

## Scintigraphy using $^{99m}\text{Tc}$ -MIBI (sestamibi), a sensitive parameter of activity of multiple myeloma \*

J. BAČOVSKÝ<sup>1</sup>, V. ŠČUDLA<sup>1</sup>, M. MYSLIVEČEK<sup>2</sup>, J. NEKULA<sup>3</sup>, M. VYŘASOVÁ<sup>1</sup>

<sup>1</sup>3rd Clinic of Internal Medicine, e-mail: Bacovskyj@post.cz, Medical Faculty and Univ. Hosp. Olomouc, Czech Republic; <sup>2</sup>Clinic of Nuclear Medicine, and <sup>3</sup>Clinic of Radiology, Med. Fac. and Univ. Hosp. Olomouc, Czech Republic

Received December 29, 2004

Technetium-99m methoxyisobutylisonitrile ( $^{99m}\text{Tc}$ -MIBI) has been shown to be useful in identifying several types of tumors, such as breast, brain, thyroid gland, malignant lymphomas and multiple myeloma.

In this study, 102 patients with multiple myeloma (MM) and 32 patients with monoclonal gammopathy of undetermined significance (MGUS) had been evaluated for correlation between  $^{99m}\text{Tc}$ -MIBI and biochemical and hematological markers of activity of the disease. Significant statistical correlation was found between summary score (SS) of  $^{99m}\text{Tc}$ -MIBI scintigrams and beta2-microglobulin ( $p < 0.001$ ), monoclonal immunoglobulin level MIG ( $p < 0.001$ ), serum thymidine-kinase – sTK ( $p < 0.001$ ), CRP ( $p < 0.05$ ) and cross-linked carboxyterminal telopeptide of type I collagen – ICTP ( $p < 0.05$ ) bone marrow plasmocytosis -BMPc ( $p < 0.001$ ) and hemoglobin Hb ( $p < 0.001$ ). All 32 patients with MGUS had physiological activity of  $^{99m}\text{Tc}$ -MIBI scintigrams.

Technetium-99m methoxyisobutylisonitrile ( $^{99m}\text{Tc}$ -MIBI) is a useful indicator of activity of MM and helps in differentiating between multiple myeloma (MM) and monoclonal gammopathy of undetermined significance (MGUS).

*Key words: Technetium-99-m methoxyisobutylisonitrile, multiple myeloma, monoclonal gammopathy of undetermined significance*

Recently the non-specific oncologic diagnostic has been widened by using  $^{99m}\text{Tc}$  methoxyisobutylisonitril ( $^{99m}\text{Tc}$ -MIBI or sestamibi), originally introduced into clinical practice for the examination of perfused myocardium. A non-specific uptake of  $^{99m}\text{Tc}$ -MIBI had been recorded in several types of tumors so that this method seems to be useful in their detection and imaging of their metastases [14] e.g. in malignant tumors of breast [13, 17], lung [5, 12], brain [19], thyroid gland [10], musculoskeletal sarcomas [18], malignant lymphomas [25] and parathyroid adenomas [21]. Several studies have reported on possible use of  $^{99m}\text{Tc}$ -MIBI as a suitable radiopharmacological, which is uptaken in tumor tissue in multiple myeloma (MM) [1, 2, 4, 6, 8, 9, 11, 22, 23].

To evaluate the extent of MM and follow-up the disease, a routine practice covers the determination of hemoglobin (Hb), biopsy of bone marrow with percentage determination of its plasma cell extent (Pb), assessment of monoclonal immunoglobulin concentration (MIG) in the serum or urine,

and radiography of the skeleton. Biological activity of MM has been routinely assessed by the examination of beta-2-microglobulin in the serum ( $B_2M$ ), serum thymidinekinase (sTK), C-reactive protein (CRP) and a marker of osteolytic activity of cross-linked carboxyterminal telopeptide of type I collagen (ICTP).

However, all above-mentioned techniques have certain limitations [16]. A conventional radiography is capable of proving the presence of osteolytic lesions but is not able to differ between an active disease and residual osteolysis without active proliferation of plasma cells [2]. Moreover, a conventional radiography cannot detect the presence of the disease in bone marrow and soft tissues. Bone marrow biopsy is a classical invasive examination method, which does not provide reliable information about the extent of disease, particularly in the case of nodular arrangement of myeloma infiltrates [16]. Most previous studies reported that  $^{99m}\text{Tc}$ -MIBI uptake in bone marrow may serve as an indicator of MM activity, which is important particularly in non-secretory form of MM, solitary and extramedullary forms of the disease.

\*This study was supported by the grant IGA MZ ČR, NC 7503-3.

Patients with MM had been reported to have various patterns of  $^{99m}\text{Tc}$ -MIBI uptake and the uptake grade is expressed by semiquantitative score (SS) showed a correlation with clinical stage of the disease [3,15]. A positive correlation was found between  $^{99m}\text{Tc}$ -MIBI and percentage of plasma cells (Pb) in bone marrow [15].

The aim of the present study was to evaluate the use of  $^{99m}\text{Tc}$ -MIBI scintigraphy in the detection of skeleton and soft tissue involvement in MM and MGUS, to assess the activity of MM and to determine correlation among various uptake patterns of  $^{99m}\text{Tc}$ -MIBI scintigraphy and clinical stage of the disease, as well as biochemical and hematological markers of disease progression.

### Material and methods

The study included 102 patients with MM (41 men, 61 women, mean age of 62 years, age range from 37 to 80 years) and 32 patients with MGUS (12 men, 20 women, mean age of 62 years, age range from 31 to 80 years). Diagnosis of MM was made according to standard diagnostic criteria SWOG. Clinical staging of MM was made on the basis of classification according to DURIE and SALMON [7].

All patients underwent bone marrow biopsy with subsequent staging of infiltration by myeloma cells (Pb). In addition to that, MIG concentrations were determined in the serum and urine, serum MIG levels were examined by cellulose acetate electrophoresis, CRP was measured nephelometrically (Behring, AG Marburg, BRD) within normal limits of 1–12 mg/l; B<sub>2</sub>M was examined by radio-immune assay (RIA kit, ADICO Prague) with normal value of 0.9–2.3 ng/ml, serum thymidinkinase (sTK) was examined by radio immune assay (RIA kit, ADICO Prague) with normal value to 5 U/l; ICTP bone marrow resorption marker was measured in the serum using RIA method (Orion Diagnostica Finland kit) with normal values within 1.8–5.0 ng/ml; hemoglobin (Hb) and serum calcium (sCa) were determined by standard methods. A complete skeleton imaging was carried out in all patients.

Anterior and posterior whole-body scanning were obtained 10 min after intravenous injection of 800 MBq of  $^{99m}\text{Tc}$ -MIBI using a scintillation camera Apex Helix, Elscint (“step and shoot” acquisition, 300 s/step, 256x256 matrix) or a scintillation camera E-CAM, Siemens (continuous shift of 12 cm/min, 256x256 matrix). Both cameras were equipped with two detectors with low energy parallel-hole collimators. The obtained scans were classified as follows: N at physiological distribution of  $^{99m}\text{Tc}$ -MIBI, D at diffuse uptake in bone marrow, F at focal uptake of  $^{99m}\text{Tc}$ -MIBI in bone marrow or extramedullary, and D+F at combined diffuse and focal uptake. Type D scans were graded semiquantitatively according to the extension of involvement (score E) and accumulation of  $^{99m}\text{Tc}$ -MIBI in bone marrow (score I). Tables 1, 2. In all patients the summary score was calculated (SS=E+I) [15]. Type D scans graded according to bone marrow involvement (E)

and  $^{99m}\text{Tc}$ -MIBI accumulation (I) reached the SS score of 2 to 6. For statistical analysis, N scans were assigned the score SS 1 and F and F+D scans the score SS 7.

At detection of active MM, as “golden standard” were considered the results obtained from laboratory examinations according standard criteria [7]. MM remission was defined using traditional criteria as the stage with <5% plasma cells in bone marrow and reduced MIG after therapy to >75% of the initial value [7]. The results were processed statistically using Chi-square analysis, ANOVA analysis and LSD tests, and correlation analysis (correlation between SS and other variables). Values  $p < 0.05$  were considered as significant. In addition to that, sensitivity, specificity, positive and negative predictive value and diagnostic accuracy of  $^{99m}\text{Tc}$ -MIBI scintigraphy were calculated for the detection of patients with active MM.

### Results

Of 102 patients with MM, 83 patients (81%) had active stage of the disease. They were mostly patients with the actually diagnosed MM who required therapy or patients with relapsed MM (stage II-III according to Durie and Salmon). Of 19 MM patients without signs of active disease, 8 patients were in clinical stage IA and no therapy was required; 11 pa-

**Table 1. Distribution of different patterns of  $^{99m}\text{Tc}$ -MIBI scans in patients with active MM or clinically inactive stage (stage IA, remission).**

$^{99m}\text{Tc}$ -MIBI scintigram	Clinical stage of MM patients				$\chi^2 = 48,8$ $p < 0.001$
	active MM n=83		inactive MM, st. IA n=8, remission n=11		
N	6	7.2%	15	78.9%	
D	42	50.6%	3	15.7%	
F a F+D	35	42.1%	1	5.2%	

N – physiological distribution, D – diffuse accumulation in bone marrow, F – focal accumulation, D+F – combined diffuse and focal accumulation

**Table 2. Correlation between  $^{99m}\text{Tc}$ -MIBI uptake grade in bone marrow of MM patients expressed by summary score – SS (SS 3.6±2.6) and markers of MM activity**

Markers of activity MM	R	p	
BMPc %	20 ± 18.9	0.472	<0.001
MIG g/l	27.7 ± 20.1	0.39	<0.001
sTK U/l	17.7 ± 18.8	0.34	<0.001
B <sub>2</sub> M ng/ml	6.2 ± 6.6	0.27	<0.001
CRP mg/l	11.8 ± 19.3	0.18	<0.05
ICTP ng/ml	12.0 ± 19.4	0.199	<0.05
Hb g/l	114.8 ± 19.5	-0.3	<0.001

B<sub>2</sub>M – beta2-microglobulin, MIG – monoclonal immunoglobulin, sTK – serum thymidinekinase, CRP – C-reactive protein, ICTP – cross-linked carboxyterminal telopeptide of type I collagen, Hb – hemoglobin, BMPc – bone marrow plasmacytosis

tients were in remission after previous therapy. Twenty-one subjects out of 102 patients had type N scan (21%), 45 patients had type D (44%), and type F or F+D was detected in 36 patients (35%). Chi-square analysis proved a significant difference ( $\chi^2=48.8$ ;  $p<0.001$ ) in type distribution of  $^{99m}\text{Tc}$ -MIBI scans between patients with active disease and patients in initial stage I A of MM without signs of activity or in remission (Tab. 1).

Of 36 patients with F a F+D type of  $^{99m}\text{Tc}$ -MIBI scan, 35 had active disease (35/36), i.e. 97%. Active disease was found also in 42/45 (93%) patients with type D scan. 15/19 (79%) patients with type N scan were in remission. Of 81 patients with pathological scan (type D, F or F+D), 95% (77/81) had active disease. While only four patients without signs of active disease in clinical stage IA according to Durie and

Salmon showed the pathological scan type, three patients had type D with summation score 3 and one patient had type F+D (Tab. 1).

Correlation was evaluated between the grade of  $^{99m}\text{Tc}$ -MIBI uptake expressed by summary score SS and biochemical and hematological markers of MM activity. A significant positive correlation was found between SS and the value of MIG, BMPc, sTK,  $\text{B}_2\text{M}$ , CRP, ICTP. A significant inverse correlation was recorded between SS and hemoglobin (Hb). (Tab. 2, Fig. 1).

Of the total number of 83 patients with active MM, four patients (5%) were in stage I, 34 (41%) in stage II and 45 (54%) patients in stage III. Six patients (7%) of 83 with active form of the disease showed type N scan at  $^{99m}\text{Tc}$ -MIBI scintigraphy. Chi-square analysis did not prove any signifi-

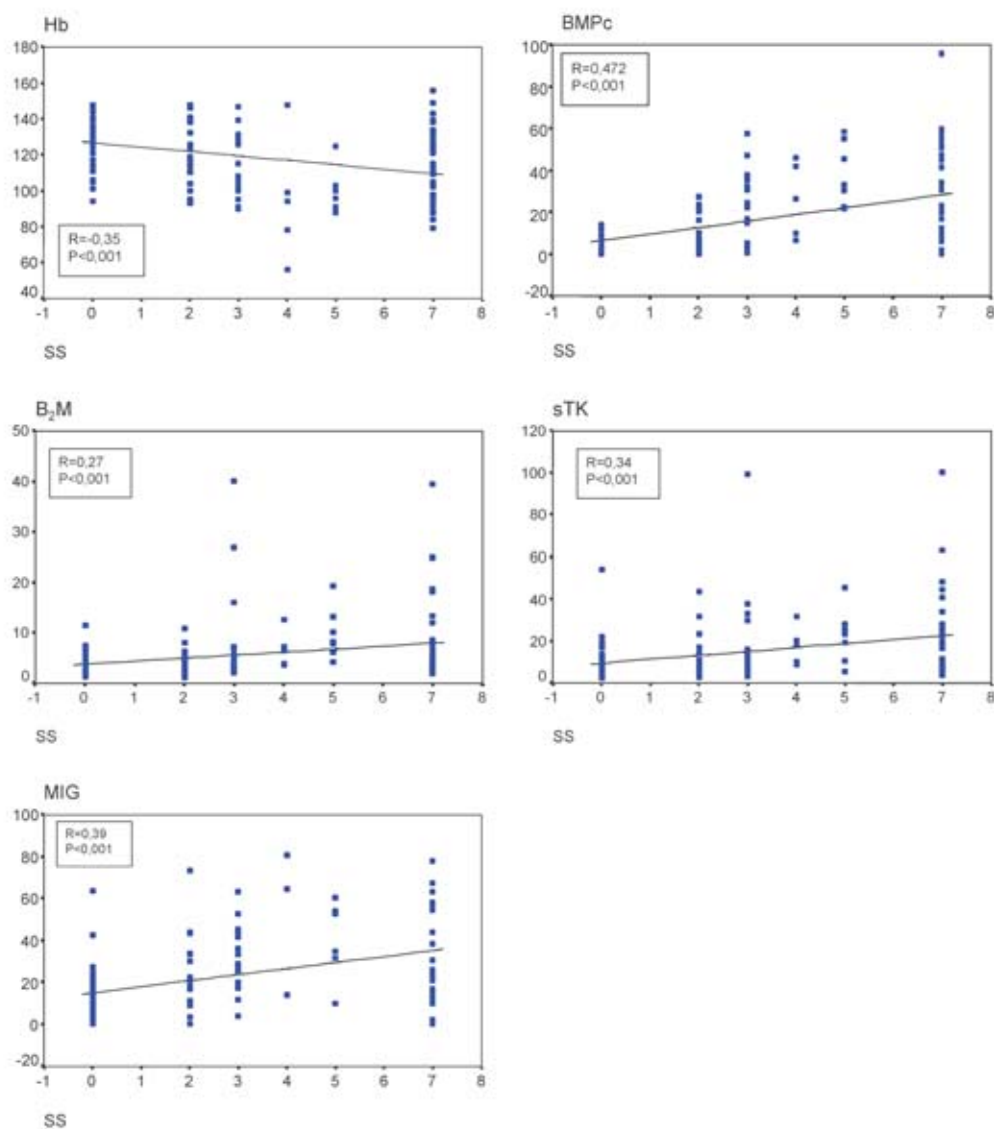


Figure 1. Graphs of  $^{99m}\text{Tc}$ -MIBI uptake dependence degree (summary score SS) and markers of activity MM: Hb, BMPc,  $\text{B}_2\text{M}$ , sTK, MIG. Hb – hemoglobin, BMPc – bone marrow plasmacytosis,  $\text{B}_2\text{M}$  – beta2-microglobulin, sTK – serum thymidinekinase, MIG – monoclonal immunoglobulin.

cant difference between scan type distribution in patients in various stages of the disease ( $\chi^2=2.46$ ;  $p=0.65$ ). Forty patients (48%) with active form of myeloma in stage II and III showed type D scans and 33 (40%) had type F or F+D. Only 2 patients with active form of MM in stage I had type D of  $^{99m}\text{Tc}$ -MIBI scan and 2 patients had type F+D. None patient of two with type D scan and active MM in stage I had summary score SS over 4 (one had SS 2, second SS 3). Sensitivity of  $^{99m}\text{Tc}$ -MIBI scintigraphy in the detection of active phase of multiple myeloma was 93%, specificity 79% in the whole groups under study.

Of 32 patients with MGUS, physiological distribution of  $^{99m}\text{Tc}$ -MIBI in bone marrow (type N scan) was recorded in 25 patients, and 7 patients had type D scan with low value of summary score  $\text{SS} \leq 2$ .

## Discussion

The present study carried out with MM patients subjected to  $^{99m}\text{Tc}$ -MIBI scintigraphy confirmed the results reported elsewhere [20] and four patterns of  $^{99m}\text{Tc}$ -MIBI uptake were recorded: physiological, diffuse, focal and combined focal and diffuse. Of 102 patients with MM included in the study, 79% of patients with normal scintigraphy were in remission and 95% of patients with pathological scan had active form of the disease.  $^{99m}\text{Tc}$ -MIBI scintigraphy showed high sensitivity and specificity in the detection of patients with active disease and appeared to be reliable in discrimination of those subjects from patients in remission (93% and 79%, respectively).

Ninety-nine % of patients with type F or F+D scan were in clinical stage II or III according to Durie and Salmon. A statistically significant positive correlation was found between summary score (SS) of  $^{99m}\text{Tc}$ -MIBI scans and markers of MM activity (MIG,  $\text{B}_2\text{M}$ ,  $\text{BMPc}$ , sTK, CRP, ICTP). Therefore we believe that the presence of pathological accumulation of  $^{99m}\text{Tc}$ -MIBI in bone marrow, its type, extent and grade can be considered as indicator of MM activity.

Similar conclusions were drawn also by other authors. ALEXANDRAKIS et al [3] found in the study with 35 MM patients that the activity of MM was directly related to the grade of  $^{99m}\text{Tc}$ -MIBI uptake in bone marrow. Similarly, BALLEARI et al [4] reported on high sensitivity and specificity of  $^{99m}\text{Tc}$ -MIBI scintigraphy for MM activity in bone marrow and consider this imaging method as a reliable approach for the staging and follow-up of patients with multiple myeloma. FONTI et al [11] quantified bone marrow uptake of  $^{99m}\text{Tc}$ -MIBI in 24 patients with MM, 3 patients with MGUS and 2 healthy volunteers and tried to verify the intracellular localization of this pharmaceutical. A micro-autoradiography showed the localization of  $^{99m}\text{Tc}$ -MIBI inside plasma cells infiltrating bone marrow. Their findings proved that the degree of  $^{99m}\text{Tc}$ -MIBI both *in vitro* and *in vivo* accumulation is related to the percentage of plasma cell infiltration, which accumulate this tracer in their inner compartments. SVALDI et al [20] described in their study with 46 MM patients that a dif-

fuse pattern of  $^{99m}\text{Tc}$ -MIBI scan reflected a higher percentage of bone marrow plasma cells and considered  $^{99m}\text{Tc}$ -MIBI scintigraphy as an effective method for discrimination of the biologically active myeloma. PACE et al [15] examined 39 patients and concluded that  $^{99m}\text{Tc}$ -MIBI scintigraphy appeared as a highly sensitive method for identification of patients with active disease, selection of patients requiring therapy and for discrimination of patients in remission from patients with recurrent disease. They also proved a correlation with clinical stage of the disease.

Our 32 patients with MGUS showed the expected bone marrow distribution of  $^{99m}\text{Tc}$ -MIBI (type N scan) and thus no infiltration by plasma cells in 25 patients, but 7 patients had type D (diffuse) scan with summary score SS 2. WAKASZGI et al [24] evaluated the potential of  $^{99m}\text{Tc}$ -MIBI for detecting bone metastases in comparison with conventional tracers used of skeleton scintigraphy. They examined by  $^{99m}\text{Tc}$ -MIBI scintigraphy 124 control patients without skeleton or bone marrow abnormalities. In 90% they found a slightly elevated accumulation of  $^{99m}\text{Tc}$ -MIBI spine, sternum and rib bone marrow. Thus, type D scan with summation score 2 cannot be considered as an unambiguous pathological finding. PACE et al [15] believed to be normal not only the type N of  $^{99m}\text{Tc}$ -MIBI scan but also type D with summary score 2. In harmony with the above conclusions, all findings in patients with MGUS in our group under study can be considered generally as physiological.

Four patients without signs of active MM (stage IA according to DURIE and SALMON) showed a pathological type of scan, 3 patients had type D with summary score 3 and one patient had type F+D. Despite clear pathological scans, those 4 patients were not indicated for therapy due to the clinical stage IA and absence of other signs of disease activity. However, one of those patients had disease progression with laboratory signs of hypercalcemia and renal insufficiency in the course of 3 months. Another patient displayed clinical and laboratory signs of active disease during subsequent 4 months and had to receive chemotherapy. Thus,  $^{99m}\text{Tc}$ -MIBI scintigraphy predicted in those two patients the development of active disease earlier than other conventional laboratory methods. These findings indicate that  $^{99m}\text{Tc}$ -MIBI scintigraphy may play a predictive role even in the follow-up of patients with MM in stage IA who are still without clinical and laboratory signs of disease activity.

In 3 patients with pattern F+D and extramedullar presence of MM foci we used  $^{99m}\text{Tc}$ -MIBI scintigraphy for determination of optimal site for puncture biopsy. Scintigraphy thus allowed a better localization of disease involvement and activity.

## Conclusions

It is concluded that whole body scintigraphy using  $^{99m}\text{Tc}$ -MIBI seems to be an easy, sensitive and available parameter of biological activity of multiple myeloma (MM). In-

dividual patterns of  $^{99m}\text{Tc}$ -MIBI uptake in MM patients showed a close association with the grade of disease activity, correlation with clinical stage of the disease and allowed with high sensitivity to discrimination of patients in remission from those with recurrent disease. Patients with MGUS had mostly physiological pattern of  $^{99m}\text{Tc}$ -MIBI uptake, or only a very low activity of diffuse pattern.

$^{99m}\text{Tc}$ -MIBI scintigraphy can be used in MM for determination of optimal site for puncture biopsy, especially in cases of suspected involvement of soft tissues.

Some preliminary findings in our study indicate that  $^{99m}\text{Tc}$ -MIBI scintigraphy may play a predictive role in the follow-up of patients with MM in clinical stage IA according to Durie and Salmon.

## References

- [1] ADAMS BK, FATAAR A, NIZAMI MA. Technetium-99m-sestamibi uptake in myeloma. *J Nucl Med* 1996; 37: 1001–1002.
- [2] ALEXANDRAKIS MG, KYRIAKOU DS, PASSAM F, KOUKOURAKI S, KARKAVITSAS N. Value of Tc-99m sestamibi scintigraphy in the detection of bone lesions in multiple myeloma: comparison with Tc-99m methylene diphosphate. *Ann Hematol* 2001; 80: 349–353.
- [3] ALEXANDRAKIS MG, KYRIAKOU DS, PASSAM FH, MALLIARAKI N, CHRISTOPHORIDOU AV, KARKAVITSAS N. Correlation between the uptake of Tc-99m-sestaMIBI and prognostic factors in patients with multiple myeloma. *Clin Lab Haematol* 2002; 24: 155–159.
- [4] BALLEARI E, VILLA G, GARRE S, GHIRLANDA P, AGNESE G et al. Technetium-99m-sestamibi scintigraphy in multiple myeloma and related gammopathies: a useful tool for the identification and follow-up of myeloma bone disease. *Haematologica* 2001; 86: 78–84.
- [5] BOM HS, KIM YC, SONG HC, MIN JJ, KIM JY, PRK KO. Technetium-99m-MIBI uptake in small cell lung cancer. *J Nucl Med* 1998; 39: 91–94.
- [6] CATALANO L, PACE L, CALIFANO C, PINTO AM, DE RENZO A et al. Detection of focal myeloma lesions by technetium-99m-sestaMIBI scintigraphy. *Haematologica* 1999; 84: 119–124.
- [7] DURIE BGM, SALMON SE. A clinical staging system for multiple myeloma: correlation of measured myeloma cell mass with presenting clinical features, response to treatment and survival. *Cancer* 1975; 36: 842–854.
- [8] DURIE BGM, WAXMAN A, JOCHELSON M, GILES FJ, HAMBURG G, AVEDON M. Technetium-99m-MIBI scanning in multiple myeloma (MM) (abstract). *Proc Am Soc Clin Oncol* 1994; 13: 411.
- [9] EL-SHIRBINY AM, YEUNG H, IMBRIACO M, MICHAELI J, MACAPINLAC H, LARSON SM. technetium-99m-MIBI versus fluorine-18-FDG in diffuse multiple myeloma. *J Nucl Med* 1997; 38: 1208–1210.
- [10] FOLDES I, LEVAY A, STOTZ G. Comparative scanning of thyroid nodules with technetium-99m-methoxyisobutylisonitrile. *Eur J Nucl Med* 1993; 20: 330–333.
- [11] FONTI R, DEL VECCHIO S, ZANNETTI A, DE RENZO A, DI GENNARO F et al. Bone marrow uptake of  $^{99m}\text{Tc}$ -MIBI in patients with multiple myeloma. *Eur J Nucl Med* 2001; 28: 214–220.
- [12] KAO CH, WANG SJ, LIN WY, HSU CY, LIAO SQ, YEH SH. Differentiation of single-solid lesions in the lungs by means of single photon emission tomography with technetium-99m-methoxyisobutylisonitrile. *Eur J Nucl Med* 1993; 20: 249–254.
- [13] KHALKHALI I, MENA I, DIGGLES L. Review of imaging techniques for the diagnosis of breast cancer: a new role of prone scintimammography using technetium-99m-sestamibi. *Eur J Nucl Med* 1994; 21: 357–362.
- [14] MÜLLER ST, GUTH-TOUGELIDES B, CREUTZIK H. Imaging of malignant tumours with MIBI- $^{99m}\text{Tc}$  SPECT abstract. *J Nucl Med* 1987; 28: 562P.
- [15] PACE L, CATALANO L, PINTO AM, DE RENZO A, DI GENNARO F et al. Different patterns of technetium-99m sestamibi uptake in multiple myeloma. *Eur J Nucl Med* 1998; 25: 714–720.
- [16] PACE L, CATALANO L, DEL VECCHIO S, DI GENNARO F, DE RENZO A et al. Predictive value of technetium-99m sestamibi in patients with multiple myeloma and potential role in the follow-up. *Eur J Nucl Med* 2001; 28: 304–312.
- [17] PRATS E, AISA F, ABOS MD, VILLAVIEJA L, GARCIA-LOPEZ F et al. Mammography and  $^{99m}\text{Tc}$ -MIBI scintimammography in suspected breast cancer. *J Nucl Med* 1999; 40: 296–301.
- [18] SODERLUND V, JONSSON C, BAUER HCF, BROSJO O, JACOBSSON H. Comparison of technetium-99m-MIBI and technetium-99m.tetrofosmin uptake by musculoskeletal sarcomas. *J Nucl Med* 1997; 38: 682–686.
- [19] SOLER C, BEAUCHESNE P, MAATOUGUI K, SCHMITT T, BARRAL FG et al. Technetium-99m sestamibi brain single-photon emission tomography for detection of recurrent gliomas after radiation therapy. *Eur J Nucl Med* 1998; 25: 1649–1657.
- [20] SVALDI M, TAPPA C, GEBERT U, BETTINI D, FABRIS P et al. Technetium-99m-sestamibi scintigraphy: an alternative approach for diagnosis and follow-up of active myeloma lesions after high-dose chemotherapy and autologous stem cell transplantation. *Ann Hematol* 2001; 80: 393–397.
- [21] TAILFER R, BOUCHER Y, POTVIN C, LAMBERT R. Detection and localization of parathyroid adenomas in patients with hyperparathyroidism using a single radionuclide imaging procedure with technetium-99m -sestamibi (double-phase study). *J Nucl Med* 1992; 33: 1801–1807.
- [22] TIROVOLA EB, BIASSONI L, BRITTON KE, KALEVA N, KOUYKIN V, MALPAS JS. The use of  $^{99m}\text{Tc}$ -MIBI scanning in multiple myeloma. *Br J cancer* 1996; 74: 1815–1820.
- [23] UNLU M, HAZNEDAR R, ATAVCI S, INANIR S, TARGUT B. Detection of bone lesion in multiple myeloma using Tc-99m MIBI scintigraphy [abstract]. *Eur J Nucl Med* 1995; 22 Suppl: 739.
- [24] WAKASZGI S, NOGUTI A, KATUDA T, HASHIZUME T, HASEGAWA Y. Potential of  $^{99m}\text{Tc}$ -MIBI for detecting bone marrow metastases. *J Nucl Med* 2002; 43: 596–602.
- [25] ZIEGELS P, NOCAUDIE M, HUGLO D, DEVEAUX M, DETOURMIGNIES L et al. Comparison of technetium-99m methoxyisobutylisonitrile and gallium-67 citrate scanning in the assessment of lymphomas. *Eur J Nucl Med* 1995; 22: 126–131.