

CLINICAL STUDY

Conn's syndrome after kidney transplantation

Michaela JAVORKOVA¹, Andrea BYSTRICANOVA¹, Martina CIRBUSOVA¹,
Marcela CVOLIGOVA¹, Martin CHRASTINA¹, Juraj MARIS¹, Janka OTAVKOVA¹,
Zuzana ZILINSKA^{1,2}

Department of Urology with The Center for Kidney Transplantation, University Hospital Bratislava,
Bratislava, Slovakia. zilinskazu@gmail.com

ABSTRACT

Conn's syndrome, defined as unilateral aldosterone-producing adenoma, accounts for 35–40% of cases of primary hyperaldosteronism. Primary hyperaldosteronism typically occurs in younger patients with poorly controlled arterial hypertension due to extracellular fluid retention, in whom at least a triple combination of antihypertensives, including a diuretic, is needed to maintain normotension. The clinical picture of arterial hypertension may be complemented by symptoms associated with hypokalaemia, such as weakness, fatigue, palpitations, convulsions, polydipsia, or polyuria. In addition to arterial hypertension and hypokalaemia, the diagnosis of Conn's syndrome relies on examination of serum renin and aldosterone concentrations, plasma renin activity, exercise or furosemide stimulation tests, and imaging studies, preferably computed tomography. The method of treatment of Conn's syndrome is adrenalectomy. In patients with primary hyperaldosteronism with underlying bilateral adrenal cortical hyperplasia or patients contraindicated for surgery, mineralocorticoid receptor antagonists are administered in combination with antihypertensives targeted for optimal blood pressure control.

In the group of patients after kidney transplantation, the exact incidence of primary hyperaldosteronism is unknown. Based on a cross-sectional study performed in 2020, it is estimated to be approximately 15% in the group of patients with unsatisfactorily compensated arterial hypertension; in the cohort of normotensive recipients, the incidence of primary hyperaldosteronism is not documented. Diagnosis of Conn's syndrome in patients in the early period after kidney transplantation is problematic, as the prevalence of arterial hypertension in transplanted patients is high (70–90%) according to the literature. Mineral abnormalities, including hypokalaemia, are also common in the early post-transplant period, mainly due to factors such as duration of cold ischaemia, onset of graft function, donor parameters, post-transplant tubulopathy, and diuretics, the effects of immunosuppressive drugs (especially calcineurin inhibitors and corticosteroids), and possibly potassium-restricted dietary habits that the patient brings from the pre-transplant period, which may mask the effect of hyperaldosteronism on potassium.

We present the case of a patient who was diagnosed with Conn's syndrome 7 months after primary kidney transplantation from a deceased donor based on persistent hypokalaemia unresponsive to replacement therapy. At the time of the first manifestation of severe hypokalaemia, the patient was treated with a dual combination of antihypertensives (amlodipine at a daily dose of 5 mg and carvedilol at a daily dose of 50 mg), without the need for a diuretics.

We consider the case interesting because the spectrum of mineral and acid-base abnormalities in advanced renal failure and in the early post-transplant period, as well as acid-base and mineral imbalances, including hypokalaemia, and the high prevalence of arterial hypertension in the post-transplant period, may mask the picture of Conn's syndrome (Fig. 3, Ref. 19). Text in PDF www.elis.sk

KEY WORDS: kidney transplantation, primary hyperaldosteronism, hypokalaemia, metabolic alkalosis, secondary arterial hypertension.

¹Department of Nephrology and Kidney Transplantations, Faculty of Medicine, Comenius University, University Hospital Bratislava, Slovakia, and ²Faculty of Medicine, Comenius University, 5th Department of Internal Medicine, University Hospital Bratislava, Bratislava, Slovakia

Address for correspondence: Zuzana ZILINSKA, Assoc Prof, MD, PhD, MPH, MHA, Department of Nephrology and Kidney Transplantations, Faculty of Medicine, Comenius University, University Hospital Bratislava, Slovakia.

Phone: +421 903 643 622

Abbreviations: ABB – acid-base balance, AD – autosomal dominant, BE – base excess, BP – blood pressure, CKD – chronic kidney disease, CMV – cytomegalovirus, CNI – calcineurin inhibitor, CT – computed tomography, HU – Hounsfield units, Creat. – creatinemia, MAL – metabolic alkalosis, MRA – mineralocorticoid receptor antagonists, PRA – plasma renin activity, RAAS – renin-angiotensin-aldosterone system, RTA – renal tubular acidosis, s-ACTH – serum adrenocorticotrophic hormone

Introduction

Conn's syndrome is defined as excessive and relatively autonomous production of aldosterone, escaping regulation by the renin-angiotensin-aldosterone system (1). Primary hyperaldosteronism typically occurs in younger patients with poorly controlled arterial hypertension due to extracellular fluid retention, in whom at least a triple combination of antihypertensives, including a diuretic, is required to maintain normotension. In a proportion of patients, a positive family history with early onset of arterial hypertension or cerebrovascular accident at a younger age may be detected. Subjective discomfort is mainly related to hypokalaemia; muscle weakness, fatigue, palpitations, polydipsia or polyuria have been described (2).

The most common cause of primary hyperaldosteronism is bilateral hyperplasia of the zona glomerulosa of the adrenal gland (idiopathic hyperaldosteronism); other causes include aldosterone-producing adrenal adenoma, adrenal cortical carcinoma, ectopic aldosterone secretion in the kidney or ovary, or familial forms of hyperaldosteronism (3). A specific case that is similar to primary hyperaldosteronism is reninoma, in which excessive ectopic renin secretion stimulates aldosterone secretion to an increased degree (2).

The diagnosis of primary hyperaldosteronism relies on an elevated ratio of morning plasma aldosterone and renin concentrations. If the ratio of aldosterone to renin is greater than 20:1, primary hyperaldosteronism is highly probable. The method of choice for imaging adrenal hyperplasia or adenoma is computed tomography (CT).

In patients with unilateral disease, adrenalectomy is recommended. Patients who are contraindicated for surgery or have primary hyperaldosteronism with underlying bilateral adrenal cortical hyperplasia should be treated with mineralocorticoid receptor antagonists (spironolactone, eplerenone) and antihypertensives for optimal blood pressure control (4, 5).

The exact incidence of Conn's syndrome in the group of patients after kidney transplantation is unknown. In 2020, a cross-sectional study was conducted at the University of Wisconsin – Madison that examined the incidence of primary hyperaldosteronism in kidney transplant recipients with unsatisfactorily compensated arterial hypertension who required at least a triple combination of antihypertensives. The study resulted in an incidence of Conn's syndrome in 15.7% of enrolled patients (6).

Diagnosis is complicated by a wide spectrum of mineral and acid-base abnormalities in the early post-transplant period, including hyper- or hypokalaemia, hyper- or hypocalcaemia, hypomagnesaemia, hypophosphatemia, metabolic acidosis or metabolic alkalosis. Several factors contribute to the occurrence of these abnormalities, including the rate of onset of graft function, duration of cold ischemia, donor parameters, acute tubular necrosis, post-transplant tubulopathy, and immunosuppressive therapy, especially calcineurin inhibitors and corticosteroids (7, 8). Prolonged cold ischemia may be the cause of acute tubular necrosis. Activation of the renin-angiotensin-aldosterone system (RAAS) leads to decreased glomerular filtration and fluid retention, resulting in com-

pensatory suppression of RAAS activity with subsequent polyuria leading to hyponatremia, hypokalaemia, hypomagnesaemia, and hypophosphatemia (9). Renal tubular acidosis (RTA) represents a disorder of transport mechanisms at the tubular level. In the early post-transplant period, it may result from acute rejection, treatment with calcineurin inhibitors or prolonged cold ischemia of the graft. The early post-transplant period is characterized by type II (proximal) RTA, which is characterized by reduced bicarbonate reabsorption at the level of proximal tubules due to calcineurin toxicity or persistent hyperparathyroidism (17, 18). Type I (distal) RTA, typical of the late post-transplant period, results from a defect in the transport mechanism for hydrogen cations (H⁺) at the level of the distal tubule and collecting duct, resulting in an inability to acidify the urine and a decrease in ammonium cation (NH₄⁺) excretion. Type I RTA is associated with interstitial damage induced by chronic rejection or long-term use of calcineurin inhibitors (10, 11, 12). As a result of the participation of the above mechanisms, stimulation of proinflammatory cytokine production, activation of intrarenal complement, endothelin ET-1 and H⁺-ATPase in secondary hyperaldosteronism, tubulointerstitial injury develops in the transplanted kidney (11, 12).

Case

We present the case of a 65-year-old patient with end-stage renal failure probably due to diabetic nephropathy (type II diabetes mellitus on diet) and hypertensive nephrosclerosis with grade 3 proteinuria (3.57 g/day), in whom the cause of chronic kidney disease (CKD) was not confirmed by renal biopsy. The patient treated with a triple combination of antihypertensive agents (bisoprolol 5 mg, irbesartan 300 mg and urapidil 180 mg per day) was enrolled in a chronic haemodialysis program in January 2019. He was free of long-term antihypertensive treatment in the pre-dialysis period, and his laboratory parameters showed normokalaemia (3.59 mmol/L). The patient underwent primary deceased donor kidney transplantation in June 2022. The donor kidney was a 70-year-old male, cause of death gunshot wound to the head, after failed cardiopulmonary-cerebral resuscitation, history of Gilbert's disease, otherwise no internal pre-existing disease, history of repeated transurethral prostatectomies for benign prostatic hyperplasia (creat. 152 μmol/l, polyuria).

Baseline admission characteristics of the recipient included residual diuresis of 500 ml, blood pressure of 160/90 mmHg, sonographically shrunken kidneys with simple cysts bilaterally, hyperkalaemia of 6.12 mmol/l, and creatininaemia of 886 μmol/l.

Because of the higher risk of delayed onset of graft function due to the length of haemodialysis treatment (42 months), cold ischemia (22 h 10 min) and a donor with extended criteria (age over 60 years, reduced renal function: creat. 152 μmol/l), antithymocyte globulin was administered at a dose of 3.38 mg/kg (total 240 mg) in the induction and a combination of prednisone, mycophenolic acid, and tacrolimus in the maintenance treatment. Primary onset of graft function was noted.

The early post-transplant period was complicated by urosepsis in acute nonobstructive pyelonephritis in the graft caused by

Enterococcus faecalis and *Pseudomonas aeruginosa*, treated with vancomycin and meropenem. The patient was discharged on post-operative day 32 with creatininaemia 168 $\mu\text{mol/l}$, normokalaemia 4.61 mmol/l , blood pressure controlled with a quadruple combination of antihypertensives (amlodipine 10 mg, carvedilol 50 mg, rilmenidine 2 mg, doxazosin 8 mg) and furosemide at a daily dose of 20 mg. Blood pressure ranged between 120–130/75–80 mmHg in the home environment and outpatient follow-ups with gradual withdrawal of antihypertensives to a dual combination (amlodipine 5 mg and carvedilol 50 mg/day). Maintenance immunosuppression consisted of a triple combination of a calcineurin inhibitor (mean valley concentration of tacrolimus 9.5 ng/ml), mycophenolic acid (720 mg/day), and prednisone (5 mg/day). 7 months after kidney transplantation, hypokalaemia (2.83 mmol/l) with metabolic alkalosis (BE 6.7 mmol/l) was first noted. Hypokalaemia was attributed to dietary error (patient reported adherence to a low-potassium diet) in combination with a loop diuretic and corticosteroids. The patient was hospitalized for replacement therapy. Potassium chloride supplementation of 3000 mg potassium chloride/day was required to achieve normokalaemia, representing 1575 mg (40 mmol) of potassium.

The patient was discharged with a dual combination of antihypertensives (amlodipine at a daily dose of 5 mg, carvedilol at a daily dose of 50 mg), without diuretic therapy, maintenance immunosuppressive therapy was unchanged. The daily dose of potassium chloride at the time of discharge was 1800 mg, representing 945 mg (24 mmol) of potassium. At follow-up 36 days later, severe hypokalaemia (2.91 mmol/l) with metabolic alkalosis (base deficit +4.7 mmol/l) recurred. The patient did not report vomiting or diarrhoea, diet without potassium restriction. Urinary findings confirmed increased potassium (24.2 mmol/l) and chloride (115 mmol/l), slightly increased fractional excretion of sodium (3.09), chloride (4.15) and significantly increased fractional excretion of potassium (29.75), which, together with hypokalaemia, led to the suspicion of hyperaldosteronism.

In the differential diagnosis of hypokalaemia, a physiological morning serum aldosterone concentration (442 ng/l), a significantly suppressed morning serum renin concentration (< 0.5 ng/l) and a high renin/aldosterone ratio (884 ng/mU) were found. Serum and urinary cortisol concentrations (298.6 nmol/l and 412 nmol/24 h, respectively) as well as serum adrenocorticotrophic hormone concentration (5.7 pg/ml) were within the physiological range. Urinary aldosterone excretion/24 h was elevated (43.8 nmol/24 h). Based on the above findings, hypercorticism was ruled out and primary hyperaldosteronism was supposed. For further diagnosis, a computed tomography (CT) scan of the abdomen was performed with the finding of a 16 mm lesion in the medial limb and junction of the right adrenal gland with a density of -5 HU, which corresponded to the CT image of the adenoma. A high serum renin/aldosterone ratio with increased urinary aldosterone excretion and CT findings suspicious for a right adrenal adenoma led to the diagnosis of Conn's syndrome. Due to adenoma size less than 20 mm, the endocrinologist recommended conservative treatment with mineralocorticoid receptor antagonists (MRAs) at a dose of 50 mg daily with beneficial effect and achievement of long-term normokalaemia. Maintenance immunosuppressive and antihypertensive treatment did not change after initiation of MRAs, blood pressure was around 120/80 mmHg. A protocol biopsy performed 4 months after transplantation was negative.

The course of graft function and potassium blood levels in the first year after kidney transplantation are shown in Figures 1 and 2.

Discussion

In the differential diagnosis of hypokalaemia (Fig. 3), it is necessary to think about inadequate dietary potassium intake, extrarenal losses mainly through the gastrointestinal tract and renal potassium losses (renal tubular acidosis, loop diuretic) (2, 3, 4).

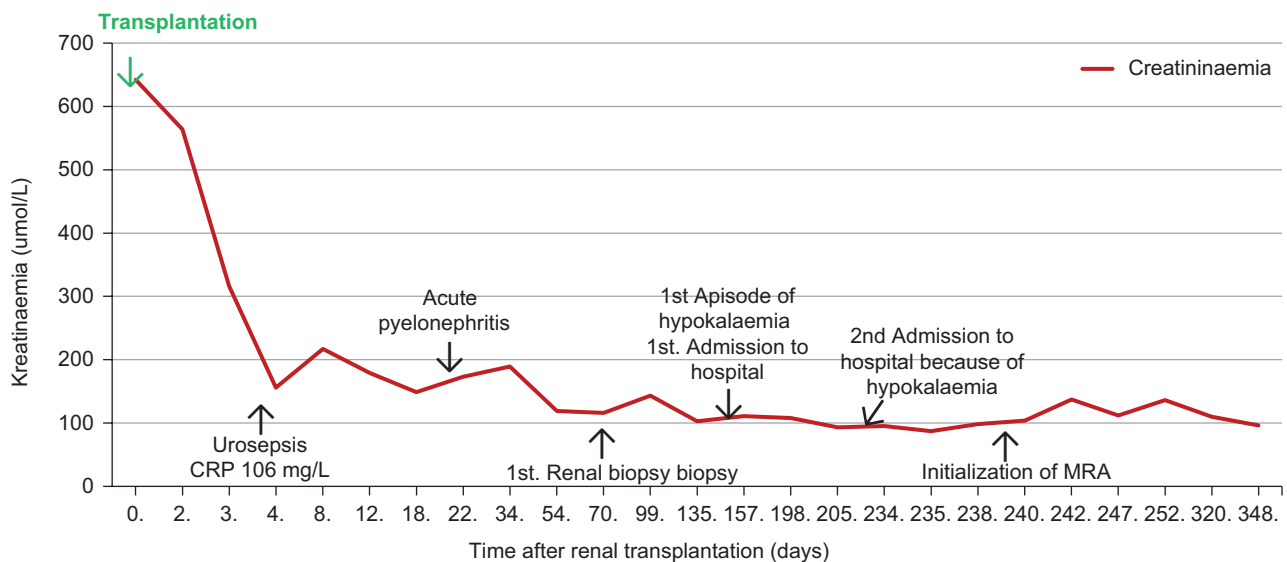


Fig. 1. The course of graft function after renal transplantation.

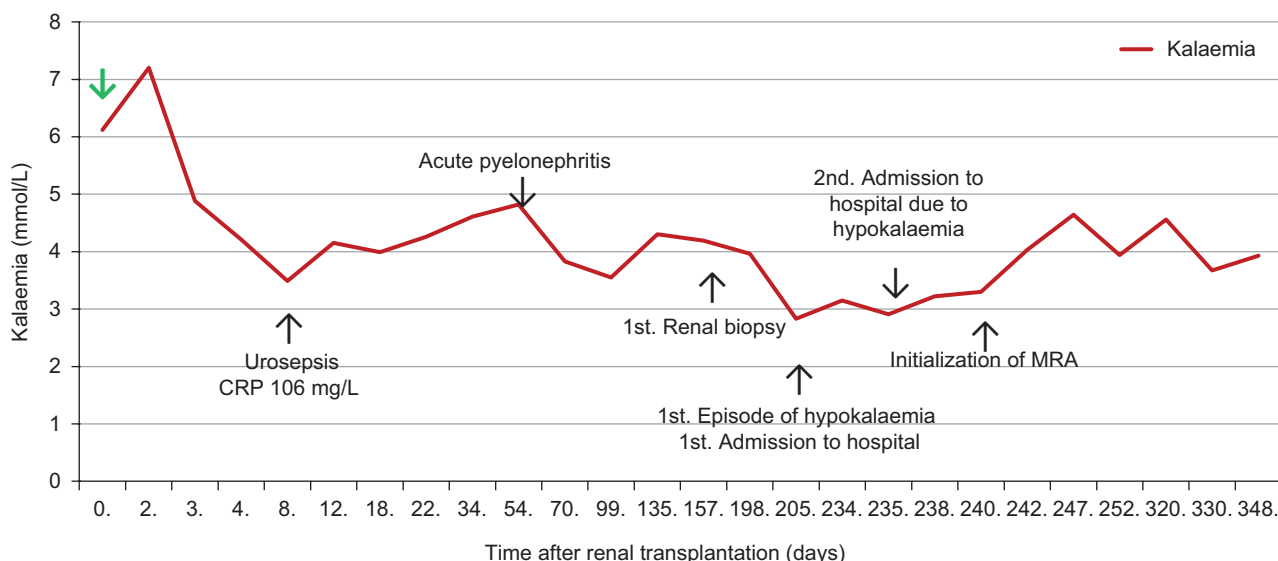


Fig. 2. The course of kalaemia after renal transplantation.

A new spectrum of mineral and acid-base abnormalities must be considered in patients after kidney transplantation, which are caused by multiple mechanisms. The most important of these are donor parameters, onset of graft function, duration of cold ischemia, acute tubular necrosis, and immunosuppressive therapy, especially calcineurin inhibitors (CNIs) and corticosteroids (13, 14). CNIs lead to an increase in magnesium excretion. Persistent hypomagnesaemia may increase kaliuresis and exacerbate hypokalaemia. However, hyperkalaemia, which is induced by inhibition of aldosterone production, is more common with CNI treatment (14).

Other causes of hypokalaemia include treatment with loop diuretics, Bartter syndrome and Gitelman syndrome, which are associated with normotensive hypokalaemia, metabolic alkalosis and high chloride excretion. Bartter syndrome is an autosomal recessive inherited tubulopathy that develops on the basis of a defective $\text{Na}^+\text{-K}^+\text{-Cl}^-$ cotransporter in the ascending thick loop of Henle, resulting in inadequate sodium absorption and activation of the RAAS with the development of secondary hyperaldosteronism. Gitelman syndrome, an autosomal recessive inherited tubulopathy, also referred to as familial hypokalaemia with hypomagnesaemia, is characterised by hypokalaemic metabolic alkalosis combined with hypomagnesaemia and low urinary calcium excretion. Another cause of hypokalaemia is Liddle's syndrome, an autosomal dominant tubulopathy, which is caused by a mutation of the sodium channel subunit gene on the luminal side of the collecting duct cells, resulting in increased urinary sodium absorption and manifestations of hyperaldosteronism in the presence of low serum

aldosterone (5, 13, 15). In our case report, we ruled out these possibilities by examining the serum aldosterone concentration. Other, less frequent causes of hyperaldosteronism include excessive intake of liquorice, where the mechanism of hypokalaemia is inhibition of 11-beta-hydroxysteroid dehydrogenase, in which the conversion of cortisol to cortisone is decreased. Excess cortisol

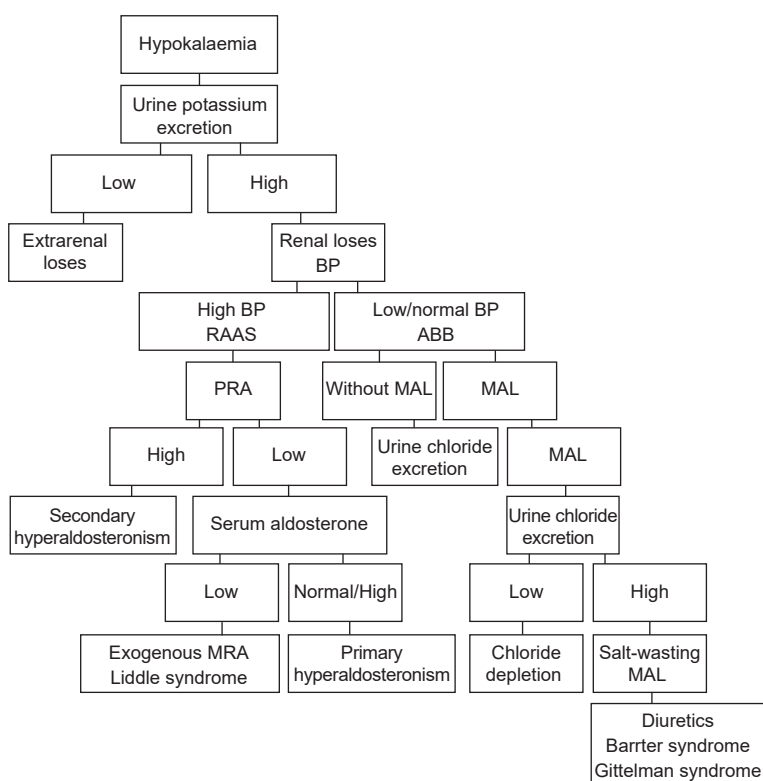


Fig. 3. Differential diagnosis of hypokalaemia.

binds to mineralocorticoid receptors and functionally manifests as a mineralocorticoid (14).

In patients with primary hyperaldosteronism, arterial hypertension is an important diagnostic marker of Conn's syndrome. The prevalence of arterial hypertension in renal transplant recipients is high and therefore is not among the findings that require more detailed diagnosis (15).

Conclusion

Conn's syndrome, a unilateral aldosterone-producing adenoma, is defined as excessive and relatively autonomous aldosterone production escaping regulation by the renin-angiotensin-aldosterone system. The incidence of Conn's syndrome in the early period after kidney transplantation is low; it is usually an unrecognized cause of arterial hypertension before kidney transplantation (9, 18). Diagnosis of Conn's syndrome in patients with end-stage renal failure and in the early period after renal transplantation is problematic because of low glomerular filtration rate in patients with end-stage renal failure and immunosuppression together with loop diuretic, and possibly potassium-restricted dietary habits prior to the transplantation period, may mask the effect of hyperaldosteronemia on potassium, which, together with arterial hypertension, is crucial for the suspicion of Conn's syndrome. The prevalence of arterial hypertension in patients with end-stage renal failure and after renal transplantation has been reported to be between 70–90% (19). We present the case of a post-kidney transplant patient with a mild form of arterial hypertension in whom antihypertensive therapy could be detrained to a two-combination regimen after kidney transplantation, with persistent severe hypokalaemia, first appearing 7 months after kidney transplantation, unresponsive to potassium chloride replacement therapy. Conn's syndrome was diagnosed. Considering the relatively early onset after kidney transplantation, we hypothesize that this was an unrecognized primary hyperaldosteronism in the pre-dialysis phase, which may have been the cause of arterial hypertension and hypertensive nephroangiosclerosis, which, together with diabetic nephropathy, led to end-stage renal failure. We hypothesize that laboratory findings related to end-stage renal failure (oliguria, metabolic acidosis, hyperkalaemia) in the pre-transplant period masked signs of primary hyperaldosteronism. Mineral abnormalities, including hypokalaemia, are common after kidney transplantation and are influenced by a wide range of factors such as the duration of cold ischaemia, onset of graft function, donor parameters, development of post-transplant tubulopathy, diuretics, and the effect of immunosuppressive drugs (especially calcineurin inhibitors and corticosteroids). Therefore, misinterpretation of hypokalaemia in the early post-transplant period and delay in the diagnosis of Conn's syndrome may occur. However, hypokalaemia unresponsive to treatment led to consideration of its hormonal cause and to the diagnosis of Conn's syndrome, including the setting of adequate treatment. In this context, the importance of early diagnosis of Conn's syndrome should be emphasized, as early adequate treatment is crucial for good blood pressure control and prevention of the development

of CKD, possibly slowing the progression of CKD as well as cardiovascular complications.

Highlights

Although the kidney transplantation is most effective, life-saving, and cheapest treatment for patients with terminal kidney failure, there is not always a complete restitution of health. The most common comorbidities that persist even after a successful kidney transplantation include high blood pressure or bone disease, approximately 20% of patients develop post-transplant diabetes mellitus in the first year after transplantation. Early recognition of complications and their effective treatment significantly affect the survival of patients and grafts. We present the case of a patient who was diagnosed with Conn's syndrome 7 months after primary kidney transplantation from a deceased donor based on persistent hypokalaemia unresponsive to replacement therapy. At the time of the first manifestation of severe hypokalaemia, the patient was treated with a dual combination of antihypertensives (amlodipine and carvedilol), without the need for a diuretic. We consider the case interesting because the spectrum of mineral and acid-base abnormalities in advanced renal failure and in the early post-transplant period, as well as acid-base and mineral imbalances, including hypokalaemia, and the high prevalence of arterial hypertension in the post-transplant period, may mask the picture of Conn's syndrome.

References

- Blažíček P.** Diagnostika endokrinné hypertenzie: Dôležitosť analýzy hormónov kôry a drene nadobličiek. In vitro, 2014. <https://www.unilabs.sk/clanky-invivo/diagnostika-endokrinné-hypertenzie-dolezitosť-analyzy-hormonov-kory-drene>.
- Nečas E.** Patologická fyziologie orgánových systémů. Praha: Karolinum, 2009, 760 s.
- Štefánek J.** Medicína, nemoci, studium na 1. LF UK [online]. 2011. <http://www.stefajir.cz/?q=connuv-syndrom>
- Češka R, Tesař V et al.** Interna. Praha: Triton, 2012, 855 s.
- Tesař V, Viklický O.** Klinická nefrologie. GRADA, 2015, 560 s.
- Garg N, Votruba CD et al.** Prevalence of primary aldosteronism in hypertensive kidney transplant recipients: A cross-sectional study. Clin Transplantation 2020, 34 (8): 10. <https://onlinelibrary.wiley.com/doi/10.1111/ctr.13999>.
- Pochinini V, Rondon-Berrios H et al.** Electrolyte and Acid-Base Disorders in the Renal Transplant Recipient. Front Med (Lausanne), 2018 5: 261. <https://www.ncbi.nlm.nih.gov/pmc/articles/PMC6176109/>.
- Bathini S.** New-onset hypokalemia in a transplant recipient – not the usual suspects! Kidney International Reports 2023; 8 (3): S49. <https://doi.org/10.1016/j.ekir.2023.02.111>.
- Samarasinghe N, Arudchelvam J et al.** Polyuria after renal transplantation: A case report and review of literature. Surgical Case Reports 2021; 4 (6): 2. https://www.scienceopen.com/polyuria-after-renal-transplantation-a-case-report-and-review_SCR-2021-6-101.
- Keven K, Ozturk R et al.** Renal tubular acidosis after kidney transplantation - incidence, risk factors and clinical implications. Nephrol. Dial. Transpl 2007; 22 (3): 906–910. <https://academic.oup.com/ndt/article/22/3/906/1900951>.
- Schwarz C, Benesch T et al.** Complete renal tubular acidosis late after kidney transplantation. Nephrol. Dial. Transpl 2006; 21 (9): 2615–2620. <https://academic.oup.com/ndt/article/21/9/2615/1938903>.

- 12. Kocyigit I, Unal A et al.** Renal tubular acidosis in renal transplantation recipients. *Renal Failure* 2022; 32 (6): 687–690. <https://www.tandfonline.com/doi/pdf/10.3109/0886022X.2010.486494>.
- 13. Hafsa T, Dobre M et al.** Metabolic acidosis post kidney transplantation. *Front Physiol* 2022, 13: 989816. <https://www.frontiersin.org/articles/10.3389/fphys.2022.989816/full>.
- 14. Ambuhl PM.** Posttransplant metabolic acidosis: a neglected factor in renal transplantation? *Curr Opin Nephrol Hypertens* 2007; 16 (4): 379–387. https://journals.lww.com/conephrolhypertens/Abstract/2007/07000/Post-transplant_metabolic_acidosis__a_neglected.15.aspx.
- 15. Cook M, Wallin J et al.** Hypokalemia secondary to primary hyperaldosteronism in a renal transplant recipient. *Clin Nephrol* 1985; 24 (5): 261–264. <https://pubmed.ncbi.nlm.nih.gov/3907909/>.
- 16. Tintillier M, Mourad M et al.** Hypokalaemia and hypertension early after kidney Transplantation. *Nephrology Dialysis Transplantation* 2002; 17 (6): 1129–1132. <https://doi.org/10.1093/ndt/17.6.1129>.
- 17. Cobb A, Aeddula NR et al.** Primary hyperaldosteronism. In *Stat pearls*. Treasure Island (FL): Stat pearls publishing, 2022. <https://www.ncbi.nlm.nih.gov/books/NBK539779/>.
- 18. Rojulpote C, Mathew A et al.** Conned by Conn's: The Manifestation of Conn's Syndrome Post-renal Transplant in a Patient with Polycystic Kidney Disease. *Cureus* 2020; 12 (4): 7512. <https://www.cureus.com/articles/29627-conned-by-conns-the-manifestation-of-conns-syndrome-post-renal-transplant-in-a-patient-with-polycystic-kidney-disease#!/>.
- 19. Ponticelli C, Cucchiari D et al.** Hypertension in kidney transplant recipients. *Transpl Int* 2011; 24 (6): 523–533. <https://pubmed.ncbi.nlm.nih.gov/21382101/>.

Received October 14, 2023.
Accepted November 5, 2023.