

Bronchial carcinoid tumors: long-term outcome after surgery*

P. FIALA¹, K. PETRÁŠKOVÁ¹, S. ČERNOHORSKÝ¹, Z. KINKOR², E. KŘEPELA¹, P. ZATLOUKAL¹

¹*Clinic of Pneumology and Thoracic Surgery, 3rd Medical Faculty, Charles University, e-mail: fialap@fnb.cz, and* ²*Department of Pathology, University Hospital Bulovka, 180 81 Prague, Czech Republic*

Received September 3, 2002

The objective of the present study was to evaluate clinical condition and results of surgical treatment of patients with typical and atypical bronchial carcinoids. The study was based on retrospective analysis of a total of 96 patients (mean age 47.3 year, age range 21–76, 44 men and women 52), who were surgically treated for bronchial carcinoid between 1985–2001. We assessed symptomatology of the disease, type of surgical intervention, tumor histology and staging, and postoperative 5-year and 10 year survival rates. The main sign of disease was respiratory inflammation. The carcinoid syndrome was not found in any patient. Most patients (n=68) were operated for central form of the tumor. The micromorphological tumor diagnosis was established prior to surgery in 76.5% patients with the central form of carcinoid. Surgical treatment included lobectomy (n=49), bronchoplastic procedure (n=14), sleeve lobectomy (n=9), atypical resection and segmentectomy (n=11), pneumonectomy (n=7) and tumor enucleation (n=5). Histological analysis revealed typical carcinoid in 77 cases (80.2%) and atypical carcinoid in 19 (19.8%). Lymph nodes (N1 and/or N2) were examined by histology in 84 patients and lymph node metastases were found in 13 (19.4%) of 67 patients with typical carcinoid and in 5 cases (29.4%) of 17 with atypical carcinoid. In the postoperative period on patient died from embolism to the arteria pulmonalis. Postoperative complications (atelectasis, prolonged air leak, bronchopleural fistula) were observed in 11.4% of patients. Tumor relapse occurred only in two patients with typical carcinoid. Postoperative 5-year and 10-year rates amounted to 98.6% and 87.3%, respectively, in typical carcinoid 94.5% and 73.5% in atypical carcinoid. The survival rates of patients with typical and atypical bronchial carcinoids were not significantly different ($p>0.05$). The surgical management is the treatment of choice in bronchial carcinoids. Results of this study indicate that the 5-year survival in patients with either histological type of bronchial carcinoid is excellent and the prognosis of operated patients is very good even in the case of regional lymph nodes infiltration by the tumors.

Key words: Bronchial carcinoid, lung resection, survival.

The term “Karzinoide“ was first used by the German pathologist OBERNDORFER in 1907 [20] for the description of a tumor resembling adenocarcinoma but with less malignant biological behavior. Carcinoids arise from the cells of diffuse neuroendocrine system called APUD system (Amine Precursor Uptake and Decarboxilation), occurring dispersedly in various organs [13]. The most frequent carcinoid localization is in gastrointestinal tract (73%) and the bronchopulmonary localization (25%), only a low number of carcinoids originate in different organs [17]. Carcinoids re-

present 2–5% of all pulmonary neoplasms [6, 8, 11]. Comparing the epidemiological data, MODLIN and SANDOR [17] found that in the course of the last decades the incidence of lung carcinoid increased. In comparison with the period of 1950–1969, when the proportion of lung localization was 10.2%, the pulmonary localization of carcinoid in the period of 1973–1991 amounted already to 32.7%.

The term “atypical“ carcinoid was designated by ARRIGONI et al in 1972 [1]. At the present time carcinoid is described as a well differentiated typical carcinoid or intermediate-grade differentiated atypical carcinoid (neuroendocrine carcinoma). The atypical carcinoids account for approximately one third of all lung carcinoids [14].

A relatively rare incidence of carcinoid makes the pro-

*This work was supported by an institutional research project (No. MZ0000064211) from the Ministry of Health, Czech Republic.

spective evaluation of a larger group of patients difficult [7] and, therefore the so far published studies are retrospective [5, 7, 12, 15, 16]. In the patients without distant metastases is the surgical treatment the basic therapeutical modality. The objective of the present study was to evaluate clinical manifestation, diagnosis and long-term outcome of surgical treatment of patients with typical and atypical bronchial carcinoids.

Patients and methods

Between January 1985 and December 2001, 96 patients underwent thoracotomy for bronchial carcinoid at the Clinic of Pneumology and Thoracic Surgery, 3rd Medical Faculty of Charles University, University Hospital Bulovka, Prague. The panel of clinical examinations performed in all patients included bronchoscopy and cytological examination, posteroanterior and lateral chest x-ray examination and since 1991 also computer tomography (CT). The following parameters were evaluated in the patients: age, sex, disease symptoms, tumor localization and histological type, type of surgical treatment, postoperative complications and mortality rate. Operative mortality was defined as any death during the first 30 postoperative days. pTNM staging of bronchial carcinoid disease was performed according to the 5th revision of lung cancer staging [18]. In order to assess survival rate of patients with bronchial carcinoid, the patients were followed-up periodically after surgical treatment. The patients after bronchoplastic procedure underwent fibrobronchoscopy during the follow-up. The follow-up period was concluded on December 31, 2001.

Hematoxylin and eosin stained sections of formalin-fixed and paraffin-embedded carcinoid tissue were microscopically reexamined (10 of high power fields in each case) and reclassified according to the criteria of a recent WHO revision of the histological typing of lung tumors [26]. The basic criteria for histological classification of carcinoids rest in evaluation of the mitotic count and of the presence and extent of necrosis. Typical carcinoid (TC) was defined by the presence of 0–1 mitoses and by the absence of necrosis or by the presence of a focal type of necrosis limited to one tumor cell or a tiny collection of them. Atypical carcinoid (AC) was defined by the presence of 2–10 mitoses and by the presence of large zonal type of tumor cells necrosis.

Statistical analysis. Quantitative data were expressed as mean \pm SD and as median with range and were analysed using the Student's t-test. Probability of survival was estimated according to the Kaplan-Meier method for the whole group of patients and for subgroups according to the type of tumor, tumor size or tumor location, where the estimates were calculated and compared using the log-rank test. A two-side p value of less than 0.05 was considered statistically significant. Furthermore, the probabilities of 5-year

and 10-year survival rate were calculated. These analyses were performed using Life Tables method.

Results

In the group of 96 studied patients the mean age was 47.3 ± 14.2 years (median 47 years, range 21–76 years). Among them there were 52 women with mean age 48.9 ± 13.3 (median 51 years, range 21–76 years) and 44 men with mean age 45.0 ± 13.5 years (median 44 years, range 22–71 years). In 27 patients (28.1%) the tumor was asymptomatic and it was found accidentally (Tab. 1). In the other patients the neoplasm was detected on the basis of their complaints. The most frequent symptom of the disease was obstructive pneumonia (n=46, 47.9%). Eighteen patients (18.7%) had hemoptysis. Clinically manifested carcinoid syndrome was not found in any patient.

Table 1. Common symptoms

Symptom	No. of patients	Percent of population
Respiratory inflammation	46	47.9%
Cough	35	36.4%
Dyspnea	23	23.9%
Chest pain	17	17.7%
Hemoptysis	18	18.7%
Carcinoid syndrom	0	0%
Asymptomatic	27	28.1%

TC was histologically determined in 77 patients (80.2%) and AC in 19 patients (19.8%). The neoplasm was detected intrabronchially by bronchoscopy (central tumor) in 68 patients (70.8%) while in the remaining 28 patients the bronchoscopic finding was normal (peripheral tumor). Cytologic examination was performed in samples obtained at bronchoscopy. In 52 patients (76.5%) with central type of tumor the cytological examination was positive, in the remaining 16 patients (23.5%) the cytological examination was negative. Patients with negative bronchoscopic finding had also negative cytologic examination. Endoscopic biopsy with finding of carcinoid was performed in 14 patients. In peripherally located lung carcinoid (n=28) the involvement of the left and the right lung was similar. On the other hand, in the case of carcinoid location in the bronchial tree the tumor was found more frequently in the right lung (n=39), especially in the lower and intermediary bronchus (n=22), and less frequently in the left lung (n=27), where again the tumors were located more frequently in the lower lobar bronchus (n=13). In 2 patients the tumor was located in the upper third of trachea and in the tracheal carina.

The most frequently applied surgical treatment was lobectomy (n=58, 60.4%) which was combined in 9 patients (9.4%) with bronchoplastic procedure. In 11 patients (11.5%) the tumor was removed by atypical resection or

Table 2. Incidence of lymph node metastases according to the histological type of lung carcinoid

	Typical carcinoid	Atypical carcinoid
Number of patients	67	17
without lymph node metastases	54 (80.6%)	12 (70.6%)
with lymph node metastases (N1 and/or N2)	13 (19.4%)	5 (29.4%)

Table 3. Staging of lung carcinoid according to its histological type

Pathologic stage	Typical histology		Atypical histology	
	No. of patients	%	No. of patients	%
Ia	38	56.7	7	41.2
Ib	13	19.4	4	23.5
IIa	4	6.0	3	17.6
IIb	3	4.5	1	5.9
IIIa	7	10.4	2	11.8
IIIb	2	3.0	0	–
IV	0	–	0	–

by segmentectomy. Seven patients (7.3%) underwent pneumonectomy. Bronchoplastic procedures were performed in 14 patients (14.6%). At the beginning of the follow-up period 5 patients underwent enucleation. Tracheostomy was performed in the patients with carcinoid of the trachea. There were no exploratory thoracotomies in the group of studied patients.

At evaluation of the primary tumor size, the tumor was less than 3 cm in diameter in 75 patients (78.1%) while in 62 patients (64.6%) it measured less than 2 cm in diameter. Twenty one patients (21.9%) had tumor larger than 3 cm in diameter and the largest tumor had 6 cm in maximum diameter. At evaluation of the T parameter according to the 5th revision of lung cancer staging [18], the distribution was as follows: T1 in 60 patients, T2 in 30 patients, T3 in 4 patients and T4 in 2 patients (carcinoid of the trachea and carcinoid of the tracheal carina). pTNM classification was done in 84 patients in whom the lymph nodes were examined histologically. In 12 patients, in which enucleation of the tumor, segmentectomy, or atypical resection were carried out, the lymph nodes were not examined. N1 and/or N2 nodes were affected from carcinoid metastasis in 13 (19.4%) of 67 and in 5 (29.4%) of 17 patient with typical carcinoid and atypical carcinoid, respectively (Tab. 2). All the patients with lymph node metastasis survived without recurrent disease to the end date of this study (median 72.6 months, range 0.8–198.1 months). We did not perform extensive dissection of mediastinal lymph nodes as is done in other histological types of lung carcinoma. Distant metastases were not identified in the patients. The most frequently evaluated pTNM stage in patients with typical carcinoid as well as atypical carcinoid was stage I (Tab. 3), no patient in IV stage underwent surgical treatment.

Eleven patients (11.4%) presented postoperative complications. Five patients (5.2%) experienced atelectasis and five patients (5.2%) required tube thoracostomy for prolonged air leaks. A bronchopleural fistula with empyema occurred in one patient (1.0%) after pneumonectomy for atypical tumor with 6 cm in diameter which caused inflammatory destruction of the right lower lung lobe with empyema. Pneumonectomy was performed after the treatment of acute phase of empyema. A bronchopleural fistula developed 4 weeks after surgery. One patient (1.0%) died after surgery from embolism to arteria pulmonalis. Adjuvant chemotherapy was not performed in any patient.

Recurrent tumor developed in 2 patients with typical carcinoid after atypical resection 52 and 63 months after surgery. Besides one patient who died postoperatively due to embolism, there were 7 patients who died before December 31, 2001. In 4 patients the cause of death could not be verified, three additional deaths were not related to carcinoid.

Survival probability was evaluated in 94 patients (97.9%), since there was no follow-up information available for two patients. The mean follow-up period was 77.8 months (median 74.5, range 0.4–204.1 months). Median survival probability for the whole group of patients was 183.1 months (95% confidence interval 169.4–196.8). Probability of 5-year survival is 97.8% and of 10-year survival 84.5% (Fig. 1).

Estimated 5-year and 10-year survival of the patients with typical carcinoid was 98.6% and 87.4%, respectively, and of those with atypical carcinoid was 94.6% and 73.6%, respectively (Fig. 2). The difference in survival probability for the patients with typical and atypical carcinoid is not statistically significant ($p=0.404$).

We did not find statistically significant difference in survival when comparing patients with T1 tumors and those with T2 tumors in all groups ($p=0.434$). Therefore we evaluated the influence of tumor size on survival probability in patients with typical and atypical carcinoid. The difference in survival probability of the patients with T1 tumor and T2 tumor was not statistically significant between the two histological types of carcinoid ($p=0.8537$ and $p=0.1201$, respectively). Moreover, the difference in survival probability of the patients with centrally located tumor and with peripheral tumor was neither statistically significant ($p=0.063$).

Discussion

Bronchopulmonary carcinoid is a relatively rare neoplasm which occurs in 2%–5% of all primary lung cancers [6, 8, 17]. Among the total of 2208 lung resections for bronchogenic carcinoma performed at our Clinic between January 1985 and December 2001 the group of 96 patients with carcinoid represents 4.3%. In this group of 96 patients the ratio of

female patients to male patients was approximately 5:4. Predominance of carcinoid in female patients is mentioned also by other authors [5, 7, 17] but this difference remains unexplained. In our group of patients we found TC in 80.2% of cases and AC in 19.8% of cases. An identical occurrence ratio of TC to AC as found in the present study was reported by other authors [2, 4, 7, 23, 24].

Similarly to other publications [4, 5, 25], the most frequent symptoms of the disease in our group of patients were poststenotic pneumonias. Hemoptysis was not the principal symptom of the disease. The asymptomatic course of the disease is described in 11.4%–39% of cases [4, 5, 10, 12, 25, 27].

Correct determination of micromorphological diagnosis prior to carcinoid surgery is important. In our group of patients, the micromorphological diagnosis of central carcinoid was preoperatively established by cytology in 76.5% of cases. Endoscopic biopsy was performed rather exceptionally (20.6%) because of the bleeding risk. Also MARTY-ANÉ et al [16] mentioned the danger of bleeding during endoscopic biopsy. DUCROCQ et al [5] reported that the risk of hemorrhage after endoscopic biopsy has been overemphasized. In contrast to cytology, the histological examination is able to differentiate between TC and AC.

The incidence of carcinoid syndrome in bronchial carcinoid is not frequent. It ranges between 0.7% and 9% [5, 6, 9, 10, 19]. Like DESCOVICH et al [4] and STOBERNACK et al [25] we did not detect carcinoid syndrome in any of our patients.

The majority of lung carcinoids (75%) arise centrally in the lobar bronchi (especially in the lower ones) and the minority of them affect the main bronchi (10%) and the lung periphery (15%) [3]. The incidence rate of 74.7% found in the present study for the central location of carcinoid is in line with previously reported data [3, 4, 5]. The lateral location of carcinoid neoplasms has been reported to occur with the prevalence to the right lung [10, 25]. In our group of patients with the occurrence of the tumor in the bronchial tree more frequently the right than the left lung was affected.

The most frequently applied surgical treatment of lung carcinoid is lobectomy without bronchoplastic procedure or in combination with it [4, 7, 12, 21, 25]. Lobectomy is con-

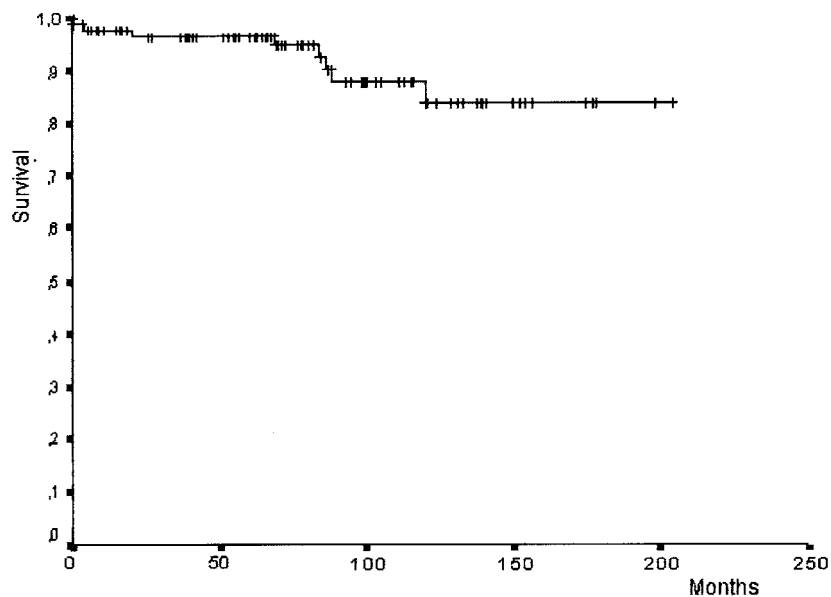


Figure 1. The survival curve of the studied patients (n=94).

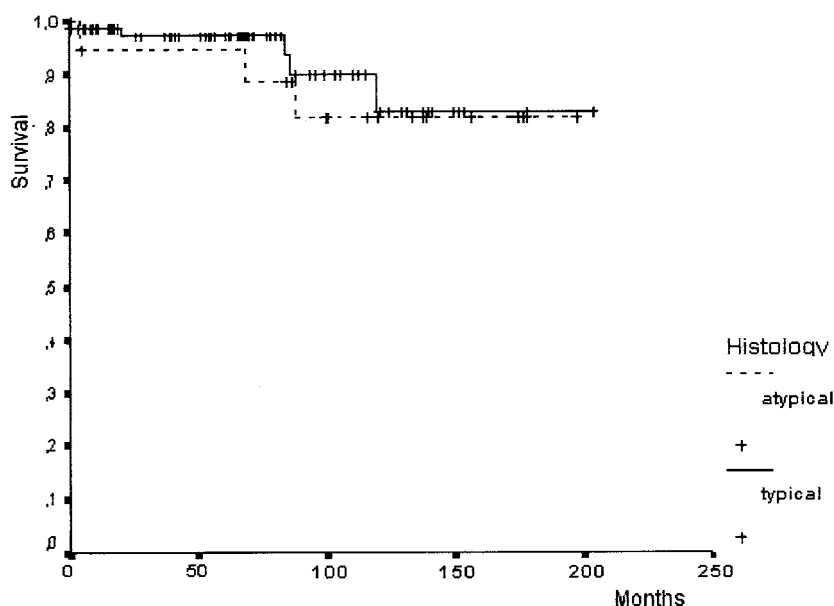


Figure 2. Survival curves of patients with typical and atypical lung carcinoid (P=0.404).

sidered to be a standard surgical treatment of AC [10]. An erroneous evaluation of preoperative or intraoperative biopsy can be the cause of incorrect decision regarding the type of surgical treatment. Indication criteria for the surgical treatment of TC and AC have been published in several studies [5, 10, 12, 27]. Bronchoplastic procedures without lung resection were indicated in 14 patients where the lung parenchyma was intact and the local finding of tumor allowed the operation on the bronchus, fulfilling the criteria of radical therapy.

Table 4. Long term survival after resection of typical and atypical bronchial carcinoid tumors

Reference	No. of patients		Survival %			
	Typical	Atypical	Typical	5 years Atypical	10 years Typical	Atypical
Harpole et al [12]	80	41	96.0%	40.0%	92%	31%
Ducroque et al [5]	39	–	92.4%	–	88.3%	–
Ferguson et al [7]	109	26	90.0%	70%	–	–
Descovich et al [4]	30	5	95.8%	–	–	–
Soga et al [23]	1595	250	93.3%	68.8%	82.1%	58.6%
Fiala et al [this series]	77	19	98.6%	94.6%	87.4%	73.6%

The indication for pneumonectomy for lung carcinoid is exceptional [27], although in some cases there is no other way to avoid it [4, 5, 7, 12]. The reason for pneumonectomy is either the inflammatory involvement of lung parenchyma or the location of tumor. Atypical resections and segmentectomies are reserved particularly for surgical treatment of peripheral TCs with less than 3 cm in diameter [4, 5, 7, 21, 22, 27]. In the present study, these surgical procedures were performed in 11 patients.

On the basis of incorrect interpretation of intraoperative biopsy that did not demonstrate carcinoid, we performed enucleation in 5 patients with peripheral lung tumor. All these patients after treatment with this surgical procedure (recently non acceptable) survive without recurrence more than 10 years. In a female patient with TC of trachea the tracheal resection was not possible because of the tumor spread through the posterior wall to hypopharynx. This patient underwent tracheostomy and received radiotherapy and is living eight years after the therapy, disease free. In a female patient with TC of carina we performed resection of the tracheal bifurcation.

At the present time it is required to examine hilar and mediastinal lymph nodes histologically in the surgical treatment of carcinoid. At the beginning of the follow-up period we did not put such an emphasis on examination of lymph nodes as we do now, and the lymph nodes were not examined in 12 patients. DESCOVICH et al [4] found positive peribronchial and hilar nodes in 5.7% of operated patients. HARPOLE et al [12] detected metastases in hilar nodes in 33.9% of operated patients for TC and AC. DUCROCO et al [5] in a group of 139 patients with TC found metastases to hilar or mediastinal lymph nodes in 9.4% of cases. SŁODKOWSKA et al [22] revealed that TC and AC metastasized to lymph nodes in 10% of cases and in 33% of cases, respectively. In our patients metastases to hilar and/or mediastinal nodes were identified in 19.4% of TCs and in 29.4% of ACs. The presence of lymph node metastases, however, does not have to be a negative prognostic factor for lung carcinoid. DUCROCO et al [5] reported long-term survival without recurrence in 13 patients with TC with lymph node metastases and on the contrary, they detected relapse of the disease with pN0 after radical surgical treatment in 4 patients with TC (2.9%). A complete resection of bronchial carcinoid

with lymph node metastases has good prognosis [16]. In our patients with metastases of TC and AC to N1 or N2 lymph nodes none of them developed recurrence and in two patients with relapse the lymph nodes were without metastases. Although there are good results regarding survival even in the cases of lung carcinoid with lymph node metastases, we suppose that the mediastinal lymphadenectomy in surgical treatment of carcinoid is undervalued. In view of these circumstances the unequivocal opinion about an extensive mediastinal lymphadenectomy has not been expressed until now. But if carcinoid is classified among carcinomas, then its use is appropriate. The results of lymph node biopsy are essential for evaluation of disease stage [16]. The finding that the largest part of our lung carcinoid patients suffered from disease stage I is in accordance with the results of other investigators [5, 7, 12, 21].

Postoperative mortality for carcinoid is low. In our group of 96 patients only one patient (1.0%) died from embolism to arteria pulmonalis. A comparably low mortality rate of patients surgically treated for lung carcinoid was also reported by others [5, 7, 12, 21]. In the patients surgically treated for TC we found 5-year and 10-year survival probability in 98.6% and 87.4%, respectively, and these results are comparable with survival data of patients with TC reported by other authors [4, 5, 12, 23]. In contrast to previous reports [7, 12, 23] we found significantly higher 5-year and 10-year survival probability of patients surgically treated for AC (94.6% and 73.6%, respectively) (Tab. 4). In the present study, the survival probability of the patients with AC is lower than that of the patients with TC but the difference is not statistically significant.

In conclusion, the results of our observations demonstrate favorable prognosis in the patients operated for bronchial carcinoid. As regards tumor size and tumor location we did not find evidence that these parameters could significantly influence postsurgery survival rate in patients with lung carcinoid. In the view of observation of tumor recurrence in patients with TC and without lymph node metastases, in the view of the fact that after TC enucleation recurrent disease did not occur, and in the view of the absence of disease relapse in patients with lymph node metastases, it may be considered that carcinoids of both histological types are neoplasms of unpredictable behavior.

In all resections performed for lung carcinoids lymph node dissection is required.

References

- [1] ARRIGONI MG, WOOLNER LB, BERNATZ PE. Atypical carcinoid tumors of the lung. *J Thorac Cardiovasc Surg* 1972; 64: 413–417.
- [2] BELTRAMI V, GALLINARO LS, BEZZI M, ANGELICI AM. Carcinoidi polmonari. Analisi di 53 casi. *Chir Ital* 1999; 51: 109–112.
- [3] DAVILLA DG, DUNN WF, TAZELAAR HD, PAIROLERO PC. Bronchial carcinoid tumors. *Mayo Clin Proc* 1993; 68: 795–803.
- [4] DESCOVICH P, ANSALONI L, GRAZIA M, BAZZOCCHI R. I carcinoidi bronchiali la nostra esperienza su 35 osservazioni. *Minerva Chir* 2000; 55: 113–119.
- [5] DUCROCO X, THOMAS P, MASSARD G, BARSOTTI P, GIUDICELLI R, FUENTES P, WIHLM JM. Operative risk and prognostic factors of typical bronchial carcinoid tumors. *Ann Thorac Surg* 1998; 65: 1410–1414.
- [6] DUSMET ME, MCKNEALLY MF. Pulmonary and thymic carcinoid tumors. *World J Surg* 1996; 20: 189–195.
- [7] FERGUSON MK, LANDREAU RJ, HAZELRIGG SR, ALTORKI NK, NAUNHEIM KS, ZWISCHENGERGER JB, KENT M, YIM YP. Long-term outcome after resection for bronchial carcinoid tumors. *Eur J Cardiothorac Surg* 2000; 18: 156–161.
- [8] FROUDARAKIS M, FOURNEL P, BURGARD G. Bronchial carcinoids. A review of 22 cases. *Oncology* 1996; 20: 189–195.
- [9] GALANIS E, KVOLS LK, RUBIN J. Carcinoid syndrome. *J Clin Oncol* 1998; 16: 796–798.
- [10] GINSBERG JR. Carcinoid tumors. In: Shields TW, LoCicero III J, Ponn RB, editors. *General Thoracic Surgery*. 5th ed. Vol 1. Philadelphia, Lippincott Williams & Wilkins 1999: 1493–1504.
- [11] GOODWIN J. Carcinoid tumors: an analysis of 2837 cases. *Cancer* 1975; 36: 560–569.
- [12] HARPOLE HD, FELDMAN JM, BUCHNANA S, YOUNG WG, WOLFE WG. Bronchial carcinoid tumors: A retrospective analysis of 126 patients. *Ann Thorac Surg* 1992; 54: 50–54.
- [13] KLOPPPEL G, HEITZ PU. Classification of normal and neoplastic neuroendocrine cells. *Ann NY Acad Sci* 1994; 733: 19–23.
- [14] KULKE MH, MAYER RJ. Carcinoid tumors. *N Engl J Med* 1999; 340: 858–868.
- [15] MARTINI N, ZAMAN MB, BAINS MS, BURT ME, MCCORMACK PM, RUSH VW, GINSBERG RJ. Treatment and prognosis in bronchial carcinoids involving regional lymph nodes. *J Thorac Cardiovasc Surg* 1994; 107: 1–6.
- [16] MARTY-ANÉ CH-H, COSTES V, PUJOL J-L, ALAUZEN M, BALDET P, MARY H. Carcinoid tumors of the lung: Do atypical features require aggressive management? *Ann Thorac Surg* 1995; 59: 78–83.
- [17] MODLIN IM, SANDOR A. An analysis of 8305 cases of carcinoid tumors. *Cancer* 1997; 79: 813–829.
- [18] MOUNTAIN CF. Revisions in the international system for staging lung cancer. *Chest* 1997; 111: 1710–1717.
- [19] NORTON JA, LEVIN B, JENSEN RT. Cancer of the endocrine system. In: DeVita VT, Hellman S, Rosenberg SA, editors. *Cancer, Principles and Practice of Oncology*. J.B. Lippincott Co., 4th ed., Philadelphia, USA, 1993: 1333–1345.
- [20] OBERNDORFER S. Karzinoide Tumoren des Dünndarms. *Frankf Z Pathol* 1907; 1: 426–430.
- [21] SHAH R, SABANATHAN S, MEARNES J, RICHARDSON L, GOULDEN C. Carcinoid tumor of the lung. *J Cardiovasc Surg (Torino)* 1997; 38: 187–189.
- [22] SŁODKOWSKA J, SIKORA J, ANDROSIUK W, RUDZINSKI P, RADOMYSKI A. Lung carcinoids. Tumor angiogenesis in relation to clinicopathologic characteristics. *Ann Quant Cytol Histol* 1999; 21: 267–272.
- [23] SOGA J, YAKUWA Y. Bronchopulmonary carcinoids: An analysis of 1875 reported cases with special reference to a comparison between typical carcinoids and atypical varieties. *Ann Thorac Cardiovasc Surg* 1999; 5: 211–219.
- [24] STEFANI A, MORANDI U, URGESSE A, RIVASI F, LODI R. Carcinoid tumors of the lung. An analysis of 65 operated cases. *J Cardiovasc Surg (Torino)* 1995; 40: 607–612.
- [25] STOBERNACK A, ENGELMANN C, STRAUB H, KLEMMANN A. Zur chirurgischen Therapie der Bronchuskarzinoide. *Zbl Chir* 1990; 115: 23–34.
- [26] TRAVIS WD, COLBY TV, CORRIN B, SHIMOSATO Y, BRAMBILLA E. Histological typing of lung and pleural tumors. *International histological classification of tumors*. Berlin: Springer Verlag, 1999.
- [27] WEISSBERG D. Bronchial gland tumors. In: Pearson FG, editor. *Thoracic Surgery*. New York, Churchill Livingstone 1995: 62.