

CLINICAL STUDY

Near infrared spectroscopy in monitoring of head and neck microvascular free flaps

Ladislav CZAKO¹, Kristian SIMKO¹, Marek SOVIS¹, Ivana VIDOVA¹, Barbora SUFLIARSKY¹, Peter ODNAGA², Branislav GALIS¹

Department of of Oral and Maxillofacial Surgery of Medical Faculty of Comenius University and University Hospital Bratislava, Bratislava, Slovakia. brano.galis@gmail.com

ABSTRACT

OBJECTIVES: Microvascular free-flap monitoring is crucial to the early detection of flap failure and increases the chance of early intervention in case of disruption of perfusion to a flap. Many clinical alternatives to classical clinical flap monitoring have been proposed, such as color duplex ultrasonography, handheld Doppler, flap thermometry, or implantable Doppler flowmetry. Early detection of critical changes in tissue oxygenation can lead to successful surgical intervention when problems with flap nutrition arise.

METHODS: Our clinical study seeks to investigate dynamic monitoring of free flaps with near-infrared spectroscopy (NIRS). NIRS is a non-invasive instrumental technique used for continuous monitoring of peripheral tissue oxygenation (StO₂) and microcirculation. All patients were included prospectively from one clinical center.

RESULTS: During the clinical research period, 18 patients underwent extraoral head and neck reconstruction with one of three types of free flap, namely with radial forearm free flap (RFFF), anterolateral thigh flap (ALT) or fibula free flap (FFF). Measurements of flap perfusion were taken using NIRS during intraoperative and postoperative phases for 71 hours on average. A total of 6 perfusion disorders were recorded, of which three originated from microanastomoses and three from postoperative bleeding and compression of pedicle. NIRS showed characteristic changes in all 6 cases that were returned to the operating theatre owing to pedicle compromise. In these cases, NIRS had detected the pedicle compromise before it was clinically identified. A single StO₂ monitoring was able to detect the vascular compromise with 100% sensitivity and 95.65% specificity. None of the cases were falsely positive. In our study, all compromised flaps were accurately identified by means of NIRS. In most cases, the changes in oxygen saturation became evident on NIRS prior to being clinically observed.

CONCLUSION: In our study, the continuous NIRS monitoring securely detected the early stages of arterial and venous thromboses or pedicle compression. The most important aspects of monitoring the flaps' microvascular perfusion and vitality by means of NIRS lie in its function of recording the dynamics of changes in the values of absolute oxygen saturation (StO₂ > 50%) alongside with detecting a 30% decrease in tissue saturation over a 60-minute interval (60 min StO₂ >30%) before the clinical changes in the microvascular flap become observable. In cases of pedicle compression, the average time of appearance of signs of StO₂ values dropping below the reference interval (as detected by NIRS) was 1:29:02 hour (SD= 0:58:42 h) prior to the occurrence of any clinical signs, while in cases of microvascular anastomosis complications, it was 0:35:23 hour (SD=0:08:30 h) (SD = 0:08:30 h) (Tab. 3, Fig. 7, Ref. 42). Text in PDF www.elis.sk

KEY WORDS: microvascular free flap, near infrared spectroscopy, monitoring of head and neck.

Introduction

Head and neck reconstructions with microvascular free flaps are nowadays considered the gold standard for any complex reconstruction. Their success rate is reported to be over 95 % (1). Despite their high success rate, 12–17 % of cases need re-exploration because of postoperative vascular complications threatening the

flap's viability (2). Flap salvage rates have been reported to exceed 50 % (3). Complications usually occur within the first 36 hours of the initial surgery and become irreversible if not corrected within 12 hours. Free flap failure can cause significant complications in the form of aesthetic and functional problems, as well as generate additional healthcare costs. The ideal monitoring system should be non-invasive for the patient, accurate, rapidly responsive, easily applicable and cost-efficient (4, 5). Multiple conventional flap monitoring techniques and systems have been developed over the past years in clinical settings. Each technique has its advantages and disadvantages while none of them has reached the level of being accepted as the standard monitoring system (6).

Monitoring systems are classified as either experimental or clinical; yet both are widely used in the clinical setting. Experimental methods include laser Doppler flowmetry, color duplex

¹Department of of Oral and Maxillofacial Surgery of Medical Faculty of Comenius University and University Hospital Bratislava, Bratislava, Slovakia, and ²Department of Anesthesiology of Medical Faculty of Comenius University Bratislava, Bratislava, Slovakia

Address for correspondence: Branislav GALIS, MDDr, PhD, Department of of Oral and Maxillofacial Surgery of Medical Faculty of Comenius University and University Hospital Bratislava, Ružinovská 6, SK-826 06 Bratislava, Slovakia.

ultrasonography, microdialysis, and lactate and glucose pinprick levels (5, 7). Clinically used systems include flap thermometry, conventional monitoring (capillary refill, color, temperature, pinprick), handheld Doppler, flap thermometry, implantable Doppler and near-infrared spectroscopy (NIRS)(8). Approximately, 60–70 % of microsurgeons routinely utilize one of many adjunct monitoring devices in addition to clinical flap assessment (4, 9). Standardly, the monitoring of microvascular flaps should be performed by nurses or physicians every half hour on the first postoperative day, hourly on the second postoperative day, every 2 hours on the third day, and every 4 hours thereafter. Clinical examination requires significant clinical expertise and experience, and when used alone, it is associated with a salvage rate in the range of 30–70 % of compromised flaps (10). Conventional monitoring is usually applied to all free flaps with adjuncts mainly assisting in detecting early failure, which in turn increases the salvage rate (11).

Near-infrared spectroscopy

Near-infrared spectroscopy (NIRS), first introduced in 1977 by Jöbsis, is a tool that allows a non-invasive measurement of tissue components. Various experimental and clinical studies using NIRS to study tissue perfusion and oxygenation have been reported in many fields (12, 13). Selective light absorption by hemoglobin results in an attenuated optical signal that permits measurement of hemoglobin and oxygen content. The technique of NIRS depends on the ability of light in the near-infrared region (700–1000 nm) of the electromagnetic spectrum to penetrate biological tissues (including bones), as well as on the selective absorption of this light within the tissues by oxygen-dependent chromophores, i.e., by hemoglobin, myoglobin and oxidized cyt aa3 (14–17). Recently, NIRS has been reported to be a reliable diagnostic modality for free-flap monitoring due to its ability to precisely detect decreases in flap perfusion. Several reviews of free-flap monitoring have concluded that NIRS is one of the best free-flap monitoring devices (3, 15, 18).

The purpose of this clinical study was to use NIRS to continuously measure the StO_2 values in extraoral free flap reconstructions during pedicle vessel occlusion while collecting the experimental data under optimized conditions. The present clinical study was designed to determine the reliability, sensitivity, and applicability of a NIRS monitor (INVOS™ Cerebral/Somatic Oximeter Monitor Model 5100C Somanetics Corp., USA) in assessing the viability of free flaps used in reconstructive head and neck surgery by means of RFFF, ALT and FFF free flaps.

Materials and methods

Subjects

This prospective observational clinical study was conducted on patients after head and neck reconstruction with microvascular free flaps with extraoral skin layer in the Department of Oral and Maxillofacial Surgery, University Hospital of Comenius University, Bratislava. All clinical measurements were carried out according to the Declaration of Helsinki. The study protocol was approved by the local Ethics Committee of University Hospital Bratislava, and written informed consent was obtained from all pa-

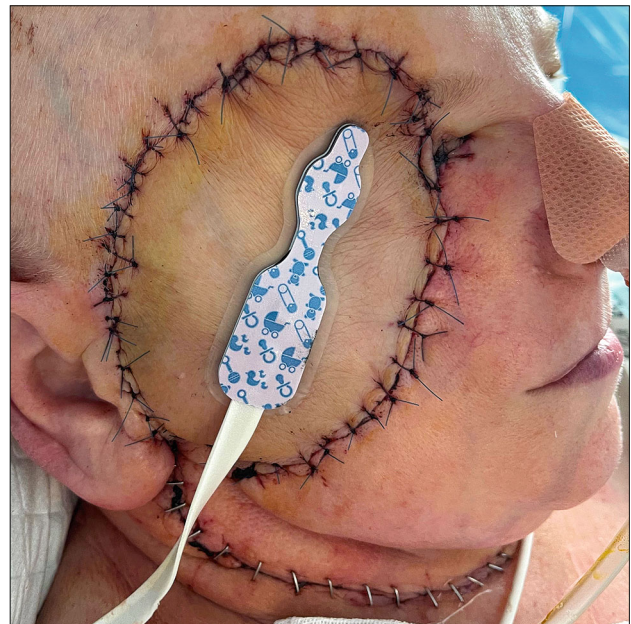


Fig. 1. Neonatal NIRS sensor is attached to the flap skin via the adhesive surface of the disposable shield.

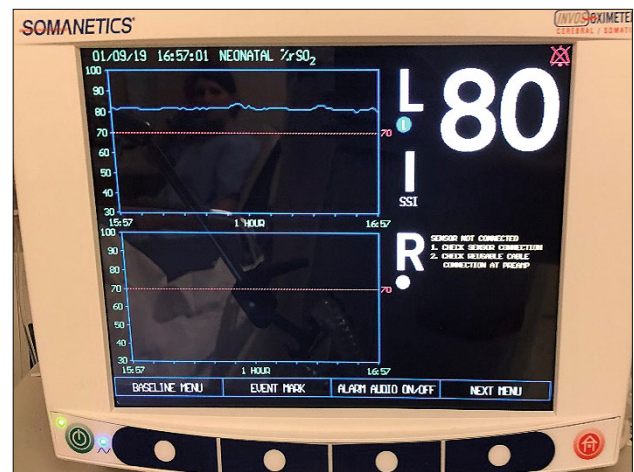


Fig. 2. INVOS Oximeter (Model 5100C) StO_2 measurement with one sensor.

tients prior to initiating the oncological treatment. Patients included were 40 to 70 years old, 6 were female (67.5; SD = 6.14) and 14 were male (67.25; SD = 11.32). Those with the history of healing complications, systemic skin disease or infection with a potential to affect the healing were excluded. Postoperative measurements were taken from the recipient sites after free microvascular flap reconstructions with a skin paddle. StO_2 measurements were made on three types of free flaps, namely on radial forearm free flaps (RFFF), anterolateral thigh flaps (ALT) and composited fibula free flaps (FFF) used in extraoral head and neck reconstructions. For clinical monitoring an INVOS Oximeter (Model 5100C, Somanetics Corp., USA), StO_2 monitor, and its single-use measurement probe were used. StO_2 is a dynamic value that changes with

oxygen supply and consumption and can signal the early stage of flap failure (Fig. 2).

NIRS measurement protocol

The INVOS Cerebral/Somatic oximetry infant-neonatal sensor and INVOS Cerebral/Somatic oximetry adult sensor were used. Measurements were made immediately after the reconstruction in the head and neck regions. After a ten-minute taking of baseline readings, the operation team waited for tissue oxygen saturation (StO_2) levels to become continuously constant (Fig. 1).

At the end of the operation, the measurement probe was attached using adhesive to the visible skin paddle to provide continuous monitoring for 48 to 96 hours ($M = 71$ hours; $SD = 41:02:16$). In addition, the clinical staff performed routine clinical monitoring of the flap, using clinical markers of skin color and temperature, capillary refill time and tissue turgor. The monitors were set to activate alarm to signal a decrease in StO_2 values by 30 % or more of the starting value as in other studies. Flap complications included vascular compromise (either arterial or venous), thrombosis, occlusion or excessive hematoma formation, wound separation, and local infection occurring in this period. Complications were defined as being “early” if intervention was required within 24 hours of surgery or “late” if they occurred thereafter. Different types of flap complications requiring surgical intervention were recorded. Leech therapy was not applied.

Statistical analysis

During the measurement of free flap type groups (RFFF, ALT and FFF), StO_2 values were evaluated and tested with Microsoft Office Excel 365 and IBM SPSS v 22 (IBM corp., Armonk, NY) for differences, using one-way ANOVA. The paired samples *t*-test was used to evaluate day-to-day changes in average StO_2 levels. The difference in average StO_2 values between groups with complications and unproblematic flaps was evaluated using the independent sample *t*-test. The independent samples *t*-test was used to analyze differences in StO_2 levels between groups of venous, arterial or non-flap-associated complications. Finally, we determined the average optimal and limit StO_2 levels of individual microvascular free flaps used for reconstruction in head and neck regions.

Results

In total, 20 head and neck reconstructions with 26 NIRS measurements conducted on 18 patients were included in the statistical analysis. Two patients underwent repeated reconstruction with microvascular free flap for flap failure. In the series of 20 reconstructions, we used 11 RFFF, 6 ALT and 3 composite FFF free flaps. Fourteen patients treated with reconstructions (70 %) experienced an uneventful postoperative period. There were two flap losses: one flap loss due to venous thrombosis, and one due to arterial ischemia. In total, we recorded six perfusion disorders: three originated from microanastomosis and three from postoperative bleeding with subsequent compression of the pedicle. In the group with microanastomosis, there were two cases of microvascular venous thrombosis and one with arterial thrombosis. The

Tab. 1. Characteristics of complications, flap failing and re-explorations.

Case No (n=6)	Flap type	Finding at re-exploration (n=6)	Outcome
1	ALT	Venous thrombosis	Salvage
2	ALT	Arterial thrombosis	Failure
3	ALT	Venous thrombosis	Failure
4	RFFF	Pedicle compression	Salvage
5	RFFF	Pedicle compression	Salvage
6	RFFF	Pedicle compression	Salvage

data on timing, management and outcome of all complications are compiled in Table 1. All complications occurred within 2 days of reconstruction. All 6 cases of circulation compromise were identified by means of NIRS prior to their clinical assessment, while all subsequent surgical flap explorations supported the NIRS findings on every occasion. Subsequently, six re-exploration procedures were indicated, and in all of them, the diagnosed complications were conclusively confirmed.

We lost two microvascular flaps (10 %) in total. Each of the two flaps that ultimately failed (one for venous thrombosis and one for arterial thrombosis) was revised once. In case of venous thrombosis, we achieved an immediate, but transitory success. In case of arterial thrombosis, despite the repeated suturing of the arterial anastomosis, the restoration of flap perfusion was not achieved. All lost flaps were replaced with a similar microvascular free flap with a successful outcome.

The overall flap survival rate (including the four flaps successfully revised for perfusion failure) was 84.62 % (22/26), however the rate of flaps salvaged as a result of successful revisions (due to flap complications) was 66.67 % (4/6).

During continuous NIRS monitoring of flaps without any type of complications (thrombosis or pedicle compression due to bleeding) the measured StO_2 levels remained stable, and we were able to calculate and set the average StO_2 values of tissue saturation of microvascular flap for each type of used flaps.

Statistical analysis with ANOVA and Welch test showed that in the group without flap complications, there were significant differences in the measured NIRS values of StO_2 between individual flap types (ALT, RFF and FFF). The NIRS values in patients with ALT flaps ($M = 78.8$; $SD = 5.51$) and RFFF flaps ($M = 78.76$; $SD = 12.59$) were significantly higher than those in patients with FFF flaps ($M = 66.59$; $SD = 7.73$). The measured optimal StO_2 values for each flap are presented in Table 2.

In all 6 cases, the presence of perfusion disorder in microvascular flaps became evident from the readings of a gradual decrease

Tab. 2. Average tissue oxygen saturation (StO_2) levels in different flap types.

Flap type	Cases (n= 20)	StO_2 (%)
RFFF	11	78.76±12.59 (15–95)
ALT	6	78.70±5.51 (54–95)
FFF	3	66.58±7.73 (44–83)

Values are means±SD (range)

Tab. 3. Monitored measurement intervals (hours).

Measurement (No)	Hourly intervals	StO ₂
1.	Initial StO ₂ levels immediately after operation	74.59±11.66 (73–76)
2.	5 hours until revision	71.27±12.20 (69–72)
3.	4 hours until revision	71.51±11.08 (70–72)
4.	3 hours until revision	68.64±12.92 (67–70)
5.	2 hours until revision	56.31±13.17 (54–57)
6.	1 hours until revision	49.85±14.37 (48–51)
7.	1 hours after revision	67.88±7.85 (66–68)

Values are means±SD (range)

in the measured StO₂ values on NIRS monitor. In cases where the decrease in perfusion was caused by compression of the pedicle as a result of bleeding into the space of the neck between the flap and vessels, the “watch and wait” rule was followed. In cases of fast stabilization of StO₂ levels we did not proceed to carry out the flap revision. In 3 cases, where the depression in NIRS values fell below the reference interval, the flap was subjected to exploration. In the group of patients with microvascular anastomotic complications (two cases of venous thrombosis and one case of arterial thrombosis), the decrease in absolute StO₂ values below the reference interval had been confirmed before the clinical changes became apparent on the microvascular flap.

The largest decreases in NIRS values took place prior to the surgical revision. Their dynamics were analyzed in retrospection after the completion of revision. As shown in Table 3, analyzed were the NIRS values found to be recorded during a time span of 5 hours preceding the revision (statistical analysis of repeated measurements). The initial values measured within a 1-hour period following the surgery (measurement #1) and the values measured 1 hour after the revision (measurement #7) were included into the analysis. The time of the largest decrease in StO₂ NIRS value relative to that obtained by way of measurement #1 was assessed. In cases of pedicle compression, the average time of appearance of first signs of StO₂ values dropping below the reference interval (as detected by NIRS) was 1:29:02 hour (SD = 0:58:42 h) prior to the occurrence of any clinical signs, while in

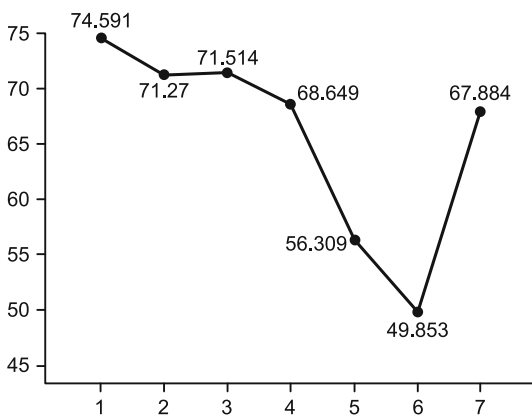


Fig. 3. Average StO₂ values at individual measurement intervals.

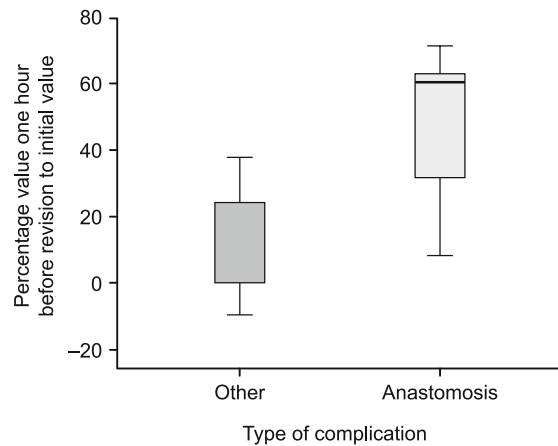


Fig. 4. Boxplot graph showing the percentage values of decrease compared to the initial value of StO₂ measurement for individual types of complications.

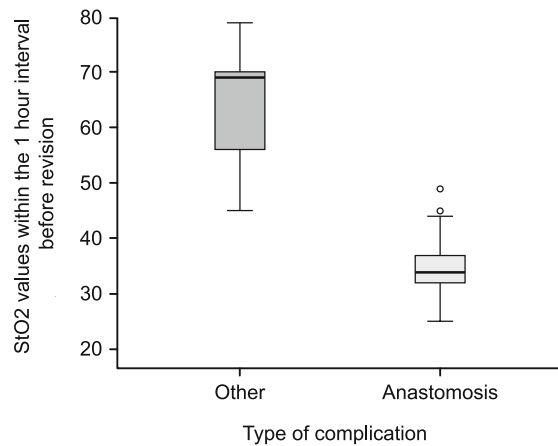


Fig. 5. Boxplot graph showing NIRS values of StO₂ measurement for each type of complication during the hour before revision.

cases of microvascular anastomosis complications, it was 0:35:23 hour (SD = 0:08:30 h).

Analysis of variance (ANOVA) of repeated measurements revealed that there were significant changes in StO₂ values (F (6.1548) = 221.545; p < 0.001) when flap complications occurred. From the given analysis of time interval differences, the largest decrease in NIRS values was identified during the interval of 2–3 hours before the revision. *Post hoc* pairing using Bonferroni correction showed that the largest difference between StO₂ values recorded in consecutive hourly intervals, namely the difference between the values of measurement #4 (M = 68.65; SD = 12.92) and values of measurement #5 (M = 56.31; SD = 13.17) taken 2 and 3 hours before revision, respectively, was significant; (p < 0.001) (Fig. 3).

Statistical analysis also identified a percentage decrease in StO₂ levels signaling the initial stage of microvascular flap perfusion disorder. The mean decrease in StO₂ NIRS values for all complications was 53.30 (SD = 15.65), which represents an average percent-

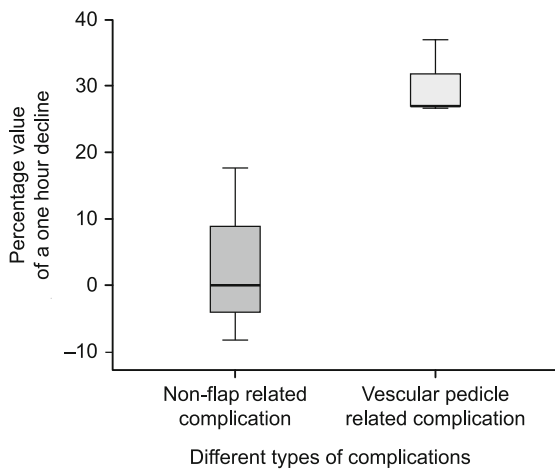


Fig. 6. Boxplot graph showing the percentage decrease in the average of StO_2 values compared to the previous 60-minute interval for each type of complication.

age decrease of 23.26 % (SD = 25.35 %). As to the group of flap complications caused by compression of the pedicle, the ratio of StO_2 values measured one hour before the revision relative to the values obtained from measurement #1 was 65.08 on average (SD = 7.38) which translates to a percentage decrease of 8.5 % (SD = 12.67 %) of the former value. As to the group of anastomotic complications, the StO_2 value reached the value of 35.01 (SD = 4.58, CI = 34.23–35.8).

This means that the average percentage of StO_2 values from measurement #1 was 51.21 % (SD = 18.96 %, CI = 48.01–54.49 %). The largest dynamic decrease in StO_2 values occurred 120 minutes before the revision in our group, where during the second hour before the revision, a depression in StO_2 values took place, namely by 41.16 % on average (SD = 9.35 %, CI = 39.53–42.78 %) (Figs 4 and 5).

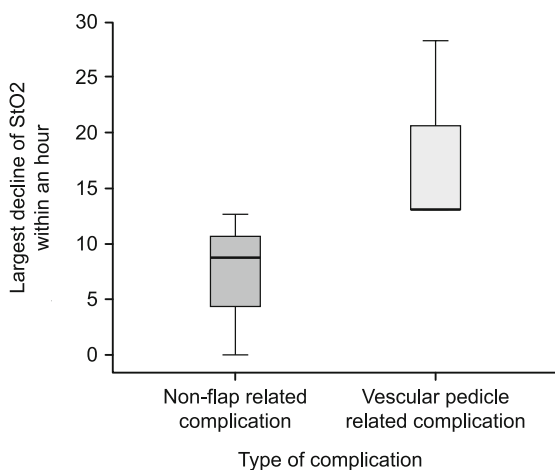


Fig. 7. Boxplot graph showing the decrease in average StO_2 values compared to the previous 60-minute interval for each type of complication.

In the group of patients with microvascular anastomotic complications, the largest decrease in the average values of StO_2 tissue saturation was observed over the given 60-minute time intervals. This dynamic decrease in StO_2 values has been examined retrospectively after the surgical revision by evaluating the largest decrease in NIRS values (average value of measurements taken for 60 minutes in two consecutive hourly intervals).

As for all complications, the largest mean decrease in NIRS values taken over the given 60-minute intervals was 12.64 (SD = 9.17) which represents an average percentage decrease of 16.68 % (SD = 17.33 %). As for separate flap complications, in the group with compressed pedicle, the ratio of the largest decrease in StO_2 values in each 60-minute interval relative to the initially measured NIRS value was 7.14 (SD = 6.49 StO_2) on average, which translates to a percentage decrease of 3.23 % of the initial value (SD = 13.18 %). In the group with microvascular anastomosis, the values of the decrease in StO_2 per 60 minutes reached the value of 18.14 (SD = 8.8 StO_2), thus the percentage decrease in average StO_2 value as compared to the previous interval was 30.125% (SD = 5.9 %) (Figs 6 and 7).

Discussion

The criteria for flap monitoring were defined in 1975 by Creech and Miller's (19). Flap monitoring should be noninvasive and harmless for both patient and flap, as well as needs to be cheap, rapid, repeatable, reliable, recordable, accurate, objective, applicable to all types of flaps, and simple to use even for an inexperienced member of staff. There is a variety of monitoring techniques, yet clinical monitoring is the gold standard. There are many modes of monitoring, such as pulse oximetry, surface temperature measurement, externalization of part of a buried flap, white-light spectrometry, fluorometry, microdialysis, ultrasound, implanted Doppler, laser Doppler, perfusion photoplethysmography, impedance plethysmography, nuclear medicine, subcutaneous pH measurement, hydrogen clearance (20) or pinprick testing (21). Clinical monitoring is still the gold standard. The use of NIRS for cerebral and myocardial oxygenation monitoring was first reported by Jöbsis (12), albeit Irwin (22) and Hayden (23) used the NIRS devices for flap monitoring.

Nevertheless, as for the reconstructive teams without long-term experience or for departments with no history of reconstructive surgery, the NIRS monitoring is very helpful. The current literature dealing with flap monitoring does not evaluate mutual superiorities of three- and two-wavelength NIRS systems (e.g., InvoS Oximeter 5100C) (24) A vascular complication is predicted when the drop rate in StO_2 ($\Delta\text{StO}_2/\Delta t$) is greater than 20 % per hour and is sustained for more than 30 minutes (4) or when $\text{StO}_2 \leq 30$ % of the initial value (25). The values clearly represent the status of flap even for unexperienced personnel who, when in doubt, can contact responsible surgeons or make any other digital records (photos, video) for consideration, because the data might detect the early stages of flap failure (26) with 99.1 % sensitivity and 99.9 % specificity. (27) Despite its relatively high price (which varies from country to country), NIRS monitoring represents a

cost-effective equipment (3,28–30) as compared to the cost of long-term training of personnel.

In a study conducted on a group of patients, NIRS monitoring can signal a compromised flap as soon as tens of minutes before clinical signs occur, which enables an early initiation of re-exploration (31). The ischemic time plays a significant role in re-exploration of flap. (32–34) The salvage rate of compromised flaps with vascular complications that were saved by means of NIRS monitoring was 88.3%– 96.6% (25,27,30,35,36).

NIRS monitoring provides many advantages that are ideal for developing more accessible applications. The function of remote monitoring is essential in improving the quality and advantages of monitoring (6) as e.g. by means of wi-fi (37,38) and remote (home, distant) monitoring (39). A limitation of NIRS monitoring emerges when it is used in buried flaps, where the optical information coming from the depth interacts and mixes with the surface information.(40) The measurement depth varies from 2mm to 25 mm, depending on the type of console and probe. (27)

The NIRS monitoring of a study group can record the changes in patients' overall status of health and detect the response in the microcirculatory system (e.g., hypotension or cardiac failure) immediately. Therefore, it is necessary to assess the overall health by means of values recorded by monitoring in cases, where the influence of general health status could have a significant impact. (41) However, a concern of potential false-positive rates should be considered in cases when the sensors can become dislodged, room light is intensive, or the thin flap layer overlaps the “halo space”, as well as in cases with hematoma, sanguineous exudation (20) or in relation to the position of the parts of the body (e.g., head rotation) (42).

The most of the complications occur during the first 48 hours (9,20). It was considered as the minimal monitoring time, but when the sensors were in good condition and there was no failure in their adhesion the monitoring did not detach.

Conclusion

NIRS can be used to indicate StO_2 changes in head and neck surgery after microvascular free-flap reconstructions with the pedicle vessel occlusion as well as to differentiate between pedicle artery and vein occlusion or both in case of kinking. NIRS showed characteristic changes in all cases that were returned to the operation theater for pedicle compromise. In all these cases, NIRS had identified the pedicle compromise before the clinical changes in the microvascular flap became observable. There were no false-positive cases. In most cases, there was evidence of changes in oxygen saturation on NIRS prior to clinical observation.

The final conclusion of our studies is that the most important aspects of the monitoring of flaps' microvascular perfusion and vitality by means of NIRS lie in its function of recording the dynamics of changes in the values of absolute oxygen saturation ($StO_2 > 50\%$) alongside with detecting a 30% decrease in tissue saturation over a 60-minute interval (60 min $StO_2 > 30\%$) before the clinical changes in the microvascular flap become observable. In cases of pedicle compression, the average time of appearance of signs of StO_2 values dropping below the reference values (as

detected by NIRS) was 1:29:02 hour (SD = 0:58:42 h) prior to the occurrence of any clinical signs, while for cases of microvascular anastomotic complications, it was 0:35:23 hour (SD = 0:08:30 h). NIRS monitoring is a simple, noninvasive, painless, non-expensive, easy to interpret, exact and objective monitoring technique.

References

1. **Wei FC, Mardini S.** Free-style free flaps. *Plast Reconstr Surg* 2004; 114 (4): 910–916.
2. **Hosein RC, Cornejo A, Wang HT.** Postoperative monitoring of free flap reconstruction: A comparison of external Doppler ultrasonography and the implantable Doppler probe. *Can J Plast Surg* 2016; 24 (1): 11–19.
3. **Repež A, Oroszy D, Arnež ZM.** Continuous postoperative monitoring of cutaneous free flaps using near infrared spectroscopy. *J Plast Reconstr Aesthetic Surg* 2008; 61 (1): 71–77.
4. **Keller A.** A new diagnostic algorithm for early prediction of vascular compromise in 208 microsurgical flaps using tissue oxygen saturation measurements. *Ann Plast Surg* 2009; 62 (5): 538–543.
5. **Jones BM.** Monitors for the Cutaneous Microcirculation. *Plast Reconstr Surg* [Internet]. 1984 May; 73 (5): 843–850. <http://journals.lww.com/00006534-198405000-00025>
6. **Moubayed SP, Mourad M, Urken ML.** What Are the Optimal Monitoring Techniques in Head and Neck Microvascular Reconstruction? *Orl* 2016; 78 (5): 241–244.
7. **Setälä L, Papp A, Romppanen EL, Mustonen P, Berg L, Härmä M.** Microdialysis detects postoperative perfusion failure in microvascular flaps. *J Reconstr Microsurg* 2006; 22 (2): 87–95.
8. **Yuen JC, Feng Z.** Monitoring Free Flaps Using the Laser Doppler Flowmeter: Five-Year Experience. *Plast Reconstr Surg* [Internet] 2000 Jan; 105 (1): 55–61. <http://journals.lww.com/00006534-200001000-00009>
9. **Zoccali G, Molina A, Farhadi J.** Is long-term post-operative monitoring of microsurgical flaps still necessary? *J Plast Reconstr Aesthetic Surg* 2017; 70 (8): 996–1000.
10. **Kohlert S, Quimby AE, Saman M, Ducic Y.** Postoperative Free-Flap Monitoring Techniques. *Semin Plast Surg* 2019; 33 (1): 13–16.
11. **Salgarello M, Pagliara D, Rossi M, Visconti G, Barone-Adesi L.** Postoperative Monitoring of Free DIEP Flap in Breast Reconstruction with Near-Infrared Spectroscopy: Variables Affecting the Regional Oxygen Saturation. *J Reconstr Microsurg* 2018; 34 (6): 383–388.
12. **Jöbsis FF.** Noninvasive, Infrared Monitoring of Cerebral and Myocardial Oxygen Sufficiency and Circulatory Parameters. *Science* (80-). 1977 Dec; 198 (4323): 1264–1267.
13. **Bale G, Elwell CE, Tachtsidis I.** From Jöbsis to the present day: a review of clinical near-infrared spectroscopy measurements of cerebral cytochrome-c-oxidase. *J Biomed Opt* 2016; 21 (9): 091307.
14. **Wray S, Cope M, Delpy DT, Wyatt JS, Reynolds EOR.** Characterization of the near infrared absorption spectra of cytochrome aa3 and haemoglobin for the non-invasive monitoring of cerebral oxygenation. *BBA - Bioenerg*. 1988; 933 (1): 184–192.
15. **Scholkmann F, Kleiser S, Metz AJ, Zimmermann R, Mata Pavia J, Wolf U et al.** A review on continuous wave functional near-infrared spectroscopy and imaging instrumentation and methodology. *Neuroimage* [Internet] 2014; 85: 6–27. <http://dx.doi.org/10.1016/j.neuroimage.2013.05.004>

16. Thorniley MS, Sinclair SJ, Barnett NJ, Shurey CB, Green CJ. The use of near-infrared spectroscopy for assessing flap viability during reconstructive surgery. *Br J Plast Surg*. 1998; 51 (3): 218–226.
17. Chen Y, Shen Z, Shao Z, Yu P, Wu J. Free flap monitoring using near-infrared spectroscopy: A systemic review. *Ann Plast Surg* 2016; 76 (5): 590–597.
18. Starr NC, Slade E, Gal TJ, Adekunle A, Bigler D, Cheung B et al. Remote monitoring of head and neck free flaps using near infrared spectroscopic tissue oximetry. *Am J Otolaryngol - Head Neck Med Surg* 2021; 42 (1).
19. Creech B, Miller S. *Skin Flaps*. Grabb W, Myers MB, editors. Boston: Little Brown and Company; 1975. 548 p.
20. Whitaker IS, Pratt GF, Rozen WM, Cairns SA, Barrett MD, Hiew LY et al. Near infrared spectroscopy for monitoring flap viability following breast reconstruction. *J Reconstr Microsurg* 2012; 28 (3): 149–154.
21. Nagata T, Masumoto K, Uchiyama Y, Watanabe Y, Azuma R, Morimoto Y et al. Improved technique for evaluating oral free flaps by pinprick testing assisted by indocyanine green near-infrared fluorescence angiography. *J Cranio-Maxillofacial Surg* 2014; 42 (7): 1112–1116.
22. Irwin MS, Thorniley MS, Dore´ CJ, Green CJ. Near infra-red spectroscopy: a non-invasive monitor of perfusion and oxygenation within the microcirculation of limbs and flaps. *Br J Plast Surg*. 1995; 48 (1): 14–22.
23. Hayden RE, Tavill MA, Nioka S, Kitai T, Chance B. Oxygenation and Blood Volume Changes in Flaps According to Near-Infrared Spectrophotometry. *Arch Otolaryngol - Head Neck Surg*. 1996 Dec; 122 (12): 1347–1351.
24. Olenczak JB, Murariu D, Ikeda K, Thiele RH, Campbell CA. Tissue Monitoring with Three-Wavelength Light Emitting Diode-Based Near-Infrared Spectroscopy. *J Reconstr Microsurg* 2016; 32 (9): 712–718.
25. Koolen PGL, Vargas CR, Ho OA, Ibrahim AMS, Ricci JA, Tobias AM et al. Does increased experience with tissue oximetry monitoring in microsurgical breast reconstruction lead to decreased flap loss? the learning effect. *Plast Reconstr Surg* 2016; 137 (4): 1093–1101.
26. Yano A, Orihashi K, Yoshida Y, Kuriyama M. Near-infrared spectroscopy for monitoring free jejunal flap. *J Plast Reconstr Aesthetic Surg* 2021; 74 (1): 108–115.
27. Kagaya Y, Miyamoto S. A systematic review of near-infrared spectroscopy in flap monitoring: Current basic and clinical evidence and prospects. *J Plast Reconstr Aesthetic Surg [Internet]* 2018; 71 (2): 246–257. <https://doi.org/10.1016/j.bjps.2017.10.020>
28. Pelletier A, Tseng C, Agarwal S, Park J, Song D. Cost analysis of near-infrared spectroscopy tissue oximetry for monitoring autologous free tissue breast reconstruction. *J Reconstr Microsurg* 2011; 27 (8): 487–493.
29. Lindelauf AAMA, Vranken NPA, Rutjens VGH, Schols RM, Heijmans JH, Weerwind PW et al. Economic Analysis of Noninvasive Tissue Oximetry for Postoperative Monitoring of Deep Inferior Epigastric Perforator Flap Breast Reconstruction: A Review. *Surg Innov* 2020; 27 (5): 534–542.
30. Newton E, Butskiy O, Shadgan B, Prisman E, Anderson DW. Outcomes of free flap reconstructions with near-infrared spectroscopy (NIRS) monitoring: A systematic review. *Microsurgery* 2020; 40 (2): 268–275.
31. Takasu H, Hashikawa K, Nomura T, Sakakibara S, Osaki T, Terashi H. A Novel Method of Noninvasive Monitoring of Free Flaps With Near-Infrared Spectroscopy. *Eplasty* 2017; 17: e37. <http://www.ncbi.nlm.nih.gov/pubmed/29308105> <http://www.pubmedcentral.nih.gov/articlerender.fcgi?artid=PMC5741564>
32. Hofer SOP, Damen THC, Mureau MAM, Rakhorst HA, Roche NA. A critical review of perioperative complications in 175 free deep inferior epigastric perforator flap breast reconstructions. *Ann Plast Surg* 2007; 59 (2): 137–142.
33. Smit JM, Acosta R, Zeebregts CJ, Liss AG, Anniko M, Hartman EHM. Early reintervention of compromised free flaps improves success rate. *Microsurgery* 2007; 27 (7): 612–616.
34. Kohler LH, Köhler H, Kohler S, Langer S, Nuwayhid R, Gockel I et al. Hyperspectral Imaging (HSI) as a new diagnostic tool in free flap monitoring for soft tissue reconstruction: a proof of concept study. *BMC Surg* 2021; 21 (1): 1–9.
35. Lindelauf AAMA, Saelmans AG, van Kuijk SMJ, van der Hulst RRWJ, Schols RM. Near-Infrared Spectroscopy (NIRS) versus Hyperspectral Imaging (HSI) to Detect Flap Failure in Reconstructive Surgery: A Systematic Review. *Life* 2022; 12 (1).
36. Lin SJ, Nguyen MD, Chen C, Colakoglu S, Curtis MS, Tobias AM et al. Tissue oximetry monitoring in microsurgical breast reconstruction decreases flap loss and improves rate of flap salvage. *Plast Reconstr Surg* 2011; 127 (3): 1080–1085.
37. Chung HU, Rwei AY, Hourlier-Fargette A, Xu S, Lee KH, Dunne EC et al. Skin-interfaced biosensors for advanced wireless physiological monitoring in neonatal and pediatric intensive-care units. *Nat Med* 2020; 26 (3): 418–429.
38. Berthelot M, Yang GZ, Lo B. A self-calibrated tissue viability sensor for free flap monitoring. *IEEE J Biomed Heal Informatics* 2018; 22 (1): 5–14.
39. Kozusko S, Gbulie U. Detecting Microsurgical Complications with ViOptix Tissue Oximetry in a Pediatric Myocutaneous Free Flap: Case Presentation and Literature Review. *J Reconstr Microsurg Open* 2018; 03 (01): e8–12.
40. Lartzien R, Planat-Chrétien A, Berger M, Henry M, Coll JL, Dot A et al. Noninvasive monitoring of deep tissue oxygenation in buried flaps by time-resolved near-infrared spectroscopy in pigs. *Plast Reconstr Surg* 2020; 565E–577E.
41. Steele MH. Three-year experience using near infrared spectroscopy tissue oximetry monitoring of free tissue transfers. *Ann Plast Surg* 2011; 66 (5): 540–545.
42. Mitsutake T, Sakamoto M, Horikawa E. Effect of neck and trunk rotation speeds on cerebral cortex activity and standing postural stability: A functional near-infrared spectroscopy study. *J Phys Ther Sci* 2015; 27 (9): 2817–2819.

Received January 18, 2023.

Accepted February 2, 2023.