

CLINICAL STUDY

Early recurrence of focal segmental glomerulosclerosis as an unusual cause of primary kidney transplant malfunction

JAVORKOVA Michaela¹, KOVACOVA Andrea¹, ZITNAKOVA Marcela¹, MARIS Juraj¹, CHRASTINA Martin¹, BREZA Jan^{1,2}, ZILINSKA Zuzana^{1,3}

Department of Urology with the Center for Kidney Transplantation, University Hospital Bratislava, Bratislava, Slovakia. zilinskazu@gmail.com

ABSTRACT

Recurrence of the primary disease is one of the most common causes of graft failure in the first decade after kidney transplantation. We present a case of a patient with an unusually rapid recurrence of focal segmental glomerulonephritis in the graft, the recognition of its occurrence was hampered by the primary graft affection and oligoanuria and by insignificant histological changes in the first two biopsy samples in the early post-transplant period, as well as by unawareness of the disease leading to terminal renal failure, as no renal biopsy was performed due to grade 3 obesity.

Only worsening of hypoalbuminemia and finding of massive proteinuria despite oligoanuria were crucial for further management. Disease recurrence in the graft was confirmed by electron microscopy. However, complex targeted therapy did not result in restoration of graft function and decrease in proteinuria. This case history was aimed to draw attention to the knowledge of the importance of the primary disease confirmed by renal biopsy and early (so called pre-emptive) treatment in case of diseases with a high potential of recurrence (Fig. 7, Ref. 10). Text in PDF www.elis.sk

KEY WORDS: kidney transplantation, recurrence, minimal changes in glomeruli, focal segmental glomerulosclerosis.

Abbreviations: GN – glomerulonephritis, KT – kidney transplantation, MCG – minimal changes in glomeruli, NS – nephrotic syndrome, LM – light microscopy, EM – electronic microscopy, FSGS – focal segmental glomerulosclerosis, s-creat. – serum creatinine, 6-MP – 6-methylprednisolon, BMI – body mass index, HLA – anti-human leukocyte antibodies, CMV – cytomegalovirus, BKV – BK polyomavirus

Introduction

Glomerulonephritis (GN) is the primary cause of terminal renal failure in 30–50 % of the patients, who subsequently undergo a kidney transplantation (KT). With the exception of congenital diseases, all diseases may potentially recur in the transplanted kid-

ney and this occurs in 6–19.4 % of the patients after KT (1, 2). GN recurrence in the transplanted kidney represents the fourth most common cause of graft failure within the first ten years after KT (1.1–8.4 %) (3). Diagnosis of glomerulonephritis after KT relies on the medical history of the failure cause of the native kidney, clinical condition, laboratory findings (haematuria, proteinuria, deteriorated graft function, evidence of organ-specific/non-specific antibodies) and histological findings (3, 4).

Minimal chain disease (MCD) glomerular changes are characterized by a rapid development of nephrotic syndrome (NS) with normal histological findings in light microscopy (LM), but diffuse fusion of pedicel podocytes in electron microscopy (EM). The disease is typical for childhood, less often it appears in adulthood. It is the most common cause of nephrotic syndrome in children (80–90 %), and only in about 15 % of the patients with NS in adulthood (5, 6). After kidney transplantation, the disease recurs in 30–50 % of the patients and it is associated with a poor prognosis. It typically occurs in the early post-transplant period (days 6–60 after KT) (6).

The risk of recurrence of idiopathic focal segmental glomerulosclerosis (FSGS) after primary kidney transplantation is 20–50 %, and in the case of secondary transplantation (if the first graft failed for FSGS) it reaches up to 80 %. Recurrence in the patients after KT is associated with a poor prognosis and usually manifests in the first four weeks after transplantation (7, 8). The mainstay of the treatment is the removal of the so-called circulating factor by

¹Comenius University Faculty of Medicine, Department of Urology with the Center for Kidney Transplantation, University Hospital Bratislava, Bratislava, Slovakia, ²Comenius University Faculty of Medicine, Department of Pediatric Urology, National Institute of Pediatric Diseases, Bratislava, Slovakia, and ³Comenius University Faculty of Medicine, 5th Department of Internal Medicine, University Hospital Bratislava, Bratislava, Slovakia

Address for correspondence: Zuzana ZILINSKA, Assoc Prof, MD, PhD, MPH, MHA, Department of Urology with the Center for Kidney Transplantation, University Hospital Bratislava, Limbova 5, SK-833 05 Bratislava, Slovakia.
Phone: +421.903643622

high-volume plasma exchange or immunoadsorption in combination with administration of anti-CD20 monoclonal antibody (rituximab), boluses of corticosteroids, cyclosporine A, cyclophosphamide in combination with standard immunosuppressive therapy, and ACE-inhibitors or angiotensin II receptor blockers with their antiproteinuric effect (9, 10).

Case

We present the case of a 47-year-old patient with a history of NS, first time hospitalized in 2017 for proteinuria more than 30 g/day, s-creat. 200 µmol/l. Diagnostics was based on clinical condition and laboratory findings, based on which GN-type minimal glomerular changes were considered. Renal biopsy was not performed due to a severe obesity (body mass index, BMI: 44.55 kg/m²). Treatment was based on boluses of corticosteroids (3000 mg

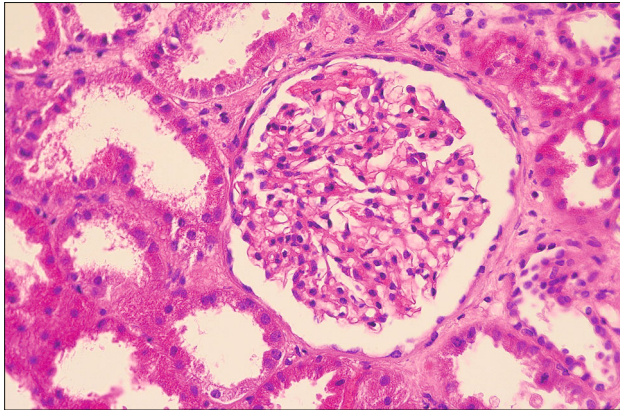


Fig. 1. Normal histological findings in light microscopy

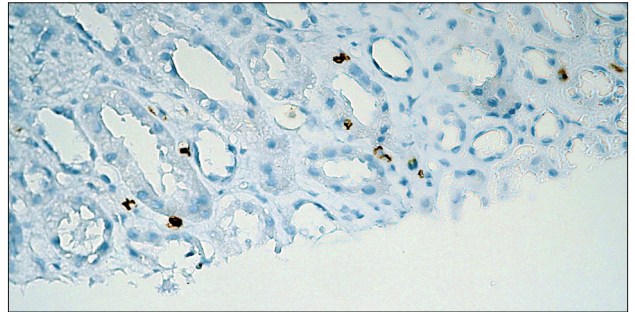


Fig. 2. Borderline TCMR.

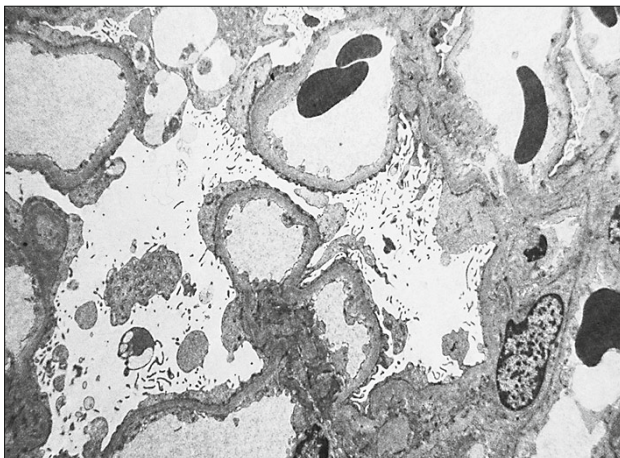


Fig. 3. Electron microscopy: de novo small glomerular abnormalities in a transplanted kidney.

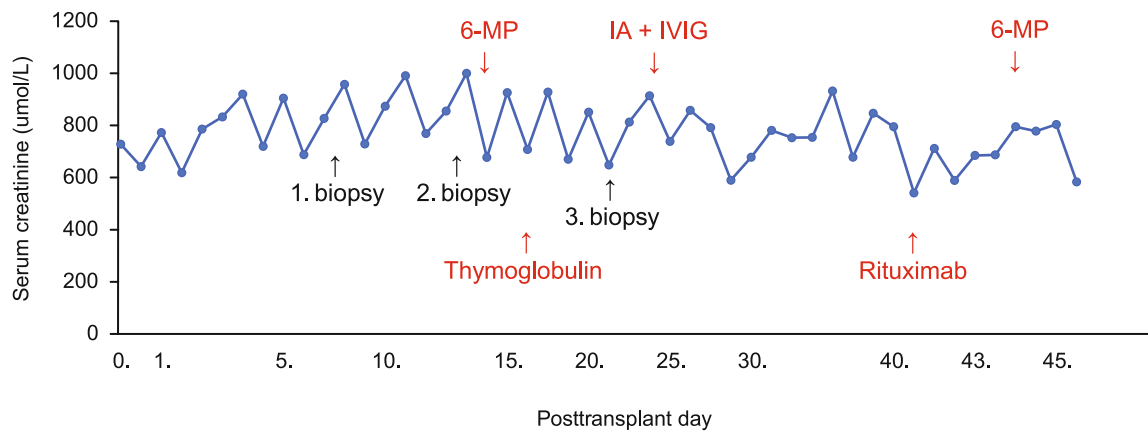
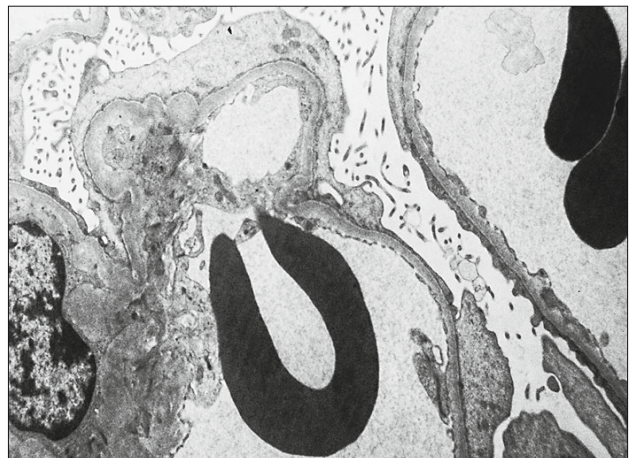


Fig. 4. Treatment in course of time and according to the results of renal biopsies.

of 6-methylprednisolone, 6-MP), followed by the treatment with cyclosporine. Due to a lack of response, it was replaced by cyclophosphamide because of nephrotoxicity, in both cases without much effect. The disease progressed to terminal renal failure with the need for haemodialysis treatment since March 2019. After completing the tests prescribed by the protocol, the patient was listed for kidney transplantation in July 2020. In March 2021, the patient was admitted to the Kidney Transplant Centre in Bratislava for primary kidney transplantation from a deceased donor. By this time, he purposefully lost almost 30 kg (BMI: 36,48 kg/m²), at the time of kidney transplantation his residual diuresis was 1500 ml/24 hours. After evaluation of immunological (specific antibodies against HLA antigens of the donor by Luminex method: negative; mismatch in HLA system: 011, compatibility index: 12, cold ischemia: 20 hours and 20 minutes) and non-immunological risk (acute kidney damage in the donor), antilymphocyte globulin was administered in induction in total dose of 550 mg (i.e. 4.8 mg/kg) according to the protocol for the prevention for acute rejection. The maintenance immunosuppression consisted of a combination of prednisolone, tacrolimus, and mycophenolic acid. The surgical procedure of kidney transplantation was performed without complications. Graft function did not recover, daily diuresis did not exceed 200 ml, the patient's condition required haemodialysis.

After excluding potential causes of graft dysfunction (urinary tract obstruction, renal artery thrombosis/stenosis, renal vein thrombosis, perirenal haemorrhage, macroscopic haematuria, urinary fistula, nephrotoxic tacrolimus level, bacterial urinary tract infection, cytomegalovirus infection, polyomavirus infection, donor-specific anti-HLA antibodies determined by the Luminex method), on post-transplantation day 9, the first biopsy of the transplanted kidney was performed with a normal histological findings (Fig. 1).

With continued targeted monitoring and provision of optimal conditions for restoration of graft function and continued dialysis treatment, anuria persisted; therefore, the second biopsy of the graft was performed on postoperative day 15 with a finding of

acute cell-mediated rejection with borderline changes (Fig. 2).

lymphocytes depicted in brown colour, magnification 200x (Source: Cytopathos LLC)

According to the protocol, treatment with boluses of 6-MP at a cumulative dose of 1000 mg was indicated, but with no effect, the condition was considered as cortico-resistant acute rejection and the treatment was changed to anti-thymocyte globulin at a dose of 375 mg (i.e., 3.3 mg/kg). Despite treatment with depletion antibody, graft failure with oligoanuria persisted. After excluding other causes (low/high tacrolimus level, urinary tract infection, CMV infection, BKV infection, urinary tract obstruction, renal blood supply disorder, donor-specific anti-HLA antibodies), a third biopsy was performed on postoperative day 23 (Fig. 3).

LLC)

In addition to graft failure, another indication for biopsy was the finding of massive proteinuria (25 g/l) in a small volume of urine at oligoanuria (up to 300 ml/24 h). The reason for examining proteinuria despite oligoanuria was worsening hypoalbuminemia from the end of the second week after transplantation despite fully restored oral intake, adequate healing of the surgical wound, and the absence of diarrhoea. In addition to light microscopy, specimens were also sent for immunohistochemistry and electron microscopy. Preliminary histological findings in light microscopy showed a persistent acute cell-mediated rejection with borderline changes. As a part of the differential diagnosis, it was necessary to distinguish whether the produced urine, including proteinuria, was from his native kidneys or from the transplanted one. Dynamic scintigraphy showed good perfusion of the graft, but impaired trans renal passage and stagnation of the radiopharmaceutical in the parenchyma without tubular secretion. Based on the above-mentioned information, we hypothesized that the significant protein loss was from the native kidneys, and it was related to the primary disease. Therefore, nephrectomy of the left native kidney was performed on the 30th day after KT, which showed a normal size in the sonographic image in contrast to the

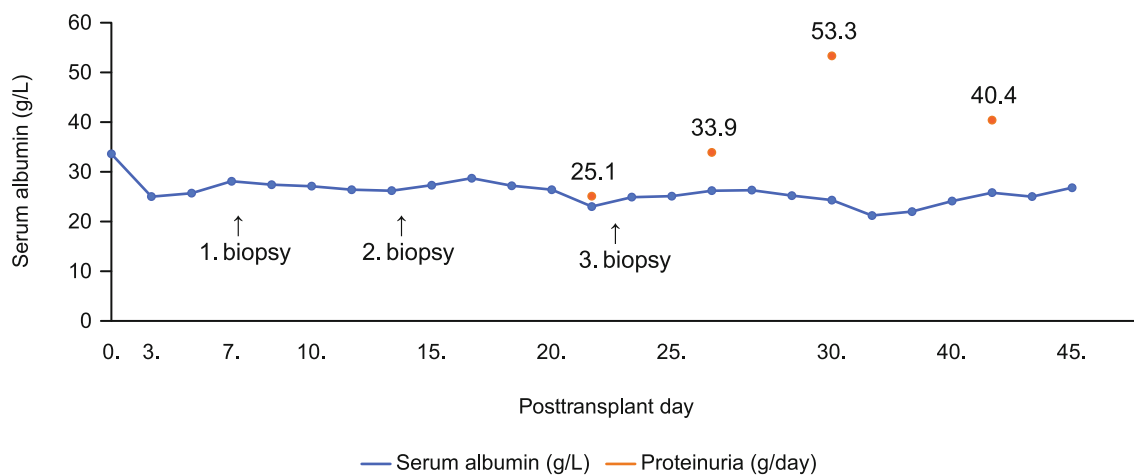


Fig. 5. Development of proteinuria in the time after kidney transplantation.

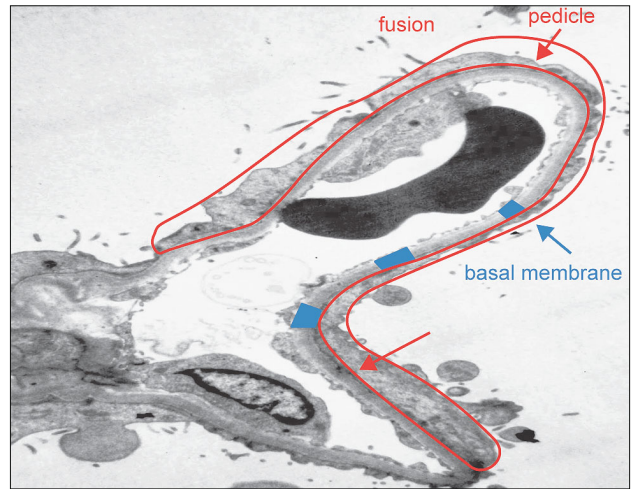
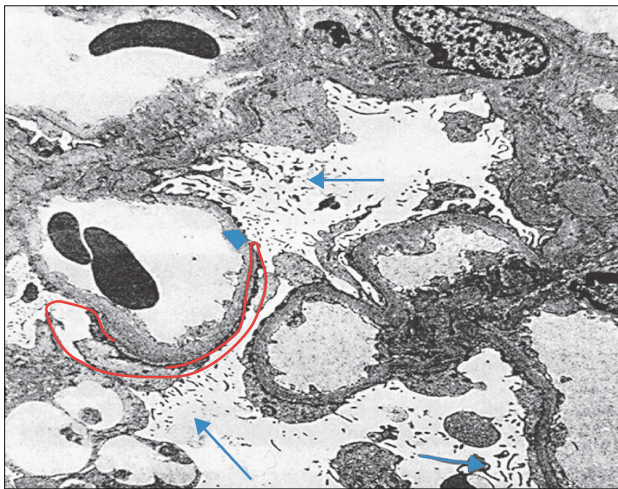


Fig. 6. Electron microscopy: Minimal glomerular changes in a transplanted kidney.

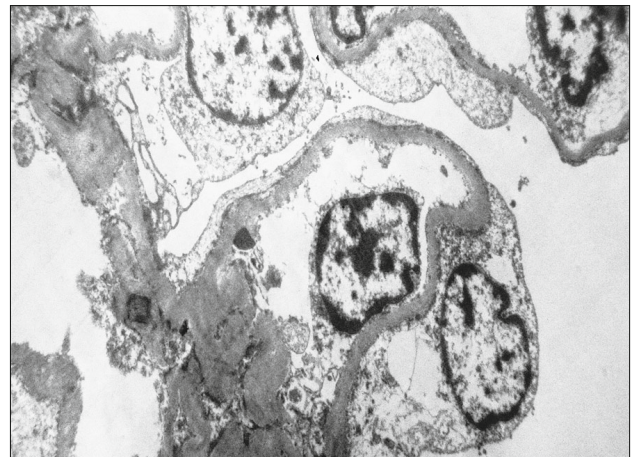
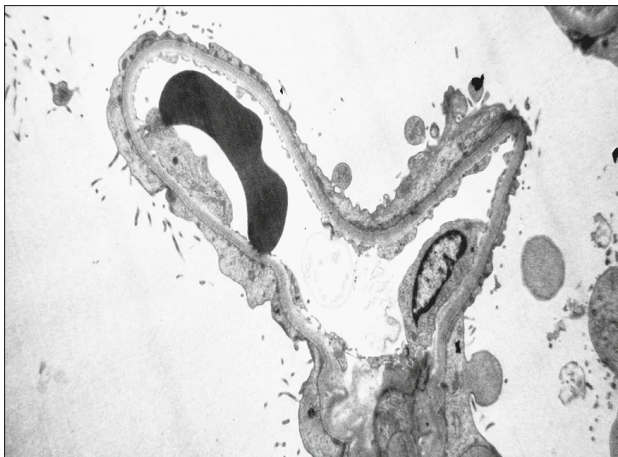


Fig. 7. Electron microscopy: FSGS in native kidney.

right smaller kidney. Subsequent electron microscopic histological examination of the biopsy specimen described *de novo* small glomerular abnormalities, and the potential for possible transition to FSGS was evaluated in correlation with the disease progression in the native kidney. Immunoabsorption (total of 5 treatments) and immunomodulatory therapy with administration of intravenous immunoglobulins (total of 100 g), biological therapy with anti-CD20 monoclonal antibody (rituximab) at a dose of 600 mg, and boluses of corticosteroids (6-MP at a dose of 2500 mg) were indicated immediately (Fig. 4).

Despite complex treatment, there was no recovery of graft function or decrease in proteinuria with persistent oligoanuria; hypoalbuminemia persisted with the need for supplementation with 20 % human albumin (Fig. 5).

In the control specimen from the 4th biopsy (postoperative day 43) examined in the EM, the finding of complete fusion of pedicel podocytes with villous transformation and vacuolization of their bodies was described (Fig. 6).

After some time, we received the result of electron microscopy evaluation of the left native kidney specimen with the finding of advanced sclerotherapy and atrophy of the renal cortex within the FSGS image (Fig. 7).

Due to persistent massive proteinuria, oligoanuria and exhausted therapeutic options, graft nephrectomy and gradual discontinuation of immunosuppressive therapy was indicated on day 60th after KT. High proteinuria reaching 31 g/l persisted in the oligoanuric patient (diuresis about 150 ml/24 h).

Conclusion

Recurrence of the primary disease represents one of the most common causes of graft failure during the first ten years after kidney transplantation. The risk of recurrence varies depending on the type of glomerulonephritis. Focal segmental glomerulosclerosis as the cause of terminal native kidney failure is associated with a high risk of recurrence in the transplanted kidney in

the first weeks after transplantation. The risk of recurrence after the primary kidney transplantation is 50 %. In the case report, we present a rapid recurrence of the disease. Recognition of recurrence was hampered by the primary graft failure with oligoanuria and unremarkable changes in the first two bioptic samples. It was only the unclear clinical course after transplantation and the worsening hypoalbuminemia that led to the examination of proteinuria despite the low daily urine output (significantly lower than the residual pre-transplant diuresis). The high volume of protein loss in urine was essential for further diagnostics and treatment which, however, did not lead to correction of the condition and development of graft function.

Hypothetically, it remains to be considered whether a specific intervention initiated immediately after kidney transplantation would be successful in reversing the adverse disease progression in the graft. In this context, the importance of being aware of the primary disease supported by renal biopsy should be emphasized. In the case of disease with a high potential for recurrence in the transplanted kidney, early diagnosis and targeted intervention are crucial.

A new experience related to the presented case report is the finding that clinically significant proteinuria leading to significant hypoproteinaemia with the need for albumin supplementation may also occur in oligoanuria. Therefore, in the case of focal segmental glomerulosclerosis as the reason of kidney failure of native kidneys, with a high potential for recurrence in the transplanted kidney, we recommend monitoring proteinuria despite oligoanuria and examining the biopsy specimen also by electron microscopy.

References

1. **KDIGO 2021** – Clinical practice guideline for the management of glomerular diseases. Practice guideline, 2021, (100) 4: supl. S1–S276. [https://www.kidney-international.org/article/S0085-2538\(21\)00562-7/fulltext](https://www.kidney-international.org/article/S0085-2538(21)00562-7/fulltext).
2. **Wai HL, Shingde M, Wong G.** Recurrent and de novo glomerulonephritis after kidney transplantation. *Front. Immunol* 2019; 10: 10.3389/fimmu.2019.01944.
3. **Hariharan S, Israni AK, Danovitch G.** Long-term survival after kidney transplantation. *N Engl J Med* 2021; 385: 729–743.
4. **Foroutan F, Friesen EL, Clark KE, Motaghi S et al.** Risk factors for 1-year graft loss after kidney transplantation. *CJASN* 2019; 14 (11): 1642–1650.
5. **Tesař V, Viklický O.** *Klinická nefrologie*. Grada, 2015: 99–106.
6. **Jan CJ, Chen A, Sun GH, Yu DS, Yen CY, Lin FY.** Recurrent minimal change disease post-allograft renal transplantation. *Transplant Proc* 2003; 35 (8): 2888–2890.
7. **Kang HG, Ha IS, Cheong HI.** Recurrence and treatment after renal transplantation in children with FSGS. *Biomed Res Int* 2016. <https://www.ncbi.nlm.nih.gov/pmc/articles/PMC4860214/>.
8. **Uffing A, Pérez-Sáez MJ, Mazzali M.** Recurrence of FSGS after kidney transplantation in adults. *CJASN* 2020; 15 (2): 247–256.
9. **Messina M, Gallo E, Mella A, Pagani F.** Update on the treatment of focal segmental glomerulosclerosis in renal transplantation. *World J Transplant* 2016; 24: 6 (1): 54–68. <https://www.ncbi.nlm.nih.gov/pmc/articles/PMC4801805/>.
10. **Kienzl-Wagner K, Rosales A, Scheidl S, Giner T.** Successful management of recurrent focal segmental glomerulosclerosis. *Am J Transplant* 2018; 18 (11): 2818–2822. <https://www.ncbi.nlm.nih.gov/pmc/articles/PMC6220932/>.

Received February 17, 2022.

Accepted March 14, 2022.