

The diagnostic contribution of magnetic resonance imaging in the detection of axillary metastasis after neoadjuvant chemotherapy

Yakup İRİAĞAÇ^{1*}, Kubilay KARABOYUN¹, Eyyüp ÇAVDAR¹, Okan AVCI¹, Tuğba İlkem Kurtoğlu ÖZÇAĞLAYAN², Meltem ÖZNUR³, Sibel Ozkan GURDAL⁴, Erdoğan Selçuk ŞEBER¹

¹Department of Medical Oncology, Faculty of Medicine, Tekirdag Namik Kemal University, Tekirdag, Turkey; ²Department of Radiology, Faculty of Medicine, Tekirdag Namik Kemal University, Tekirdag, Turkey; ³Department of Pathology, Faculty of Medicine, Tekirdag Namik Kemal University, Tekirdag, Turkey; ⁴Department of Surgical Oncology, Faculty of Medicine, Tekirdag Namik Kemal University, Tekirdag, Turkey

*Correspondence: yakup@dr.com; yiriagac@nku.edu.tr

Received January 27, 2022 / Accepted April 8, 2022

Sentinel lymph node dissection (SLND) is a reliable method that provides axillary staging in clinical node-negative (cN0) breast cancer patients before neoadjuvant chemotherapy (NACT). However, it is not a standard method on its own due to the high false-negative rates (FNR) reported in initially clinical node-positive patients (cN1-cN3). The contribution of magnetic resonance imaging (MRI) to SLND after chemotherapy is not well understood. In our study, we aimed to investigate the contribution of post-NACT MRI to SLND in breast cancer patients receiving NACT. Between January 2014 and December 2020, patients who had MRI images including the axilla after NACT and had axillary lymph nodes evaluation performed simultaneously with SLND were included in the study. MRI images of all patients were re-evaluated by 2 experienced clinicians. MRI and SLND results were analyzed to detect axillary lymph node metastasis. 117 patients were included in the study. The median age of the patients was 49 years. Before chemotherapy, 108 patients (92.3%) had tumor metastases in their axilla pathologically confirmed by tru-cut biopsy. Axillary downstage was obtained in 48.1% (n=52) of the patients after NACT. Of the 56 patients with axillary node positivity, 3 patients had no metastasis in the SLND evaluation (FNR=5.4%). The sensitivity of post-NACT MRI in detecting node positivity was 69.6%, the specificity was 90.2%, the positive predictive value (PPV) was 86.7% and the negative predictive value (NPV) was 76.4. SLND together with MRI predicted all node-positive patients (FNR=0%). In summary, SLND may not detect a group of patients with residual axillary lymph node metastases after NACT. We have shown that MRI can contribute to identifying these patients. If no metastases are detected by both methods (SLND and MRI), avoidance of axillary dissection may be an acceptable choice.

Key words: breast cancer; neoadjuvant chemotherapy; sentinel lymph node dissection; MRI; ALND

In patients with early-stage or locally advanced breast cancer, neoadjuvant chemotherapy (NACT) is a preferred treatment strategy for a potential reduction of the axillary stage, a higher chance of breast-conserving surgery, and assessment of an early *in vivo* response to systemic treatment [1].

Axillary lymph node dissection (ALND) is a surgical procedure used in breast cancer surgery to achieve regional control, prolong survival, and perform lymph node classification. However, this procedure is associated with short-term and long-term surgical complications; such as lymphedema, wound problems, nerve damage, and shoulder dysfunction in a significant number of patients [2, 3]. In addition, decreased quality of life is observed in patients who underwent ALND [4].

Until recently, ALND was used as a standard procedure during breast surgery in all patients receiving

NACT. However, after European SENTinel NeoAdjuvant (SENTINA) and American College of Surgeons Oncology Group (ACOSOG) Z1071 studies, the SLND procedure after NACT has become widely used, and axillary dissection requirement was abandoned for some patients [5, 6]. Yet, it is controversial to use only SLNB without ALND to evaluate axillary metastasis after NACT. In previous studies, a false-negative rate (FNR) of 8–25% was observed when SLND is used to detect axillary metastasis after NACT [7–9]. Therefore, in addition to SLND, various methods such as nodal marking or radiological imaging are used to avoid axillary dissection [10–13].

Breast magnetic resonance imaging (MRI) is an imaging modality that is widely used to detect occult breast cancer and evaluate NACT response, as well as the evaluation of high-risk patients [14–16]. Studies have shown that post-

NACT MRI is the most sensitive imaging method to evaluate the response in breast tissue [17]. On the other hand, reports are showing that MRI is useful, to various degrees, for the evaluation of axillary lymph nodes [18–20]. However, the contribution of post-NACT MRI in patients undergoing SLNB is not well understood and only a few studies are available, evaluating SLND, MRI, and ALND together.

In this study, we aim to investigate the importance of post-NACT MRI in the evaluation of axillary lymph nodes in breast cancer patients treated with neoadjuvant chemotherapy and to investigate its contribution to SLNB.

Patients and methods

Patients. In this study, the data of patients, aged 18 years and over, who applied to Tekirdag Namik Kemal University between 01 January 2014 and 30 December 2020, were analyzed. The study included patients who had MRI images of the axilla after NACT and had at least 3 negative sentinel lymph nodes removed or one positive lymph node found by concurrent ALND. Male breast cancer patients were excluded from the study. All patients had confirmed axillary biopsies before NACT (Figure 1).

This research conforms with the provisions of the 1995 Declaration of Helsinki. All patients provided informed consent and the Local Ethical Committee of Tekirdag Namik Kemal University gave formal approval to this retrospective study (approval no. 2021.128.05.01 on 27th May 2021).

Sentinel lymph node procedure and pathological evaluations. SLN surgery is a procedure used by surgeons to find a metastatic tumor in the lymphatic drainage pathway from the primary tumor in the breast to the axillary lymph node region. The Blue dye method was used to determine sentinel lymph nodes. During the operation, the lymph channels in which the blue dye was observed were trailed and the sentinel lymph nodes were evaluated by the surgeon and dissected as sentinel nodes. The TNM Classification of Malignant Tumors 8th edition was used for pathological staging. Pathological micrometastases (larger than 0.2 mm, but none larger than 2.0 mm) were evaluated as pN1mi and defined as pathological lymph node metastasis (node-positive).

Radiological evaluation. MRI images of all patients were re-evaluated by 2 experienced clinicians, a radiologist, and a breast surgeon, with pathology data censored. An increase in cortical thickness in the lymph node, the loss of fatty hilum,

round shape, and a ratio of the long axis of the lymph node to the short axis being less than 2, were considered significant for axillary lymph node metastasis [21–22]. The cases were evaluated in two groups; “positive” cases with lymph node metastasis of breast cancer defined radiologically and “negative” cases without radiological metastasis.

A 1.5-T whole-body MRI scanner (BRIVO MR 355, GE™ Healthcare™, USA) was used for whole breast and axillary imaging. In contrast-enhanced MRI scans, after 6 saline infusions, gadoteric acid was administered at a dose of 0.1 mmol/kg and a rate of 2 ml/sec. The first image was obtained 25 seconds after the contrast injection.

Study endpoint. In the study, we aimed to determine the FNR in patients who underwent intraoperative SLNB after NACT and to investigate the contributions of post-NACT MRI in these patients.

Statistical analysis. The FNR for SLND was calculated by dividing the number of patients with negative sentinel lymph nodes by the number of those with residual disease in the axillary lymph nodes. Basic statistical analyzes were used for the accuracy of MRI as a diagnostic test. SPSS Statistic software 24 (SPSS Inc., Chicago, III) was used for basic statistical analysis (Table 1).

Results

In our study, 117 female breast cancer patients who had completed neoadjuvant chemotherapy (NACT) and subsequently had been operated on were evaluated. The median age of the patients was 49 (min: 24 max: 74). The most common histological type was invasive ductal carcinoma (n=93, 79.5%) and 58 of all patients (49.6%) had hormone receptor (HR) positive/Her-2 negative breast cancer. Before chemotherapy, 108 patients (92.3%) had tumor metastases in the axilla that were pathologically confirmed by tru-cut biopsy, 80 patients (68.4%) had a single focal tumor, 28

Table 1. Statistical methods used for determining the statistical accuracy of MRI.

	Node positive	Node negative
MRI positive	True-positive (TP)	False-positive (FP)
MRI negative	False-negative (FN)	True-negative (TN)

Notes: sensitivity: $TP/(TP+FN)$; specificity: $TN/(TN+FP)$; positive predictive value (PPV): $TP/(TP+FP)$; negative predictive value (NPV): $TN/(TN+FN)$

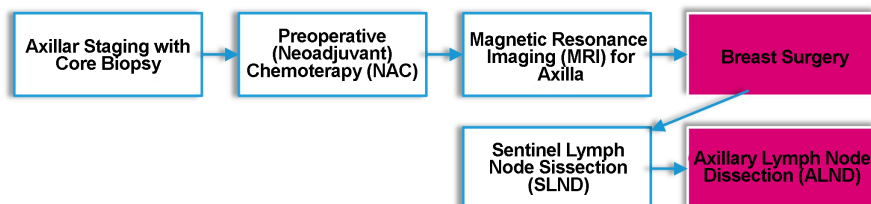


Figure 1. Chronological order of the procedures performed on patients included in the study.

Table 2. Patient's characteristics.

Characteristic	n=117	%
Age	59	50.4
<50	58	49.6
≥50		
Molecular subtype		
HR Positive, Her-2 Negative	58	49.6
HR Positive, Her-2 Positive	30	25.6
HR Negative, Her-2 Positive	9	7.7
Triple Negative	20	17.1
Histologic type		
Ductal	93	79.5
Others	24	20.5
ER		
Negative	29	24.8
Positive	88	75.2
PgR		
Negative	41	35
Positive	76	65
Her-2		
Negative	78	66.7
Positive	39	33.3
Ki-67		
<18	30	25.6
≥18	87	74.4
Grade		
Grade 1	5	4.3
Grade 2	82	70.1
Grade 3	30	25.6
Clinical T stage		
T1	31	26.5
T2	78	66.7
T3-T4	8	6.8
Location		
Left	64	54.7
Right	53	45.3
Number of tumor foci		
Unifocal	80	68.4
Multifocal	28	23.9
Multicentric	9	7.7
Metastasis in axillary biopsy before NACT		
Negative	9	7.7
Positive	108	92.3

Abbreviations: MRI-magnetic resonance imaging; SLND-sentinel lymph node dissection; NACT-neoadjuvant chemotherapy

patients had a multifocal tumor (23.3%), and 9 patients (7.7%) had a multicentric tumor (Table 2).

According to the pathological evaluation of patients who underwent lymph node dissection after NACT, 56 patients (47.9%) had residual lymph node metastases (ypN1-3) and 61 patients (52.1%) did not have lymph node metastases (ypN0) (Figure 2). Axillary metastases were cleared in 48.1% (n=52) of 108 patients who were initially node-positive and axillary downstage was obtained.

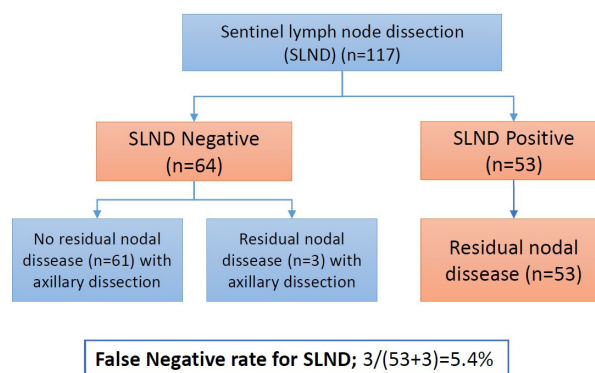


Figure 2. Evaluation of sentinel lymph node dissection and axillary lymph node dissection after neoadjuvant chemotherapy.

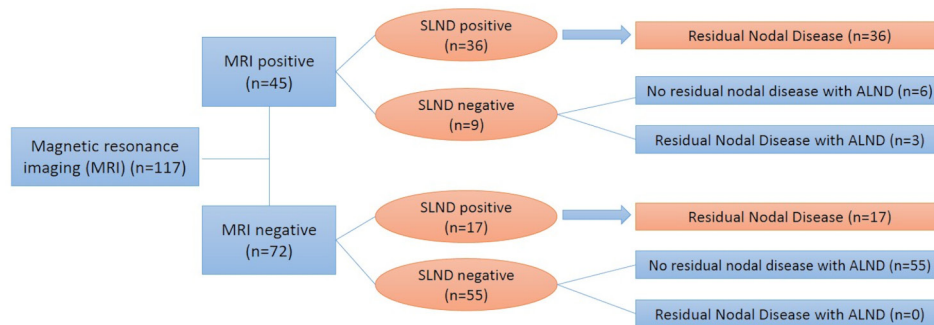
Of the 56 patients with residual lymph node metastasis (ypN1-3) after NACT; it was evaluated as metastasis by MRI in 39 (69.6%) patients (true-positive) and no metastasis was observed in MRI (false-negative) in 17 patients (30.4%). Of 61 patients without lymph node metastasis (ypN0); 55 (90.2%) patients were evaluated as having no tumor (true-negative) on MRI and the metastatic-like image was obtained on MRI in 6 (9.8%) patients (false-positive). When the pathological evaluation was referred to as the gold standard diagnostic test, the sensitivity of MRI in detecting node positivity was 69.6%, the specificity was 90.2%, the positive predictive value (PPV) was 86.7%, and the negative predictive value (NPV) was 76.4 (Figure 3).

There were 64 patients without tumor metastasis by SLND, 61 patients without lymph node metastasis in ALND, and metastasis with ALND was reported in 3 patients. The FNR for SLND was calculated as 5.4% (Figure 2). When SLND and MRI were evaluated together after chemotherapy, the FNR rate was found to be 0% (Figure 3).

Discussion

In this study, the sensitivity of post-NACT MRI in detecting residual node metastasis was 69.6%, the specificity was 90.2%, the PPV was 86.7% and the NPV was 76.4%. There were 56 patients with axillary metastases, but no lymph node metastases were detected in 3 patients with SLND (FNR: 5.4%) and in 17 patients with MRI (FNR: 30.3%). When MRI and SLND were applied together as a diagnostic test, it correctly detected all patients without axillary metastases (FNR: 0%). In conclusion, with this study, SLND alone may be insufficient to detect patients with residual axillary metastases after NACT, and we have shown that post-NACT MRI will contribute to detecting these patients.

In clinical node-negative breast cancer (cN0) patients at diagnosis, avoiding axillary dissection after NACT is a reliable and preferred method of SLND. FNR with SLND in cN0 patients is approximately 6% (95% CI: 3–8%) [23].



For MRI; sensitivity=69.6%, specificity=90.2%, PPV=86.7%, NPV=76.4%

False negative rate for MRI; $17/(36+3+17) = 30.3\%$

False negative rate for MRI with SLND; $0/(36+3+17) = 0\%$

(PPV:positive predictive value, NPV:negative predictive value, SLND:Sentinel lymph node dissection)

Figure 3. Diagnostic analyzes of magnetic resonance imaging and sentinel lymph node dissection to identify axillary metastases.

Avoiding axillary dissection in these patients is shown to be safe in the long term. In the study by Nogi et al., after a 51-months follow-up of 183 patients with cN0 at baseline, none of the patients developed axillary lymph node recurrence after NACT [24]. Similar results were seen in the GANEA 2 study, and it is safe to avoid axillary dissection after SLND in patients who are clinically node-negative at the time of diagnosis [25].

SLND is controversial in evaluating axillary response after NACT in initially node-positive patients. A high FNR with SLND has been reported as a result of fibrosis developing in lymphatic channels after NACT as well as heterogeneous chemotherapy responses of lymph nodes. Among prospective randomized studies, FNR was found to be 12.6% in ACOSOG Z1071, 14.2% in SENTINA, and 11.9% in GANEA [2, 5, 6, 25]. 2019 St. Gallen conference panel concluded that SLN surgery may be appropriate in patients with clinically positive axilla before treatment and negative after NACT. However, in such cases, the panel stipulated that three or more SLNs must be identified and all negative or a pre-NACT labeled axillary lymph nodes proved to be negative. However, patients presenting with cN2 disease are excluded from SLN and must undergo complete axillary dissection and receive regional nodal irradiation regardless of response to NACT [7]. In our study, among the patients with negative SLN biopsy, tumor metastasis was detected by ALND in 3 patients and the FNR was calculated as 5.4%. We think that the section differences in pathological procedures of SLN and the diagnosis of an experienced pathologist in breast tumors contributed to the fact that our FNR rate was lower than the literature [26, 27].

The contribution of MRI after chemotherapy in the evaluation of axillary lymph nodes after NACT is not known enough. In the study by Javid et al., MRI sensitivity was 92% and specificity 89% in the detection of pathological axillary lymph node disease after NACT [28]. In another study by Ha

et al., this rate was reported as 57.33% and 72.09%, respectively [18]. In our study, the sensitivity of MRI in detecting node positivity was 69.60%, the specificity was 90.20%, PPV 86.70%, and NPV 76.40%. While FNR was 5.40% with SLND, there were no patients with FNR (0%) when evaluated together with MRI after NACT. These results showed that MRI alone is a low-sensitivity diagnostic test, but when added to SLND, it contributes to identifying patients who will have FNR. The most important limitation of our study was its retrospective design. What made our study strong was that all radiological, pathological, and surgical procedures were carried out in a single-center where more than 100 breast surgeries were performed annually.

In conclusion, a group of patients without tumor metastasis as a result of SLND after NACT may have metastasis in the axillary lymph node, and post-NACT MRI contributes to SLND in detecting axillary metastases in these patients. If no metastases are detected by both methods (SLND and MRI), avoidance of axillary dissection may be an acceptable choice. In future studies, it is necessary to investigate the contribution of MRI to the sentinel lymph node, together with methods such as FNR-reducing clip placement, wireless non-radioactive localizers, or tattooing [11–13].

References

- [1] SCHOTT AF, HAYES DF. Defining the Benefits of Neoadjuvant Chemotherapy for Breast Cancer. *J Clin Oncol* 2012; 30: 1747–1749. <https://doi.org/10.1200/JCO.2011.41.3161>
- [2] FLEISSIG A, FALLOWFIELD LJ, LANGRIDGE CI, LANGRIDGE CI, JOHNSON L et al. Post-operative arm morbidity and quality of life. Results of the ALMANAC randomised trial comparing sentinel node biopsy with standard axillary treatment in the management of patients with early breast cancer. *Breast Cancer Res Treat* 2006; 95: 279–293. <https://doi.org/10.1007/s10549-005-9025-7>

- [3] LUCCI A, MCCALL LM, BEITSCH PD, WHITWORTH PW, REINTGEN DS et al. Surgical complications associated with sentinel lymph node dissection (SLND) plus axillary lymph node dissection compared with SLND alone in the American College of Surgeons Oncology Group Trial Z0011. *J Clin Oncol* 2007; 25: 3657–3663. <https://doi.org/10.1200/JCO.2006.07.4062>
- [4] VELANOVICH V, SZYMANSKI W. Quality of life of breast cancer patients with lymphedema. *Am J Surg* 1999; 177: 184–188. [https://doi.org/10.1016/s0002-9610\(99\)00008-2](https://doi.org/10.1016/s0002-9610(99)00008-2)
- [5] KUEHN T, BAUERFEIND I, FEHM T, FLEIGE B, HAUSCHILD M et al. Sentinel-lymph-node biopsy in patients with breast cancer before and after neoadjuvant chemotherapy (SENTINA): a prospective, multicentre cohort study. *Lancet Oncol* 2013; 14: 609–618. [https://doi.org/10.1016/S1470-2045\(13\)70166-9](https://doi.org/10.1016/S1470-2045(13)70166-9)
- [6] BOUGHEY JC, SUMAN VJ, MITTENDORF EA, AHRENDT GM, WILKE LG et al. Sentinel lymph node surgery after neoadjuvant chemotherapy in patients with node-positive breast cancer: the ACOSOG Z1071 (Alliance) clinical trial. *JAMA* 2013; 310: 1455–1461. <https://doi.org/10.1001/jama.2013.278932>
- [7] BOILEAU JE, POIRIER B, BASIK M, HOLLOWAY CMB, GABOURY L et al. Sentinel node biopsy after neoadjuvant chemotherapy in biopsy-proven node-positive breast cancer: the SN FNAC study. *J Clin Oncol* 2015; 33: 258–264. <https://doi.org/10.1200/JCO.2014.55.7827>
- [8] TAKAHASHI M, JINNO H, HAYASHIDA T, SAKATA M, ASAKURA K et al. Correlation between clinical nodal status and sentinel lymph node biopsy false negative rate after neoadjuvant chemotherapy. *World J Surg* 2012; 36: 2847–2852. <https://doi.org/10.1007/s00268-012-1704-z>
- [9] ALVARADO R, YI M, LE-PETROSS H, GILCREASE M, MITTENDORF EA et al. The role for sentinel lymph node dissection after neoadjuvant chemotherapy in patients who present with node-positive breast cancer. *Ann Surg Oncol* 2012; 19: 3177–3184. <https://doi.org/10.1245/s10434-012-2484-2>
- [10] CORSO G, DE SCALZI AM, VICINI E, MORIGI C, VERONESI P et al. Sentinel lymph node biopsy management after neoadjuvant treatment for breast cancer care. *Future Oncol* 2018; 14: 1423–1426. <https://doi.org/10.2217/fon-2018-0132>
- [11] SISO C, DE TORRES J, ESGUEVA-COLMENAREJO A, ESPINOSA-BRAVO M, RUS N et al. Intraoperative ultrasound-guided excision of axillary clip in patients with node-positive breast cancer treated with neoadjuvant therapy (ILINA trial). *Ann Surg Oncol* 2018; 25: 784–791. <https://doi.org/10.1245/s10434-017-6270-z>
- [12] LAWS A, DILLON K, KELLY BN, KANTOR O, HUGHES KS et al. Node-positive patients treated with neoadjuvant chemotherapy can be spared axillary lymph node dissection with wireless non-radioactive localizers. *Ann Surg Oncol* 2020; 27: 4819–4827. <https://doi.org/10.1245/s10434-020-08902-y>
- [13] PATEL R, MACKERRICHER W, TSAI J, CHOY N, LIPSON J et al. Pretreatment tattoo marking of suspicious axillary lymph nodes: reliability and correlation with sentinel lymph node. *Ann Surg Oncol* 2019; 26: 2452–2458. <https://doi.org/10.1245/s10434-019-07419-3>
- [14] GARETH ED, NISHA K, YIT L, GADDE S, HURLEY E et al. MRI breast screening in high-risk women: cancer detection and survival analysis. *Breast Cancer Res Treat* 2014; 145: 663–672. <https://doi.org/10.1007/s10549-014-2931-9>
- [15] KIM H, PARK W, KIM SS, AHN SJ, KIM YB et al. Outcome of breast-conserving treatment for axillary lymph node metastasis from occult breast cancer with negative breast MRI. *Breast* 2020; 49: 63–69. <https://doi.org/10.1016/j.breast.2019.10.017>
- [16] BANSAL GJ, PURCHASE D, WRAY M. Routine use of both mammography and MRI surveillance in patients with previous ‘mammogram occult’ breast cancer: experience from a tertiary centre. *Postgrad Med J* 2022; 98: 18–23. <https://doi.org/10.1136/postgradmedj-2020-138571>
- [17] CHEN JH, BAHRI S, MEHTA RS, KUZUCAN A, YU HJ et al. Breast cancer: evaluation of response to neoadjuvant chemotherapy with 3.0-T MR imaging. *Radiology* 2011; 261: 735–743. <https://doi.org/10.1148/radiol.11110814>
- [18] HA SM, CHA JH, KIM HH, SHIN HJ, CHAE EY et al. Diagnostic performance of breast ultrasonography and MRI in the prediction of lymph node status after neoadjuvant chemotherapy for breast cancer. *Acta radiol* 2017; 58: 1198–1205. <https://doi.org/10.1177/0284185117690421>
- [19] AL-HATTALI S, VINNICOMBE SJ, GOWDH NM, EVANS A, ARMSTRONG S et al. Breast MRI and tumour biology predict axillary lymph node response to neoadjuvant chemotherapy for breast cancer. *Cancer Imaging* 2019; 19: 91. <https://doi.org/10.1186/s40644-019-0279-4>
- [20] WEBER JJ, JOCHELSON MS, EATON A, ZABOR EC, BARRIO AV et al. MRI and prediction of pathologic complete response in the breast and axilla after neoadjuvant chemotherapy for breast cancer. *J Am Coll Surg* 2017; 225: 740–746. <https://doi.org/10.1016/j.jamcollsurg.2017.08.027>
- [21] MARINO MA, AVENDANO D, ZAPATA P, RIEDL CC, PINKER K. Lymph node imaging in patients with primary breast cancer: concurrent diagnostic tools. *Oncologist* 2020; 25: e231–e242. <https://doi.org/10.1634/theoncologist.2019-0427>
- [22] BALTZER PAT, DIETZEL M, BURMEISTER HP, ZOUBI R, GAJDA M et al. Application of MR mammography beyond local staging: is there a potential to accurately assess axillary lymph nodes? Evaluation of an extended protocol in an initial prospective study. *Am J Roentgenol* 2011; 196: W641–W647. <https://doi.org/10.2214/AJR.10.4889>
- [23] GENG C, CHEN X, PAN X, LI J. The feasibility and accuracy of sentinel lymph node biopsy in initially clinically node-negative breast cancer after neoadjuvant chemotherapy: a systematic review and meta-analysis. *PLoS One* 2016; 11: e0162605. <https://doi.org/10.1371/journal.pone.0162605>
- [24] NOGI H, UCHIDA K, MIMOTO R, KAMIO M, SHIOYA H et al. Long-Term Follow-Up of Node-Negative Breast Cancer Patients Evaluated via Sentinel Node Biopsy After Neoadjuvant Chemotherapy. *Clin Breast Cancer* 2017; 17: 644–649. <https://doi.org/10.1016/j.clbc.2017.05.002>

- [25] CLASSE JM, LOAEC C, GIMBERGUES P, ALRAN S, TUNON DE LARA C et al. Sentinel lymph node biopsy without axillary lymphadenectomy after neoadjuvant chemotherapy is accurate and safe for selected patients: the GANEA 2 study. *Breast Cancer Res Treat* 2019; 173: 343–352. <https://doi.org/10.1007/s10549-018-5004-7>
- [26] WEAVER DL. Pathology evaluation of sentinel lymph nodes in breast cancer: protocol recommendations and rationale. *Mod Pathol* 2010; 23: S26–S32. <https://doi.org/10.1038/modpathol.2010.36>
- [27] WEAVER DL, LE UP, DUPUIS SL, WEAVER KAE, HARLOW SP et al. Metastasis detection in sentinel lymph nodes: comparison of a limited widely spaced (NSABP protocol B-32) and a comprehensive narrowly spaced paraffin block sectioning strategy. *Am J Surg Pathol* 2009; 33: 1583. <https://doi.org/10.1097/PAS.0b013e3181b274e7>
- [28] JAVID S, SEGARA D, LOTFI P, RAZA S, GOLSHAN M. Can breast MRI predict axillary lymph node metastasis in women undergoing neoadjuvant chemotherapy. *Ann Surg Oncol* 2010; 17: 1841–1846. <https://doi.org/10.1245/s10434-010-0934-2>