

EXPERIMENTAL STUDY

Beneficial effects of vitamin E on radioiodine induced gastrointestinal damage: an experimental and pathomorphological study

Yumusak N¹, Sadic M², Akbulut A², Aydinbelge FN², Koca G², Korkmaz M²

Department of Pathology, Faculty of Veterinary Medicine, University of Harran, Sanliurfa, Turkey.

nihatyumusak@harran.edu.tr

ABSTRACT

OBJECTIVES: The aim of the present study was to investigate the radioprotective effect of vitamin E in the prevention of radioiodine (RAI) induced gastrointestinal damage.

METHOD: Twenty-four rats were randomly divided into three groups as follows: Group-1 was untreated control group, Group-2 was orally administered single dose of 111 MBq RAI, and Group-3 was orally administered 111 MBq RAI and 1 mL of oral vitamin E. Vitamin E was started two days before RAI administration and was continued for five days once daily after RAI. Pathomorphological parameters of gastrointestinal tissues (stomach, small intestines and bowels) were measured using Hematoxylin-Eosin and Masson's trichrome staining.

RESULTS: Varying degrees of inflammation, edema, ulcer, mucosal degeneration, necrosis and fibrosis were seen in the stomach, small intestine and bowel tissues of the rats in both study groups and not in the control group. The differences were statistically significant between these groups for all parameters ($p < 0.05$). The histopathological damage in the vitamin E treated group was significantly less than the damage in the RAI only group ($p < 0.05$ for all pathomorphological parameters).

CONCLUSION: The results of this study showed that vitamin E has a radioprotective property with antiinflammatory and antifibrotic effects protecting against gastrointestinal damage caused by radioiodine (Tab. 3, Fig. 3, Ref. 26). Text in PDF www.elis.sk.

KEY WORDS: vitamin E, radioiodine, radiation, gastrointestinal tract, pathomorphology.

Introduction

Radioiodine (RAI) has been one of the important components in the treatment of hyperthyroidism and differentiated thyroid carcinomas since the 1940s. RAI treatment is applied to prevent potential metastases and recurrences after total thyroidectomy for thyroid cancer (1). RAI is a radioactive isotope and emits high beta and gamma rays, which destroy tumor cells by causing radiation in thyroid cancer cells where they are accumulated. Therefore, it is used successfully for the prevention of undetected tumor metastases (2). Orally administered RAI is absorbed by the stomach and intestines, distributed in the blood as an extracellular ion, and trapped by the thyroid thereafter. The transition mechanism of RAI in the stomach and intestines have not yet been fully explained (3). The most common opinion is that it is NIS-mediated transition. NIS is a trans-membrane protein, which immunohistochemical studies have shown to be strongly expressed on the apical surfaces

of gastrointestinal epithelial cells of RAI-administered rats. This shows that NIS has a role in the absorption of radioiodine from the stomach and intestines (4).

Gastrointestinal clinical side effects such as xerostomia, nausea, gastralgia, dacryostenosis, enteritis, and changes in taste and vomiting may be seen during the 2–48 hours following therapy despite the successful therapeutic effects of RAI (5). These gastrointestinal findings are attributed to ionizing radiation increasing the release of free oxygen radicals (e.g. lipid peroxidases, hydrogen peroxide and hydroxyl radical) and oxidative stress induced tissue damage (6). Increased numbers of tissue free radicals impair the oxidant/antioxidant balance and trigger genetic destruction, mutation, cellular proliferation, apoptosis and inflammation through effects on the cell membrane, organelles and DNA (7). Many studies have reported positive outcomes of antioxidant supplements such as lycopene, vitamin D, Co-Q and melatonin for the prevention of oxidative stress-induced tissue damage which develops due to radioiodine (8, 9).

Vitamin E is the most important lipid-soluble antioxidant and it protects membranes from oxidation by reacting with lipid radicals which develop from the lipid peroxidation chain reaction (10). Vitamin E is absorbed through passive diffusion by intestinal enterocytes. It is accumulated in microsomal membrane, endoplasmic reticulum, the Golgi apparatus, lysosomal and perox-

¹Department of Pathology, Faculty of Veterinary Medicine, University of Harran, Sanliurfa, Turkey, and ²Department of Nuclear Medicine, University of Health Sciences, Ankara Training and Research Hospital, Ankara, Turkey

Address for correspondence: N. Yumusak, DVM, University of Harran, Faculty of Veterinary Medicine, Eyyubiye, 63100 Sanliurfa, Turkey.
Phone: +90.414.3183899, Fax: +90.414.3183922

ysmal membranes. A great part of vitamin E is incorporated into chylomicrons in its free form at the Golgi apparatus level before being released into lymphatic circulation (11). Vitamin E, which is non-toxic, has been used in the treatment of diseases such as cataract, cancer and cardiovascular diseases (12). Recent studies have revealed that vitamin E has a radio-protective effect against lacrimal and salivary gland damage which occurs in patients receiving RAI treatment (13, 14, 15).

The aim of this study was to investigate the protective effect of vitamin E, which is non-toxic, easily available and easily absorbed from the intestines, against radioiodine-related early gastrointestinal damage.

Material and methods

Animals

All stages of the study were conducted in the Animal Unit Laboratory after national and Local Ethics Committee approval had been obtained for breeding and using laboratory animals and in accordance with the principles of the 1964 Declaration of Helsinki for laboratory animals.

A total of 24 female Wistar albino rats, aged 3–5 months, and each weighing 250–300 g, were used in the study. The rats were acclimatized for one week before the experiment and were housed under standard laboratory conditions (21 ± 2 °C room temperature and 65–70 % relative humidity) with a 12-h light/dark cycle in polypropylene cages separated by lead to protect against exposure to radioisotopes. Disposable absorbent cloths were placed under sterile paddy husks to avoid contamination from radioactive urine. During the study, the experimental rats were fed with standard chow and water ad libitum.

Tab. 1. The statistically significant values of the histopathological parameters detected in the stomach tissues of the groups.

Histopathological Parameters	Group 1	Group 2	Group 3	p
Edema	0[0-0]‡	1[0-1]	0[0-0]‡	0.011*
Inflammation	0[0-0]‡	1[1-2]	0[0-1]‡	0.001*
Fibrosis	0[0-0]‡	1.5[1-2]	0[0-1]‡	0.001*
Mucosal Erosion	0[0-0]‡	1[1-2]	0[0-0]‡	0.001*
Mucosal Degeneration	0[0-0]‡	1[1-1]	0[0-0]‡	0.001*
Ulcer	0[0-0]‡	0[0-1]	0[0-0]‡	0.037*
Necrosis	0[0-0]‡	1[0.5-1]	0[0-0]‡	0.002*

†Median [25–75 %], *Significant at 0.05 level; Kruskal–Wallis test, ‡ Significant versus RAI; All pairwise multiple comparison test.

Experimental design

The animals were randomly divided into three groups (n = 8/ per group). Group1 (control) was given no treatment. In Group 2 (RAI group), radioiodine (Mon-Iyot-131, Eczacibasi) was applied at 111 MBq (3 mCi/kg) via an orogastric catheter. Group-3 (RAI+Vitamin E group) was given 3 mCi/kg I-131 RAI via gastric gavage and 1mL Vitamin E [(100 mg/kg body weight) (Evigen)]. Vitamin E was started 2 days before the RAI treatment and was continued for 5 days after RAI treatment. At 24 hours after the last dosage of Vitamin E, the animals were anesthetized with 50 mg/kg, intra-peritoneal propofol and then sacrificed. The gastrointestinal system organs, stomach (S), small intestine (duodenum (D), jejunum (J) and ileum (I)) and bowels (cecum (Ce), colon (C) and rectum (R)) were removed with standard methods for histomorphological examination.

Histopathological examination

The removed tissues were immediately fixed in 10 % neutral buffered formalin (pH 7.2–7.4) and taken for routine pathology

Tab. 2. Histopathological parameters in the small intestinal tract.

Histopathological Parameters	Group 1			Group 2			Group 3			P
	Duodenum	Jejunum	Ileum	Duodenum	Jejunum	Ileum	Duodenum	Jejunum	Ileum	
Edema	0[0-0]‡	0[0-0]‡	1[1-1.5]‡	1[0.5-2]	1[1-1]	1[1-1.5]	0[0-0.5]‡	0[0-0.5]‡	0[0-0.5]‡	D=0.005* J=0.004* I=0.001*
Inflammation	0[0-0]‡	0[0-0]‡	1[1-1.5]‡	2[1-2]	2[2-2]	2[2-2]	0[0-1]‡	0[0-1]‡	0[0-1]‡	D=0.001* J=0.001* I=0.001*
Fibrosis	0[0-0]‡	0[0-0]‡	0[0-0]‡	2[1-2]	1[1-1]	1[1-1.5]	0[0-0.5]‡	0[0-0.5]‡	0[0-0.5]‡	D=0.001* J=0.001* I=0.001*
Mucosal Erosion	0[0-0]‡	0[0-0]‡	0[0-0]‡	1[1-1]	1[1-1]	1[1-1]	0[0-0]‡	0[0-0]‡	0[0-0.5]‡	D=0.001* J=0.001* I=0.004*
Mucosal Degeneration	0[0-0]‡	0[0-0]‡	0[0-0]‡	1[0-1.5]	1[0.5-1]	1[0.5-1.5]	0[0-0.5]	0[0-0.5]	0[0-0.5]‡	D=0.021* J=0.021* I=0.005*
Ulcer	0[0-0]‡	0[0-0]‡	0[0-0]‡	1[0-1]	0.5[0-1]	0.5[0-1]	0[0-0]‡	0[0-0]‡	0[0-0]‡	D=0.001* J=0.001* I=0.017*
Necrosis	0[0-0]‡	0[0-0]‡	0[0-0]‡	1[1-1]	1[1-1]	1[1-1]	0[0-0]‡	0[0-0]‡	0[0-0]‡	D=0.001* J=0.001* I=0.001*

†Median [25–75 %], *Significant at 0.05 level; Kruskal–Wallis test, ‡ Significant versus RAI; All pairwise multiple comparison test.

follow-up as described by Luna et al (16) The tissues, which were dehydrated in increasing degrees of alcohol (50 %, 75 %, 96 % and 100 %) in an automated tissue follow-up device, were applied with xylol to obtain transparency and embedded in paraffin blocks. Four-micron thickness sections were taken with a Leica RM 2125 RT; the first three sections and every tenth section were transferred to glass lams. The preparations were passed through a series of alcohol and xylol and stained with Hematoxylin Eosin (HE) and Masson's trichrome stains. Pathological lesions in the preparations of the stomach, small intestines and bowel of each rat were examined with regard to edema, ulcer, erosion, mucosal degeneration, necrosis, inflammation and fibrosis in randomly determined 10 different fields at x200 magnification using a high-resolution light microscope (Olympus BX-50, DP53 camera, Tokyo, Japan) by a pathologist blinded to the groups. These findings were evaluated as absent, focal, lobular or diffuse at x200 magnification according to the previously described grading systems and scored as 0 (none), + (mild), ++ (moderate), +++ (severe) (17). The differences between groups were compared statistically.

Statistical analysis

The normality distribution of continuous variables was tested with the Shapiro Wilk test. Kruskal Wallis and all pair wise multiple comparison tests were used for comparison of three independent groups of variables with a non-normal distribution. Median (25 – 75 %) values were given as descriptive statistics. Statistical analysis was performed with SPSS for Windows version 24.0 software. A value of $p < 0.05$ was accepted as statistically significant.

Results

The histopathological results of the gastrointestinal tract are summarized in Tables 1, 2 and 3. The control group was seen to be normal and no pathological lesions were encountered. The pathological findings of Group 3 (RAI+Vitamin E group) were found to be milder compared to Group 2 (RAI group). Severe inflammation was detected in the stomach, small intestines and bowel of the Group 2 rats which were applied RAI only (S = 0.005, D = 0.001, J = 0.001, I = 0.001, Ce = 0.001, C = 0.001, R = 0.001). Widespread fibrosis, necrosis, degeneration and edema were also detected in the stomach of Group 2 rats (Fig. 1). Severe inflammation (p = 0.001), edema (p = 0.001), ulcer (p = 0.037), mucosal degeneration (p = 0.001) and erosion (p = 0.001), fibrosis (p = 0.001) and necrosis (p = 0.002) were detected in the stomach tissues of the rats in Group 2 and the difference was statistically significant compared to the other groups (Tab. 1). Inflammation (D = 0.001, J = 0.001, I = 0.001), edema (D = 0.005, J = 0.004, I = 0.001),ulcer (D = 0.001, J = 0.001, I = 0.017), mucosal degeneration (D = 0.021, J = 0.021, I = 0.005), mucosal erosion (D = 0.001, J = 0.001, I = 0.004), fibrosis (D = 0.001, J = 0.001, I = 0.001) and necrosis (D = 0.001, J = 0.001, I = 0.001) in the small intestines were found to be more severe in Group 2 compared to the other groups (Tab. 2) (Fig. 2). Similar findings in the bowel tissues were more severe compared to the control group and the vitamin E-administered group (Group 3). Inflammation (Ce = 0.001, C = 0.001, R = 0.001), edema (Ce = 0.001, C = 0.001, R = 0.001), ulcer (Ce = 0.001, C = 0.001, R = 0.001), mucosal degeneration (Ce = 0.001, C = 0.001, R = 0.001), erosion (Ce = 0.001, C = 0.001, R = 0.001), fibrosis (Ce = 0.001, C = 0.001, R = 0.001)

Tab. 3. Statistically significant values of histopathological parameters of the bowel tissues of the groups.

Histopathological Parameters	Group 1			Group 2			Group 3			P
	Cecum	Colon	Rectum	Cecum	Colon	Rectum	Cecum	Colon	Rectum	
Edema	0[0-1]‡	1[0.5-1.5]‡	0[0-0]‡	1[0.5-2]	1[0.5-1.5]	1[0.5-1]	0[0-0]‡	0[0-0]‡	0[0-0]‡	Ce=0.001* C=0.001* R=0.001*
Inflammation	0[0-0]‡	0[0-0]‡	0[0-0]‡	2[1.5-2.5]	2[1.5-3]	2[1-3]	0.5[0-1]‡	0.5[0-1]‡	0.5[0-1]‡	Ce=0.001* C=0.001* R=0.001*
Fibrosis	0[0-0]‡	0[0-0]‡	0[0-0]‡	2[1.5-2.5]	2[2-2.5]	2[1.5-2.5]	0.5[0-1]‡	0.5[0-1]‡	0.5[0-1]‡	Ce=0.001* C=0.001* R=0.001*
Mucosal Erosion	0[0-0]‡	0[0-0]‡	0[0-0]‡	1[1-2]	1[1-2]	1[1-2]	0[0-0.5]‡	0[0-0.5]‡	0[0-0.5]‡	Ce=0.001* C=0.001* R=0.001*
Mucosal Degeneration	0[0-0]‡	0[0-0]‡	0[0-0]‡	1[1-1]	1[1-1]	1[1-1]	0[0-1]‡	0[0-1]‡	0[0-1]‡	Ce=0.001* C=0.001* R=0.001*
Ulcer	0[0-0]‡	0[0-0]‡	0[0-0]‡	0.5[0-1]	0.5[0-1]	0.5[0-1]	0[0-0]‡	0[0-0]‡	0[0-0]‡	Ce=0.001* C=0.001* R=0.001*
Necrosis	0[0-0]‡	0[0-0]‡	0[0-0]‡	1[1-1]	1.5[1-2]	0.5[0-1]	0[0-0]‡	0[0-1]‡	0[0-0]‡	Ce=0.001* C=0.001* R=0.001*

‡Median [25%-75%], *Significant at 0.05 level; Kruskal Wallis test, ‡ Signicant versus RAI; All pairwise multiple comparison test.

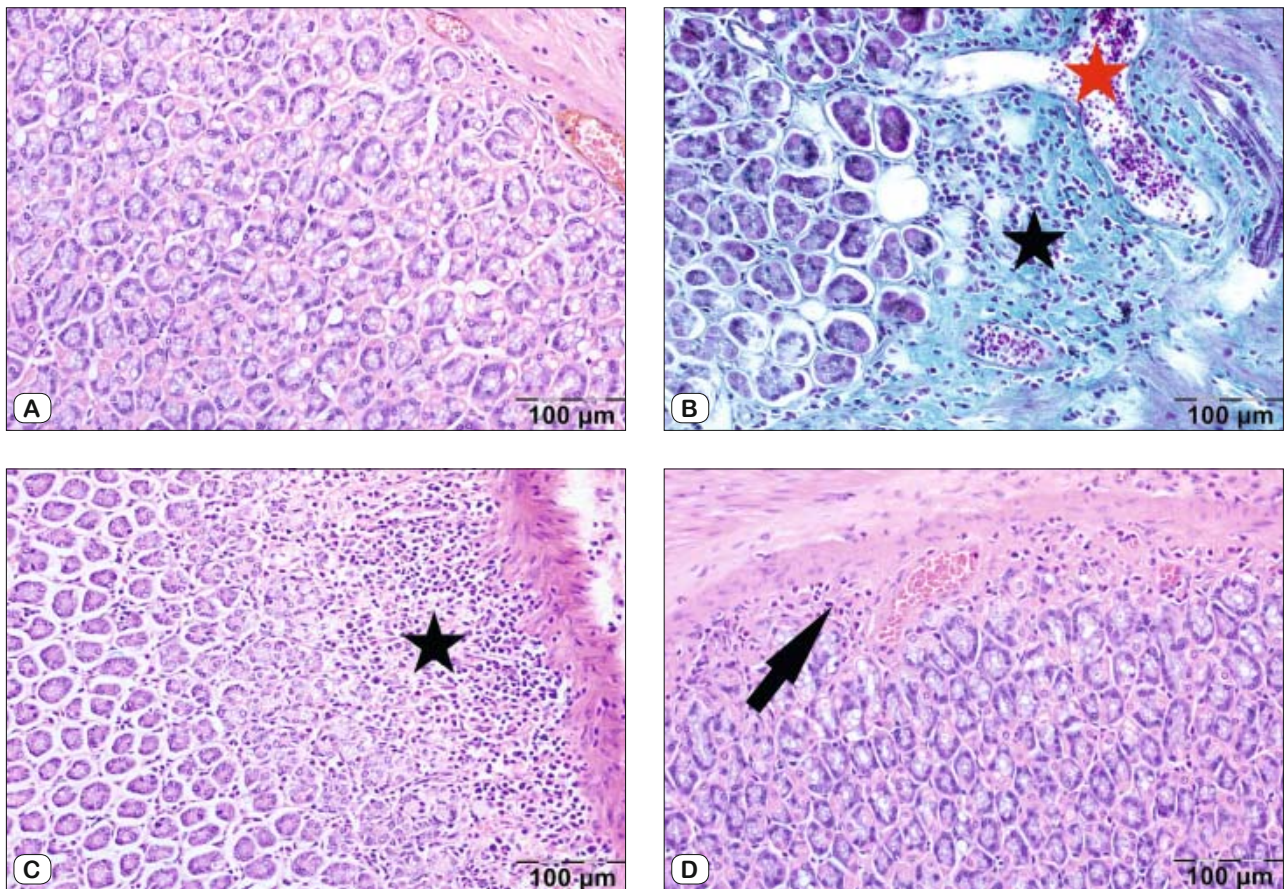


Fig. 1. Evaluation of histopathological changes of the stomach, HE and trichrome staining. A – Control group with no damage and normal glandular structure, HE staining. B – The RAI group presenting with diffuse fibrosis and severe inflammation (black star), hyperemia (red star), trichrome staining. C – RAI group presented with severe inflammation (star), HE staining. D – RAI+Vitamin E group inflammation and fibrosis near-complete recovery in the stomach (arrow), HE staining.

and necrosis ($C_e = 0.001$, $C = 0.001$, $R = 0.001$) were found to be milder in Group 3 than in Group 2 (Fig. 3).

Discussion

Despite the high treatment success rates of RAI, side-effects such as sialoadenitis, hepatitis and nephritis have been reported in some patients. Gastrointestinal system disorders are seen during the treatment period in many patients. Particularly epigastric pain, vomiting and enteritis are commonly encountered (18, 19). In the present study, evaluation was made of the pathomorphology of gastrointestinal damage in RAI-administered rats and the potential radioprotective effect of vitamin E, which is prescribed in many diseases due to its antioxidant property.

Preclinical studies have revealed pathological damage such as high-dose radiation-related inflammation and fibrosis in extra-thyroidal tissues of RAI-administered rats. However, there are few studies in literature that have investigated the pathomorphology of RAI-induced damage in the gastrointestinal system. Pashnehsaz

et al (20) observed clinical signs such as gastralgia, nausea, vomiting and diarrhea in RAI-administered thyroid cancer patients. Although Carroll et al (21) reported data about radio-protective agents used in the gastrointestinal system, sufficient knowledge is not available about tissue damage. Sadic et al (17) reported gastric and intestinal inflammation, fibrosis and degeneration due to high-dose RAI treatment. The current pathomorphological study has revealed similar findings; erosion, ulcer, inflammation, edema and degeneration were observed in gastric mucosa. In addition, severe inflammation and mucosal necrosis were observed in the duodenum and ileum. Intensive fibrosis was also observed in the duodenum, ileum and rectum.

The pathophysiology of the damage to extra-thyroid and gastrointestinal tissues has not yet been fully clarified. The most common opinion is that the damage develops from RAI-induced cellular oxidation. Oxidation has a causative role in degeneration, apoptosis, and inflammation (7). RAI which is taken into the cell by NIS leads to an elevation in free oxygen species and oxidative stress (4). In a study by Yilmaz et al (22) in which rats were ad-

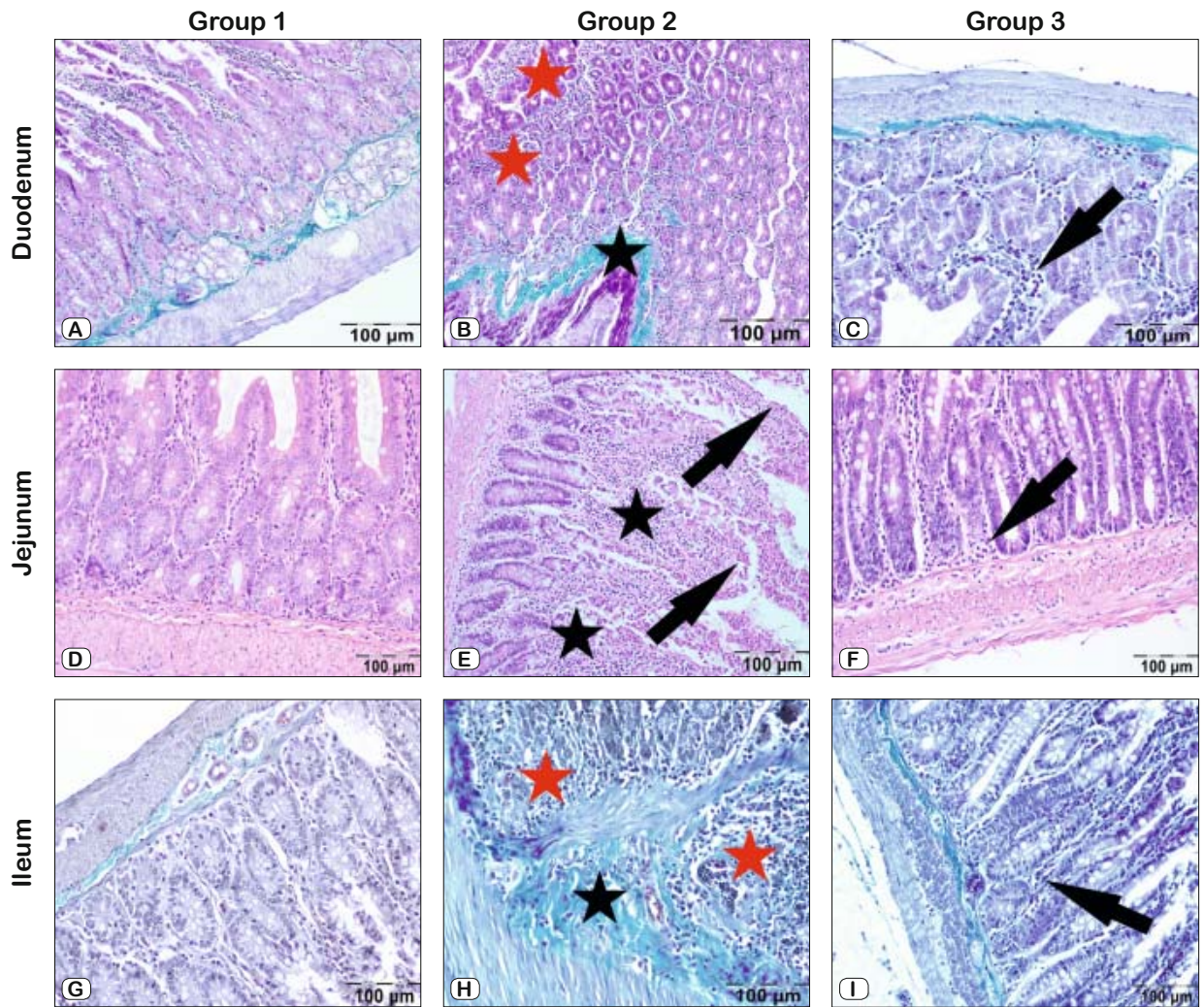


Fig. 2. Micropathological findings of the small intestine, HE and trichrome staining. A, D, G – Control (Group 1) group with no damage and normal glandular structure. B – In the duodenum severe inflammation (red stars) and diffuse fibrosis (black star), trichrome staining. C – Mild inflammation (arrow) showing in the duodenum, trichrome staining. E – In the jejunum of the RAI group (Group 2) severe inflammation (stars) and necrosis (arrows), and F – Mild inflammation in RAI+Vitamin E group (Group 3) (arrow), HE staining. H – In the RAI group, the ileum presented with diffuse fibrosis (black star) and severe inflammation (red stars), trichrome staining. I – Mild inflammation (arrows) in ileum, trichrome staining.

ministered RAI via the oral route, it was reported that intensive NIS is expressed only in the stomach in the 24th hour and NIS positivity was determined in the whole gastrointestinal system in the 3rd week. Immunohistochemically, NIS was determined to be greatly decreased in the 3rd month, demonstrating that RAI uptake is by NIS in the gastrointestinal system and it is excreted from the body over time. Severe inflammation and degenerative changes in gastrointestinal system tissues of RAI-administered rats suggest the role of ROS in the pathophysiology of the damage. The development of severe lesions, particularly in the stomach, on the 7th day at a significantly higher rate compared to the intestines suggests that this can be attributed to RAI staying longer in the stomach. In the current study, more severe gastrointestinal histopathological

findings in the RAI-only administered rats compared to the other groups suggests that this damage may be related to RAI in parallel with NIS expression.

Vitamin E is a vitamin found in many foods of plant and animal origin and its anti-oxidant property has been known for many years. Kudlackova et al (23) documented that vitamin E decreases the presence of oxidative stress and antioxidant metabolites. Upadhyaya et al (15) detected the protective effect of vitamin E against the radio-iodine-induced damage in salivary glands. Acar et al (13) proposed the anti-inflammatory and anti-fibrotic effect of vitamin E against the damage in lacrimal glands of RAI-administered rats. In a study by Ramos et al (24) the protective effect of vitamin E in single dose radiation-applied rats was detected by measuring

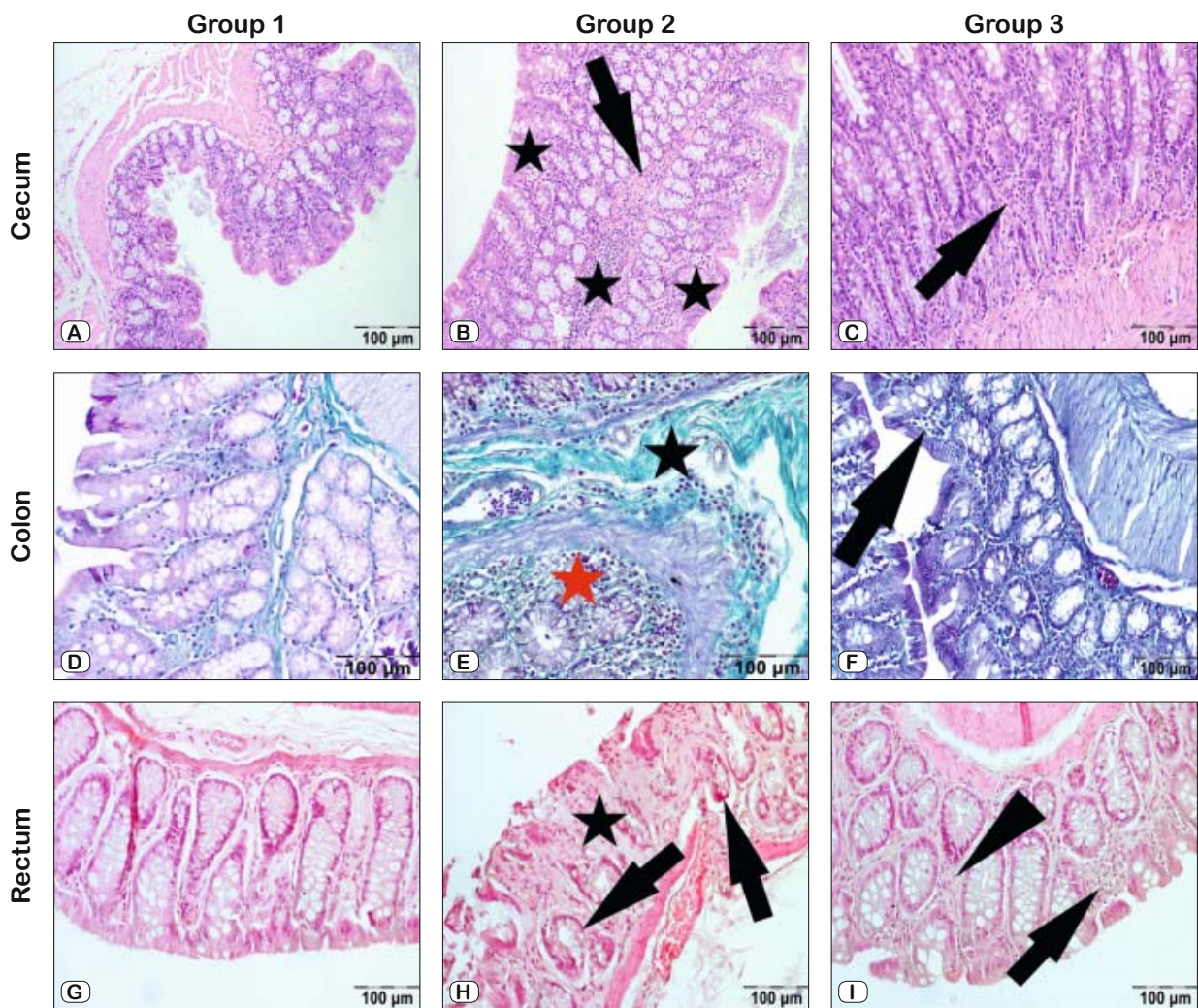


Fig. 3. Representative photomicrographs of the bowel, HE and trichrome staining. A, D, G – Control (Group 1) group with no damage. B – RAI group (Group 2) severe inflammation (stars) and fibrosis (arrow) in the cecum, and C – Mild inflammation (arrow) seen in RAI+Vitamin E group (Group 3), HE staining. E – In the colon severe inflammation (red star) and massive fibrosis (black star) in the RAI group; and F – Mild inflammation (arrow), trichrome staining. H – Diffuse fibrosis (star) and massive glandular necrosis (arrows) in the rectum of the RAI group, and I – Mild inflammation (arrow) and fibrosis (arrow head) in the RAI+Vitamin E group, HE staining.

the volume of saliva. Bhartiya et al (25) showed that vitamin E significantly decreased lipid peroxidation in salivary glands and recommended that it may be used as a radio-protective agent. Fallahi et al (14) evaluated the functions of salivary glands with scintigraphy and observed positive effects of vitamin E in patients receiving RAI therapy. Singh et al (26) showed that vitamin E protected mice from radiation-induced gastrointestinal injury and promoting the regeneration of crypt cells.

The results of the current study revealed that vitamin E has an anti-inflammatory effect against the histopathological damage in the gastrointestinal tract of RAI-administered rats. Inflammation was found to be significantly less in the gastrointestinal system of the RAI+ Vitamin E- administered rats compared to the RAI only group. Fibrosis and degenerative damage were seen to be more

severe in the RAI group and milder in the vitamin E group and this result indicates the protective effect of vitamin E.

In conclusion, severe histomorphological damage develops in the gastrointestinal system of RAI- administered rats. The present study demonstrated that vitamin E administered as anti-oxidant treatment in rats has a radio-protective effect against gastro-intestinal damage. It is highly probable that anti-inflammatory and anti-fibrotic activities are involved in the mechanism underlying the radioprotective effects of vitamin E.

Learning points

Acute severe inflammation, fibrosis and degeneration develop during RAI treatment.

Anti-inflammatory and anti-fibrotic activities are likely to be involved in the radioprotective effects of vitamin E against RAI-induced gastrointestinal damage.

Vitamin E may be prescribed as an ideal gastrointestinal radioprotective agent.

References

- Hertz S, Roberts A.** Radioactive iodine in the study of thyroid physiology; the use of radioactive iodine therapy in hyperthyroidism. *J Am Med Assoc* 1946; 131: 81–86.
- Seidlin SM, Marinelli LD, Oshry E.** Radioactive iodine therapy; effect on functioning metastases of adenocarcinoma of the thyroid. *J Am Med Assoc* 1946; 132: 838–847.
- Ziessman HA, O'Malley JP, Thrall JH.** Nuclear medicine: the requisites. Elsevier Health Sciences 2013; 66–97.
- Nicola JP, Basquin C, Portulano C et al.** The Na⁺/I⁻ symporter mediates active iodide uptake in the intestine. *Am J Physiol Cell Physiol* 2009; 296: 654–662.
- Fard-Esfahani A, Emami-Ardekani A, Fallahi B et al.** Adverse effects of radioactive iodine-131 treatment for differentiated thyroid carcinoma. *Nucl Med Commun* 2014; 35: 808–817.
- Epperly MW, GreRon JE, Sikora CA et al.** Mitochondrial localization of superoxide dismutase is required for decreasing radiation-induced cellular damage. *Rad Res* 2003; 160: 568–578.
- Marx K, Moka D, Schomacker K et al.** Cell death induced by 131I in a differentiated thyroid carcinoma cell line in vitro: Necrosis or apoptosis? *Nucl Med Commun* 2006; 27: 353–358.
- Barlas A, Bag Y, Pekcici M et al.** Melatonin: a hepatoprotective agent against radioiodine toxicity in rats. *Bratisl Lek Listy* 2017; 118: 95–100.
- Shirazi A, Mihandoost E, Mahdavi SR, Mohseni M.** Radio-protective role of antioxidant agents. *Oncol Rev* 2012; 6: 16.
- Nagyova A, Kudlackova KM, Horska A et al.** Lipid peroxidation in men after dietary supplementation with a mixture of antioxidant nutrients. *Bratisl Lek Listy* 2004; 105 (7–8): 277–280.
- Reboul E.** Vitamin E bioavailability: Mechanisms of intestinal absorption in the spotlight. *Antioxidants* 2017; 22 (4): 95
- Jiang Q.** Natural forms of vitamin E: metabolism, antioxidant, and anti-inflammatory activities and their role in disease prevention and therapy. *Free Radic Biol Med.* 2014; 72:76–90
- Acar U, Atilgan HI, Acar DE, Yalniz-Akkaya Z et al.** The effect of short-term vitamin E against radioiodine-induced early lacrimal gland damage. *Annals of nuclear medicine.* 2013; 27 (10): 886–891.
- Fallahi B, Beiki D, Abedi SM, Saghari M et al.** Does vitamin E protect salivary glands from I-131 radiation damage in patients with thyroid cancer? *Nucl Med Commun* 2013; 34 (8): 777–786.
- Upadhyaya A, Zhou P, Meng Z et al.** Radioprotective effect of vitamin E on salivary glands after radioiodine therapy for differentiated thyroid cancer: a randomized-controlled trial. *Nucl Med Commun* 2017; 38 (11): 891–903.
- Luna LG.** Manual of histologic staining methods of the armed forces. Institute of Pathology . New York: Blakiston, 1968: 1–46.
- Sadic M, Aydinbelge FN, Yumusak N et al.** Radioprotective effect of lycopene on the gastrointestinal tract after high-dose radioiodine administration in rat models. *Nucl Med Commun* 2017; 38 (12): 1041–1046.
- Kita T, Yokoyama K, Higuchi T et al.** Multifactorial analysis on the short-term side effects occurring within 96 h after radioiodine- 131 therapy for differentiated thyroid carcinoma. *Ann Nucl Med* 2004; 18: 345–349.
- Lu L, Shan F, Li W, Lu H.** Short-term side effects after radioiodine treatment in patients with differentiated thyroid cancer. *Biomed Res Int* 2016; 4376720.
- Pashnehsaz M, Takavar A, Izadyar S et al.** Gastrointestinal side effects of the radioiodine therapy for the patients with differentiated thyroid carcinoma two days after prescription. *World J Nucl Med* 2016; 15: 173–178.
- Carroll MP, Zera RT, Roberts JC et al.** Efficacy of radioprotective agents in preventing small and large bowel radiation injury. *Dis Colon Rectum* 1995; 38: 716–722.
- Yilmaz R, Yumusak, N, Sadic M et al.** The scintigraphic, biodistribution and histopathological evaluation of the effect of experimental 131I administration on the gastrointestinal system and the demonstration of the Na⁺/I⁻ symporter by immunohistochemistry in rats. *Nucl Med Commun* 2018; 39 (6): 511–520.
- Kudlackova KM, Ursinyova M, Blazicek P et al.** Free radical disease prevention and nutrition. *Bratisl Lek Listy* 2003; 104 (2): 64–68.
- Ramos FM, Pontual ML, Almeida SM et al.** Evaluation of radioprotective effect of vitamin E in salivary dysfunction in irradiated rats. *Arch Oral Biol* 2006; 51: 96–101.
- Bhartiya US, Raut YS, Joseph LJ et al.** Evaluation of the radioprotective effect of turmeric extract and vitamin E in mice exposed to therapeutic dose of radioiodine. *Indian J Clin Biochem* 2008; 23: 382.
- Singh VK, W SY, Scott JR, Romaine PLP et al.** Radioprotective efficacy of delta-tocotrienol, a vitamin E isoform, is mediated through granulocyte colony-stimulating factor. *Life Sci* 2014; 98 (2): 113–122.

Received January 15, 2019.
Accepted February 18, 2019.