

The protective role of folic acid against testicular dysfunction in lead-intoxicated rat model

Asmaa M. S. Gomaa¹, Nasser S. Abou Khalil¹ and Mohammed A. Abdel-Ghani²

¹ Department of Medical Physiology, Faculty of Medicine, Assiut University, Assiut, Egypt

² Department of Theriogenology, Faculty of Veterinary Medicine, Assiut University, Assiut, Egypt

Abstract. There is an increasing concern over male reproductive toxicity caused by lead exposure. Folic acid (FA) is supposed to be a promising therapeutic strategy against lead toxicity. Therefore, the aim of this experimental study was to shed light on the potential protective role of FA on lead-induced testicular dysfunction in rats and its possible underlying mechanistic pathways. Rats ($n = 24$) were divided into four groups: Control, FA, Lead, and FA+Lead group. After 4 weeks, lead intoxication resulted in a marked reduction in the relative testicular weight and the serum level of testosterone, an impairment in the characters of semen analysis, and an increased content of lead, malondialdehyde and both interleukin-6 and -10 and a decreased antioxidant enzyme levels in the testicular tissue homogenate. Furthermore, marked degenerative histological changes and an increased expression of NF- κ B were also noticed in the testicular tissue of Lead group. Supplementation of FA in association with lead considerably alleviated these adverse outcome responses most probably owing to its cytoprotective ability as emerged from combating the oxidative stress and inflammatory reactions. We concluded that FA could act as a highly effective fighting approach against lead-associated testicular toxicity.

Key words: Folic acid — Lead — NF- κ B — Oxidative stress — Semen analysis

Introduction

The causative link between heavy metals exposure and health burden remains a topic of research for many years and represents a scientifically attractive area for investigators due to a gradual rise in occupational and environmental poisoning risks. The non-biodegradable nature, prolonged persistence in the environment and variable ways of exposure (Carocci et al. 2015) direct the attention towards lead as a major globally hazardous pollutant with general negative health effects (Sun et al. 2016a) especially on the male reproductive organs (Elgawish and Abdelrazek 2014).

In Egypt, the control of lead exposure is not efficient and hence, environmentally and occupationally exposed urban Egyptian men were found to have erectile dysfunction and impaired semen parameters (El-Zohairy et al. 1996; Anis et al. 2007). Induction of oxidative stress and inflammation were supposed to be important mechanistic avenues of lead-

associated testicular dysfunction (Elgawish and Abdelrazek 2014; Barbhuiya and Sengupta 2015). Oxidative stress could enhance the activation of nuclear transcription factor kappa B (NF- κ B), which in turn controls the transcription of genes involved in the immune response, inflammation and apoptosis (Lee et al. 2014). However, plenty of controversies still emerged about its testicular toxicity relative to strain/age differential response (Elgawish and Abdelrazek 2014) providing a driving force for continuation in exploring this area of research with respect to the multifactorial nature of testicular impairment.

The search for agents having a powerful ameliorative impact against this widely spread toxicant with potential natural biological occurrence and predictably having no side effects is worthwhile. In this regard, a still not fully researched folic acid (FA) is considered a highly promising candidate owing to its anti-apoptotic, anti-inflammatory and anti-oxidant activities (Majumdar et al. 2010; Hwang et al. 2011; Zhao et al. 2013) giving a rationality to block the multiple toxicological targets of lead. Dietary FA deficiency acts as a predisposing factor in increasing the susceptibility for lead intoxication (Rader et al. 1982). Up to our knowledge,

Correspondence to: Asmaa M. S. Gomaa, Department of Medical Physiology, Faculty of Medicine, Assiut University, Assiut, Egypt
E-mail: asmaagom3a@yahoo.com

there is one available literature about the combating effects of this therapeutic agent against neurotoxicity induced by lead exposure in rat pups (Quan et al. 2015). Therefore, the mission of this study is to shed light on the potential protective role of FA on lead-induced testicular dysfunction in rat and its possible underlying mechanistic pathways.

Materials and Methods

Animals and experimental design

Twenty-four adult male Wistar albino rats aged 7–8 weeks (120–135 g in weight) obtained from the Animal House of Assiut University were used in this study. They were kept at room temperature in polypropylene cages and were exposed to a natural 12 h light/dark cycle with free access to standard laboratory chow and water *ad libitum*. Experimental procedures in this study were conducted in accordance with the internationally accepted principles for the Care and Use of Laboratory Animals and were approved by our institutional ethics committee.

After 7 days of acclimatization, rats were randomly divided into four groups (six animals each): Control group received distilled water daily by oral gavage, FA group treated daily with FA (CAS: 59-30-3, Oxford Lab. Co., India) at a dose of 2 mg/kg body weight (b.w.) by oral gavage (Ajeigbe et al. 2011) for 4 weeks, Lead group administered lead acetate (CAS: 6080-56-4, Oxford Lab. Co., India) 5 days weekly at a dose of 10 mg/kg b.w. *intraperitoneal* (*i.p.*) (Hamed et al. 2014) for 4 weeks, and the FA+Lead group received the same previous doses of both FA and lead acetate for the same duration.

At the end of the experiment, animals were weighed and fasting venous blood samples were collected in plain tubes from the retro-orbital vein in anesthetized rats by an experienced laboratory technician. Then, animals were sacrificed by cervical dislocation. Blood samples were centrifuged at 3000 rpm for 15 min and the clear supernatant sera were removed and kept at -20°C until use. Orchidectomy was performed by open castration method through a midline incision and the testis was milked out of the incision site, weighed and rapidly exposed by incising the tunica vaginalis and the cauda epididymis was quickly removed and used for semen analysis. The relative testicular weight was calculated as the percentage ratio of testicular weight to body weight. One testis was kept at -80°C until use for further analysis and the other testis was used for histopathological examination.

Measurement of the serum testosterone hormone level

Testosterone has been estimated by the enzyme-linked immunosorbent assay kit (Cat. No. BC-1115, BioCheck, Inc.,

Foster City, USA) according to the manufacturer's instructions. The serum testosterone level was expressed as ng/ml.

Semen analysis

Semen was collected as previously described (Oyeyemi and Ubiogoro 2005). Briefly, cauda epididymis was opened longitudinally with a pair of fine-pointed scissors, and epididymal content was squeezed into a sterile watch glass. Sperm motility was examined microscopically as explained previously (Zemjanis 1977). The spermatozoa were counted by a hemocytometer using the improved Neubauer chamber (LABART, Germany) (Pant and Srivastava 2003). Sperm morphology was assessed using alkaline methyl violet stain. Briefly, the stain was poured off on slides containing diluted semen sample (1:4) and the stain was left for 5–10 min. Thereafter, slides were washed with distilled water, dried with filter paper and examined under the light microscope (Olympus CH, Japan) where the spermatozoa appeared violet in colour. A total of 200 spermatozoa from each rat were examined for morphological changes and the percentage of morphologically normal sperms was recorded. The viability of sperms was assessed using Eosin & Nigrosine stain. The stain could pass only through the non-living cell membrane and hence, non-viable sperms absorbed the stain and appear red and viable sperms appear colorless. Viability was reported as the percentage of total number of colorless sperms (Bjorndahl et al. 2003).

Measurement of testicular lead concentration

Testicular tissue was digested with concentrated nitric acid and was placed in an oven at 40°C for 30 min. Then, digests were diluted to a constant volume with distilled water. The diluted tissue samples were analyzed using atomic absorption spectrophotometer (Buck model 210 VGP, East Norwalk, CT, USA), and the results were reported as $\mu\text{g/l}$.

Measurement of testicular oxidative stress biomarkers

Testicular tissues from all animals were homogenized in phosphate buffer saline to give 10% (wt/v) homogenate. The homogenate was centrifuged for 15 min at $5000 \times g$ at 4°C . Then, homogenates were used for estimation of superoxide dismutase (SOD), glutathione peroxidase (GSH-Px), catalase (CAT) and malondialdehyde (MDA) using commercially available colorimetric kits (Bio-Diagnostics, Egypt, Cat. No. SD2521, GP 2524, CA 2517, and MD 2529; respectively) according to the manufacturer's protocol. Briefly, measuring SOD was based on its ability to decrease the phenazine methosulphate-mediated reduction of nitroblue tetrazolium dye to form a red product (Nishikimi et al. 1972). The oxidation of NADPH to NADP^+ is associated with a decrease in

absorbance at 340 nm providing spectrophotometric means for measuring GSH-Px levels (Paglia and Valentine 1967). CAT was determined based on the fact that 3,5-dichloro-2-hydroxybenzene sulfonic acid could rapidly terminate the degradation reaction of hydrogen peroxide catalyzed by CAT and react with the residual hydrogen peroxide to generate a yellow product (Aebi 1984). The reaction of thiobarbituric acid with MDA in acidic medium to form thiobarbituric acid reactive pink product was the principle for estimation of MDA (Ohkawa et al. 1979). Total protein in testicular homogenate samples was assayed using biuret reagent (Gornall et al. 1949). Results of SOD, GSH-Px and CAT were expressed as U/mg protein, and results of MDA were reported as nM/mg protein.

Measurement of testicular interleukin IL-6 and IL-10

Testicular homogenates were used for estimation of IL-6 and IL-10 concentrations according to the manufacturer's instructions (Koma Biotech Inc., Seoul, Korea; K0112464 and K0332134, respectively). Briefly, samples were added to 96-microwell ELISA plates, precoated with a monoclonal antibody directed against each cytokine. Standards of known rat cytokines concentration and unknown samples were pipetted into these wells. After 3 hours of incubation, the IL-6 or IL-10 antigen binds to the coating antibody. After washing, a biotinylated (detection) antibody specific for both cytokines was added to bind to the IL-6 or IL-10 antigens captured during incubation. After incubation, plates were washed and a streptavidin-horseradish peroxidase (Colour Development enzyme) was added. This enzyme binds to the detection antibody. After incubation for 30 min and further washing, colour development solution was added and the plates were read using a microplate reader at 450 nm. A standard curve was created to obtain the concentration of the unknown samples. Their levels were reported as ng/mg protein.

Histopathology and immunohistochemistry

Specimens from the testis of all animals were fixed in 10% neutral buffered formalin, dehydrated and embedded in

paraffin. 5 μ m thick sections were cut and stained with Hematoxylin and Eosin (H&E) as described previously (Bancroft and Gamble 2008).

Immunohistochemical staining of NF- κ B/p65 was performed by the avidin biotin immunoperoxidase complex technique (Ultravision plus detection system anti-polyvalent HRP/DAB, Thermo scientific Corporation Fremont, CA, USA). Immunohistochemistry was performed according to the manufacturer's protocol. Briefly, 4 μ m-sections were deparaffinized in xylene and rehydrated with graded alcohol series. Endogenous peroxidase was blocked by immersion of the sections in 3% hydrogen peroxide solution for 10 min. Sections were then subjected to antigen retrieval by immersing them in 10 mM citrate buffer for 10 min followed by placing them in the microwave for 8 min. Then, samples were incubated with NF- κ B/p65 at a dilution of 1:100 for one hour at 4°C. After the application of a secondary antibody, slides were covered by adding one drop of 3-3'-diaminobenzidine chromogen. Finally, sections were counterstained with Mayer's hematoxylin. Negative control slides were prepared by omitting the primary antibody.

Statistical analysis

All data were expressed as mean \pm SD. Statistical differences between groups were analyzed by one-way analysis of variance (ANOVA) followed by Tukey's test after investigating the data for normality using Shapiro-Wilk test to be sure that the data are normally distributed using SPSS program version 16 (SPSS Inc., Chicago, USA). Differences of $p < 0.05$ were considered to be significant.

Results

The relative testicular weight and serum testosterone levels

Table 1 showed that there was insignificant difference between the relative testicular weight of Control and FA groups ($0.97 \pm 0.11\%$ versus $0.85 \pm 0.13\%$). Lead administration resulted in a significant decrease of the relative

Table 1. Relative testicular weight, testicular lead concentration and interleukin (IL-6 and IL-10) levels in the experimental groups

	Group			
	Control	FA	Lead	FA+Lead
Relative testicular weight (%)	0.97 ± 0.11	0.85 ± 0.13	$0.55 \pm 0.16^{a,b}$	0.91 ± 0.24^c
Testicular lead concentration (μ g/l)	0.396 ± 0.08	0.411 ± 0.07	$0.656 \pm 0.03^{a,b}$	0.518 ± 0.07^c
IL-6 (ng/mg protein)	127.5 ± 5.68	127.9 ± 9.08	$207.6 \pm 23.94^{a,b}$	$158.1 \pm 19.45^{a,b,c}$
IL-10 (ng/mg protein)	130.3 ± 6.37	126.3 ± 6.68	$276.6 \pm 27.10^{a,b}$	$210.7 \pm 23.06^{a,b,c}$

Values are expressed as means \pm SD of 6 rats per group. ^a $p < 0.05$ significantly different from Control group, ^b $p < 0.05$ significantly different from FA group, ^c $p < 0.05$ significantly different from Lead group. FA, folic acid.

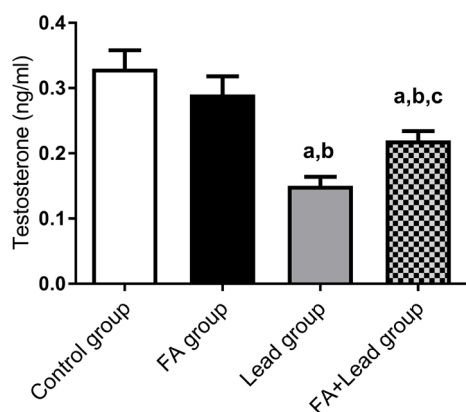


Figure 1. Serum testosterone level in the various experimental groups. Values are expressed as means \pm SD. ^a $p < 0.05$ significantly different from Control group, ^b $p < 0.05$ significantly different from FA group, ^c $p < 0.05$ significantly different from Lead group. FA, folic acid. For more information, see Materials and Methods.

testicular weight ($0.55 \pm 0.16\%$) when compared with Control and FA groups. Treatment with FA associated with lead administration significantly increased relative testicular weight to $0.91 \pm 0.24\%$ in comparison with Lead group. The relative testicular weight of FA+Lead group

showed insignificant difference when compared with both Control and FA groups.

Figure 1 revealed the absence of significant difference between the serum testosterone levels of Control group (0.33 ± 0.03 ng/ml) versus those of the FA-supplemented one (0.29 ± 0.03 ng/ml). Lead intoxication was manifested by a significant reduction of the serum testosterone levels (0.15 ± 0.01 ng/ml) when compared with both Control and FA groups. FA treatment in association with lead intoxication significantly succeeded in elevation of the serum testosterone levels to 0.22 ± 0.01 ng/ml in comparison with Lead group. However, it was still significantly lower than those of Control and FA groups.

Semen analysis

Figure 2 showed that there were insignificant differences in all tested parameters of semen analysis (sperm motility, sperm count and the percentages of morphologically normal and viable spermatozoa) between Control group (80.0 ± 4.08 , 48.8 ± 5.56 , 82.25 ± 3.86 and $84.25 \pm 2.98\%$) and FA group (83.0 ± 3.55 ; 51.8 ± 6.60 , 85.0 ± 4.08 and $88.50 \pm 2.38\%$). Lead administration altered semen analysis in the form of significant reductions of sperm motility, sperm count and the percentages of morphologically normal and

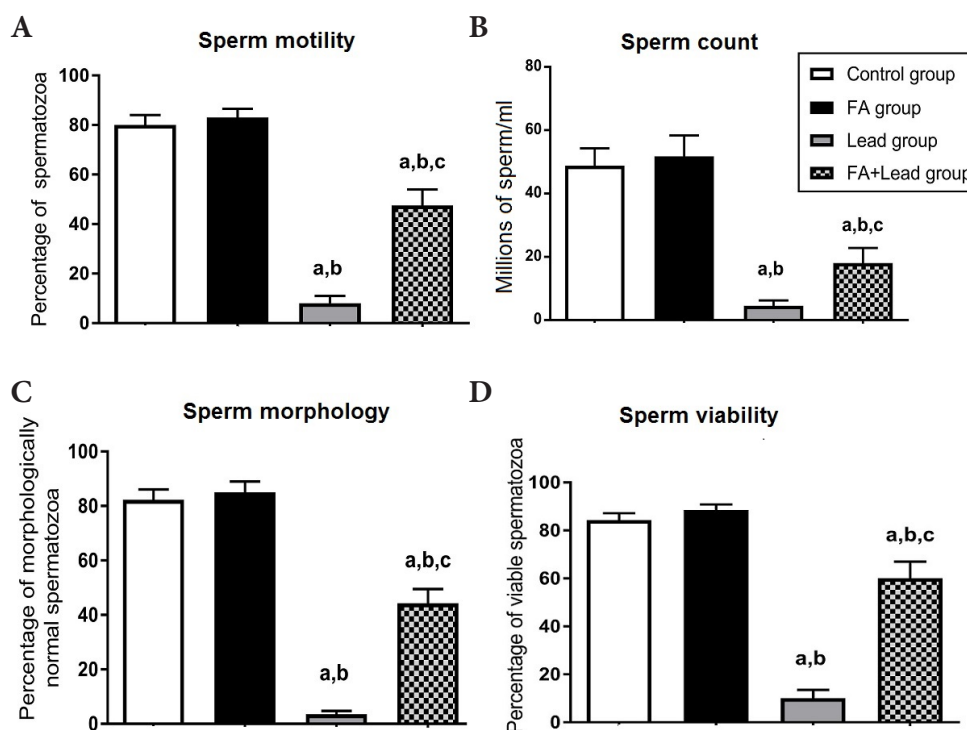


Figure 2. Semen analysis outcomes in the various experimental groups. Tested parameters: sperm motility (A), sperm count (B), sperm morphology (C) and sperm viability (D). Values are means \pm SD. ^a $p < 0.05$ significantly different from Control group, ^b $p < 0.05$ significantly different from FA group, ^c $p < 0.05$ significantly different from Lead group. FA, folic acid.

viable spermatozoa when compared with both Control and FA groups ($8.00 \pm 2.94\%$, $4.50 \pm 1.73\%$, $3.50 \pm 1.29\%$, and $10.0 \pm 3.55\%$). FA treatment in combination with lead intoxication resulted in a marked improvement in the form of significant increases in all tested parameters of semen analysis ($47.5 \pm 6.45\%$, $18.0 \pm 4.83\%$, $44.25 \pm 5.31\%$, and $60.0 \pm 7.07\%$) in comparison with Lead group. However, in comparison with Control and FA groups, FA+Lead group showed a significant reduction in all tested parameters of semen analysis.

Testicular lead concentration

Regarding lead concentration in testicular homogenates, there was no significant difference between Control ($0.396 \pm 0.08 \mu\text{g/l}$) and FA ($0.411 \pm 0.07 \mu\text{g/l}$) groups. A significant increase of lead content in testicular tissue of Lead group ($0.656 \pm 0.03 \mu\text{g/l}$) was found when compared with both Control and FA groups. Treatment with FA in combination with lead supplementation resulted in a marked reduction of lead content to $0.518 \pm 0.07 \mu\text{g/l}$ in comparison with Lead group. However, there was no significant increase in lead concentration of testicular tissue of FA+Lead group in comparison with both Control and FA groups (Table 1).

Testicular oxidative stress biomarkers

No significant differences could be found in the testicular enzymatic antioxidant levels; namely SOD, CAT and GSH-Px of control rats (203.13 ± 45.89 , 1.68 ± 0.33 and $42.08 \pm 9.13 \text{ U/mg protein}$; respectively) versus the FA-supplemented ones (201.70 ± 38.18 , 1.68 ± 0.36 and $43.58 \pm 8.96 \text{ U/mg protein}$; respectively). The testis of animals of Lead group showed a significant reduction in SOD, CAT and GSH-Px levels reaching 65.55 ± 10.67 , 0.55 ± 0.13 and $14.13 \pm 2.70 \text{ U/mg protein}$, respectively, in comparison with both Control and FA groups. A significant elevation was observed in SOD, CAT and GSH-Px levels to 126.85 ± 11.76 , 1.05 ± 0.13 and $24.40 \pm 1.82 \text{ U/mg protein}$, respectively, following FA administration to lead-intoxicated rats, but their levels were still significantly below those in Control and FA groups (Figure 3).

Testicular MDA level of Control group ($2.63 \pm 0.57 \text{ nM/mg protein}$) exhibited no significant difference when compared with the FA group ($2.5 \pm 0.47 \text{ nM/mg protein}$). Testicular tissue of Lead group was characterized by a significant elevation in MDA levels reaching $5.53 \pm 0.66 \text{ nM/mg protein}$ as compared with Control and FA groups. FA treatment of rats intoxicated with lead was efficient in reducing lipid peroxidation as evident by a significant decline in

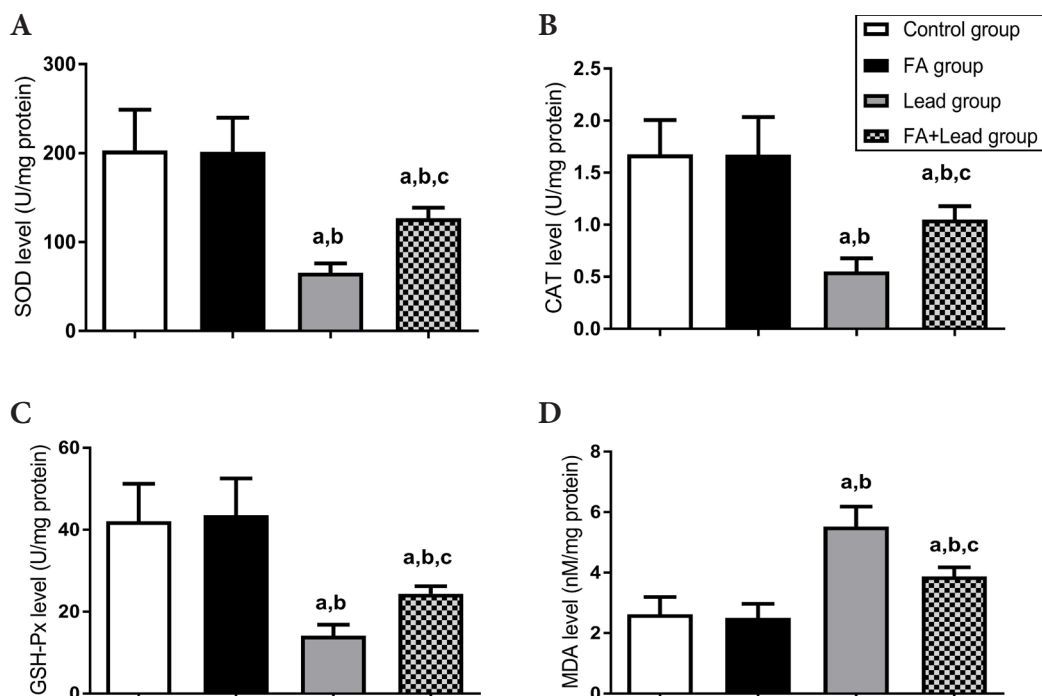


Figure 3. Levels of enzymatic antioxidants: superoxide dismutase (SOD, **A**), glutathione peroxidase (GSH-Px, **B**), catalase (CAT, **C**) and malondialdehyde (MDA, **D**) in testicular tissue homogenate of various experimental groups. Values are means \pm SD. ^a $p < 0.05$ significantly different from Control group, ^b $p < 0.05$ significantly different from FA group, ^c $p < 0.05$ significantly different from Lead group. FA, folic acid.

MDA level to 3.88 ± 0.29 nM/mg protein. Moreover, MDA level of FA+Lead group was significantly higher than that in Control and FA groups (Figure 3).

Testicular IL-6 and IL-10

Insignificant differences were noted in the testicular levels of both IL-6 and IL-10 between Control (127.5 ± 5.68 and 130.3 ± 6.37 ng/mg protein) and FA (127.9 ± 9.08 and 126.3 ± 6.68 ng/mg protein) groups. However, lead administration resulted in a significant increase of both IL-6 (207.6 ± 23.94 ng/mg protein) and IL-10 (276.6 ± 27.10 ng/mg protein) levels in testicular tissue in comparison with both Control and FA groups. Treatment with FA in combination with lead administration resulted in a significant decrease in the levels of both IL-6 (158.1 ± 19.45 ng/mg protein) and IL-10 (210.7 ± 23.06 ng/mg protein) in comparison with Lead group. However, in comparison with both Control and FA groups, levels of both IL-6 and IL-10 in FA+Lead group were significantly higher (Table 1).

Histopathology and immunohistochemistry

Microscopic examination of sections of the testis of both Control and FA groups showed the normal histological structure of the testis (Figure 4A and B). Sections of Lead group revealed the presence of oedematous seminiferous tubules with irregular contour, abnormal architecture and acidophilic degenerated hyalinized center. Furthermore, degenerated or hyalinized interstitial tissue was also present. Spermatogenic, Sertoli and Leydig cells appeared disorganized, degenerated and apoptotic. There were also sloughed apoptotic germ cells in the center of the seminiferous tubules, reduced spermatogenic cells count and reduced height of germinal epithelium (less than 3 layers). In some areas of the seminiferous tubules, there was a complete loss of spermatogenic cells which were replaced by degenerated tissue (Figure 4C). Treatment with FA in combination with lead administration resulted in a marked histological improvement as seminiferous tubules appeared at different stages of

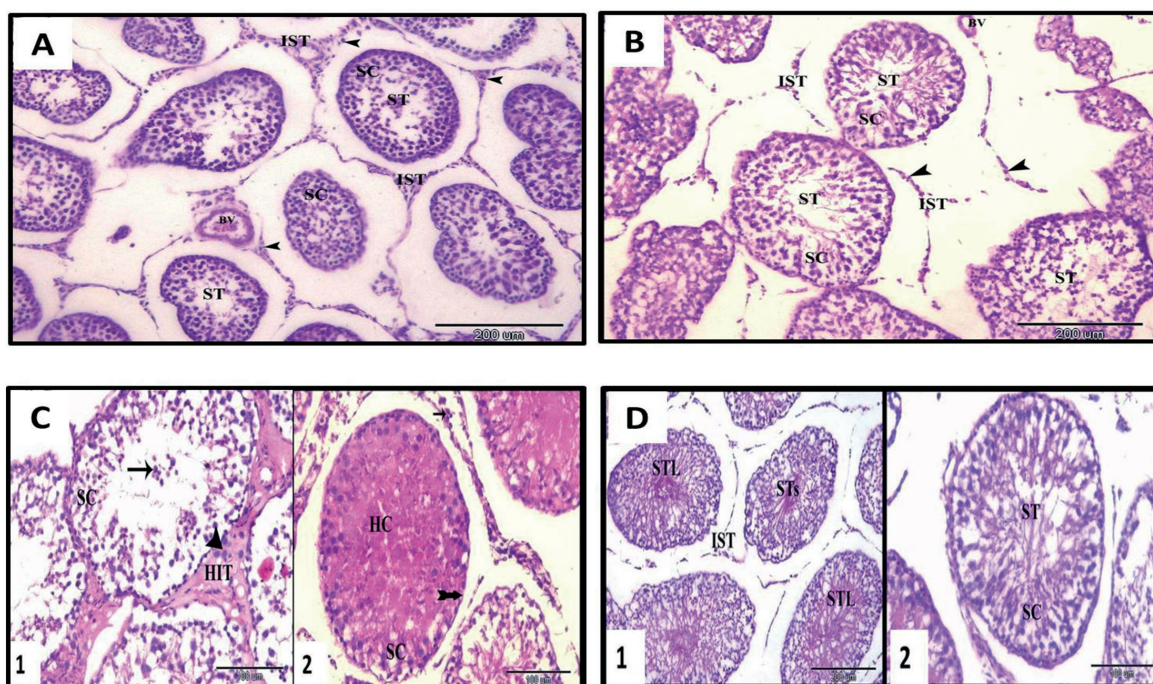


Figure 4. Photomicrograph of H&E-stained sections of the testis of rats in various experimental groups. **A.** Control group showed the normal architecture and contour of seminiferous tubules (ST) with healthy, multi-layered spermatogenic cells (SC) and normal vascular interstitial tissue (IST) with Leydig cells (arrow head) and blood vessels (BV) (magnification $\times 100$). **B.** FA group showed the normal histological appearance of testis similar as Control group (magnification $\times 100$). **C.** Lead group showed: 1, disorganized SC, apoptotic germ cells (arrow) in the center of the seminiferous tubules and apoptotic Leydig cells (arrow head) and degenerated hyalinized interstitial tissue (HIT); 2, seminiferous tubules with acidophilic degenerated hyalinized center (HC), in some areas of the seminiferous tubules there was complete loss of spermatogenic cells (forked tail arrow) and apoptotic or degenerated Leydig cells (arrow) were also observed. Magnification $\times 200$. **D.** The FA+Lead group showed: 1, seminiferous tubules in different stages of improvement; seminiferous tubules with large acidophilic fibrosed center (STL) and other seminiferous tubules with small acidophilic fibrosed center (STs). Note the normal IST with Leydig cells (magnification $\times 100$). 2, seminiferous tubules appeared more or less normal with nearly healthy SC at different stages of spermatogenesis (magnification $\times 200$).

improvement as some seminiferous tubules appeared with a large and others with a small acidophilic fibrosed center. Seminiferous tubules in advanced stages of improvement had a continuous basement membrane and contained nearly healthy multilayered spermatogenic cells at different stages of spermatogenesis. The interstitial tissue and Leydig cells appeared more or less normal (Figure 4D).

Immunostaining of sections of the testis of Control and FA groups showed moderate cytoplasmic expression of NF- κ B in spermatogonia, primary spermatocytes and myoid cells in many of the cross-sections of the seminiferous tubules. In contrast, the majority of the cross-sections showed no nuclear NF- κ B expression except for a weak nuclear staining of few Sertoli cells. Identification of Sertoli cells was based on their typical localization in the seminiferous epithelium and their characteristic oval nu-

cleus. Moderate cytoplasmic staining of NF- κ B was also observed in Leydig cells (Figure 5A and B). However, immunostaining of sections of testis of Lead group revealed an intense nuclear immunostaining of NF- κ B in the germ cells. Immunostaining of sections of FA+Lead group showed a moderate cytoplasmic and nuclear staining of NF- κ B in spermatocytes and spermatid and an intense nuclear and moderate cytoplasmic immunostaining of NF- κ B in few germ cells (Figure 5C and D).

Discussion

In the current study, FA dietary intervention efficiently mitigates lead-induced testicular dysfunction *via* combating oxidative stress and inflammatory signs due its antioxidant

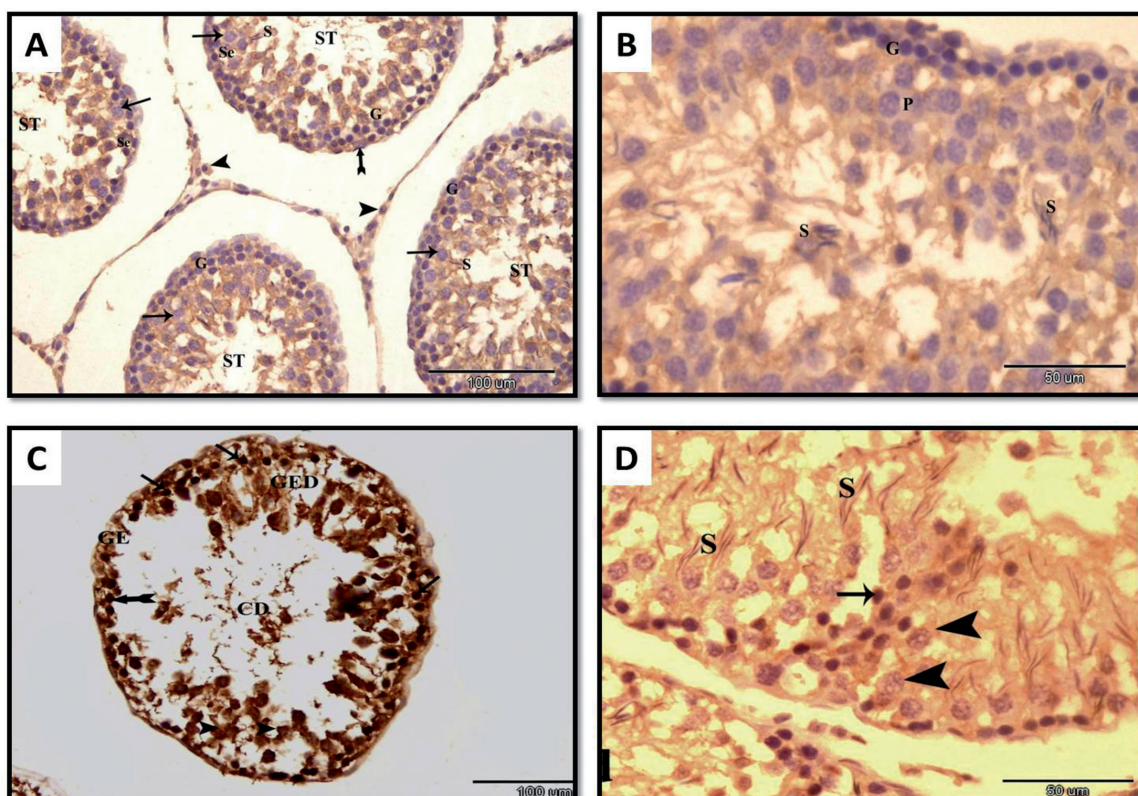


Figure 5. Photomicrograph of NF- κ B/p65-immunostained sections of the testis of rats in various experimental groups. **A.** Control group showed the cellular localization of the NF- κ B/p65. In many cross-sections of the seminiferous tubules (ST), moderate cytoplasmic expression of NF- κ B was observed in spermatogonia (G), primary spermatocytes (arrow) and myoid cells (forked tail arrow). The majority of the cross-sections showed no nuclear NF- κ B/p65 expression except for weak nuclear staining of few Sertoli cells (Se). Moderate cytoplasmic staining of NF- κ B/p65 was also observed in Leydig cells (arrow head). Magnification $\times 200$. **B.** FA group showed moderate cytoplasmic staining of NF- κ B/p65 in spermatogonia (G), primary spermatocytes (P) and spermatid (S). Note no nuclear NF- κ B/p65 expression was detected. Magnification $\times 400$. **C.** Lead group showing intense nuclear immunostaining of NF- κ B/p65 in the germ cells (arrow), degenerated germ cells (arrow head). Magnification $\times 200$. **D.** FA+Lead group showing moderate cytoplasmic and nuclear NF- κ B/p65 expression in spermatocytes (arrow head) and spermatid (S), intense nuclear and moderate cytoplasmic immunostaining of NF- κ B/p65 in few germ cells (arrow). Magnification $\times 400$.

and anti-inflammatory activities. These findings paving the road towards its utilization as a protective therapy against lead-associated reproductive anomalies and left the door open in front of further investigations for its mechanistic molecular approaches.

Normal testicular weight is largely dependent on the mass of the differentiated spermatogenic cells that highly correlate with testosterone level (Reshma Anjum and Sreenivasula Reddy 2015). Thus, the decreased relative testicular weight of Lead group of the present study might be explained by the withdrawal of testosterone trophic action and the degenerative histological patterns found in their testicular tissues. The marked reduction of the serum testosterone level in Lead group of the current study was reported previously (Kresovich et al. 2015) and was supported by the presence of degenerated and apoptotic Leydig cells in the histopathological sections of the testis in our study. Inhibition of testicular steroidogenesis biosynthetic enzymes and gonadotropin-releasing hormone (GnRH) and luteinizing hormone (LH) release (Klein et al. 1994; Ji et al. 2015) could be implicated in this outcome response. It is worthy to note the causative involvement of the hypothalamic-pituitary axis, as a major target for lead toxicity, in the testicular degeneration (Doumouchtsis et al. 2009). However, conflict data arise from the literature regarding the modulatory effects of lead on this axis; most probably reflect the variation in dose and duration of exposure (Sokol et al. 2002; Allouche et al. 2009).

Normal spermatogenesis and also normal secretory functions of the testis depend on the normal production of the testosterone hormone that enhances testicular growth and increases the number of spermatogonia and Sertoli cells (Elgawish and Abdelrazek 2014; Reshma Anjum and Sreenivasula Reddy 2015). Hence, decreased testosterone level might be the reason for the observed significant deterioration in semen outcome measures in Lead group of the present study. Our results were in agreement with other studies (Jensen et al. 2006; Reshma Anjum and Sreenivasula Reddy 2015). Other contributory factors involved in the mechanism of lead-induced alteration of parameters of semen analysis include accessory gland dysfunction, cellular nutrition depletion, sperm chromatin condensation disturbance, germ cell DNA fragmentation and necrosis of germinal epithelium and Sertoli cells (Naha and Manna 2007; Shaban El-Neweshy and Said El-Sayed 2011; Haouas et al. 2015).

Lead can cross the blood-testis barrier, accumulate in the testis, and damage germinal cells at various levels of differentiation (Apostoli et al. 1999). This could explain the significantly increased lead concentration noticed in testicular tissue of Lead group *vs.* other groups of the present study.

Administration of lead, in the current study, shifted the oxidant/antioxidant profile towards oxidant side as manifested by the marked exhaustion of the enzymatic antioxidants together with the accumulation of lipid peroxidation product

in the testicular tissue homogenate. This was in corroboration with earlier reports (Ansar et al. 2016; Hasanein et al. 2016). Lead interrupted redox homeostasis through slow clearance of hydrogen peroxide, stimulation of membrane lipid peroxidation, inhibition of delta-aminolevulinic acid dehydratase and upregulation of production and oxidizing potential of oxidant species (Adonaylo and Oteiza 1999a, 1999b; Robinson et al. 2015). The increased oxidative stress was incriminated in playing the main role in the pathogenesis of lead toxicity (Mohammadi et al. 2014). Since the membranes of spermatozoa are rich in polyunsaturated fatty acids, they are vulnerable to oxidative stress damage (Abd-Allah et al. 2016) which might be one of the leading causes of the observed disturbed parameters of semen analysis in Lead group of the present study.

In the current experiment, increased levels of both IL-6 and IL-10 following lead exposure were in the same line with other previous studies (Valentino et al. 2007; Li et al. 2015). Their increased levels indicated the ability of lead to trigger inflammation which might occur in response to increased oxidative stress through activation of NF- κ B (Heeba and Hamza 2015). Interestingly, increased IL-6 could inhibit testosterone production by Leydig cells (Bini et al. 2015). Elevated levels of the anti-inflammatory IL-10 could control inflammation *via* inhibition of activation of immune cells such as macrophages (Sinuani et al. 2013) and prevention of the pathological effects of the inflammatory cytokines (Carrocci et al. 2015). A negative correlation between cytokine levels in the semen and the standard semen parameters was previously reported (Sanocka et al. 2003). Furthermore, an increased level of IL-6 was reported to be present in the semen of infertile men (Camejo 2003) confirming the important role played by these cytokines in the disturbed semen analysis found in Lead group.

Testis of Lead group in the present study showed the presence of severe degenerative and apoptotic changes in harmony with previous studies (Shaban El-Neweshy and Said El-Sayed 2011; Elgawish and Abdelrazek 2014). These histological changes could be related to the damaging effects of the accumulated lead and the increased oxidative stress and inflammatory cytokines recorded in this group. In fact, the primary mechanism by which lead produced cellular damage was found to be through increasing the level of reactive oxygen species which altered the physico-chemical properties of cell membranes and induced protein degradation and DNA damage (Sun et al. 2016b). Moreover, oxidative stress stimulated the progression of inflammation which might end in apoptosis of cells (Hu et al. 2015). This explained the increased apoptotic changes seen in the testis of Lead group of the current study. The reduced level of testosterone, necessary to maintain the normal structure and function of the testis (Abd-Allah et al. 2016), could be also attributed to these histopathological changes. Lead-

induced morphological changes might result in complete arrest of spermatogenesis (Shaban El-Neweshy and Said El-Sayed 2011) which could explain the severely altered semen analysis of this group.

Interestingly, sections of the testis of Lead group in this study showed also an intense nuclear expression of NF- κ B transcription factor in agreement with the findings of Rodriguez-Iturbe et al. (2005). NF- κ B activation in our study might be the result of the increased oxidative stress (Heeba and Hamza 2015). NF- κ B played a central role in inflammation as it triggered the transcription of proteins involved in the inflammatory response (Sun et al. 2016a) as IL-6 (Taniguchi and Karin 2014). This might be a reason for the increased levels of interleukins in Lead group of the present study.

The increased relative testicular weight and serum testosterone level following concurrent administration of FA to lead-challenged rats might be caused by the notable return of the histological structure of the testicular cells towards the normal pattern. Consequently, this group showed an improved sperm quality which was in harmony with the previously reported benefits of FA supplementation on sperm health condition and male fertility (Shalaby et al. 2010; Ibrahim et al. 2011). Low sperm count found in the control rats in comparison with other studies might be related to seasonal and age variations (Guraya 1987). By acting as an essential building block in DNA synthesis and as a dietary antioxidant, FA is considered a central denominator in germ cell development and protection of cellular membrane and DNA from free radical damage (Joshi et al. 2001; Ebisch et al. 2007). The protective effects of FA against lead intoxication might be attributed to its involvement in a large number of biochemical processes, especially remethylation pathway of homocysteine in the testis which is essential for normal spermatogenesis and normal semen parameters (Shalaby et al. 2010). Furthermore, FA reduced the testicular lead accumulation when compared with Lead group. Binding of lead by FA and its increased excretion (Quan et al. 2015) can underlie this effect and contribute to the protective effect of folic acid.

According to the findings of the present study, FA successfully alleviated the SOD, CAT, and GSH-Px depletion and MDA elevation occurred with lead intoxication. This is in agreement with several lines of evidence emerged from other animal models about its broad scope of protection against oxidative damage (Majumdar et al. 2010; Alf rez et al. 2015). The current study revealed also that co-administration FA and lead resulted in attenuation of the inflammation associated with lead administration evidenced by a significant decrease of both IL-6 and IL-10. In line with our results, different experimental studies confirmed the anti-inflammatory effect of FA (Zhao et al. 2013; Tousoulis et al. 2014).

Sections of the testis of rats given FA concurrently with lead intoxication in the current study revealed a markedly improved histological architecture. Similar results were obtained by Shalaby et al. (2010) who used FA against methomyl insecticide in rats. Being antioxidant and anti-inflammatory, FA could protect cells against damage caused by lead administration. FA is important for normal cell multiplication and differentiation processes (Williams et al. 2011), especially during periods of rapid cell division and growth because it is required to synthesize and repair DNA (Ibrahim et al. 2011). Therefore, FA supplementation affected positively spermatogenesis (Forges et al. 2007). The observed anti-apoptotic effects of FA supplementation in the current study was also reported previously (Ajeigbe et al. 2011).

Sections of the testis of FA+Lead group also showed a decreased expression of NF- κ B in comparison with Lead group. This was in agreement with other studies (Au-Yeung et al. 2006; Zhao et al. 2013). The oxidative stability, produced by the supplementation of FA to lead-intoxicated rats of the current study; might be the cause of the downregulation of NF- κ B activation as reported previously (Ebaid et al. 2013). Being a link between oxidative damage and inflammation (Heeba and Hamza 2015), the inhibition of NF- κ B would suppress the inflammatory cascade and the inflammatory cytokines (Ebaid et al. 2013) which explained the anti-inflammatory effect of FA in the present study. Moreover, an earlier study indicated an essential role played by NF- κ B in testicular apoptosis induced by testicular ischemia-reperfusion injury (Minutoli et al. 2009) hence, the downregulation of NF- κ B activation by FA might also explain its observed anti-apoptotic effect.

In conclusion, lead is one of the most attention-commanding heavy metals which altered testicular homeostasis in the present animal model. However, co-administration of FA and lead antagonized its testicular toxicity as reflected on the enhancement of the relative testicular weight and testosterone secretion, alleviation of oxidative stress and inflammatory pathogenic responses together with cytoprotection of the testis and downregulation of NF- κ B signaling pathway.

Acknowledgements. The authors are grateful to Dr. Mahmoud Abd-Elkareem (Anatomy, Histology and Embryology Department, Faculty of Veterinary Medicine, Assiut University, Assiut, Egypt) for his help in the histopathological part of this study.

References

- Abd-Ellah M. F., Aly H., Mokhlis H., Abdel-Aziz A. H. (2016): Quercetin attenuates di-(2-ethylhexyl) phthalate-induced testicular toxicity in adult rats. *Hum. Exp. Toxicol.* **35**, 232–243 <https://doi.org/10.1177/0960327115580602>

- Adonaylo V. N., Oteiza P. I. (1999a): Lead intoxication: antioxidant defenses and oxidative damage in rat brain. *Toxicology* **135**, 77–85
[https://doi.org/10.1016/S0300-483X\(99\)00051-7](https://doi.org/10.1016/S0300-483X(99)00051-7)
- Adonaylo V. N., Oteiza P. I. (1999b): Pb 2+ promotes lipid oxidation and alterations in membrane physical properties. *Toxicology* **132**, 19–32
[https://doi.org/10.1016/S0300-483X\(98\)00134-6](https://doi.org/10.1016/S0300-483X(98)00134-6)
- Aebi H. (1984): Catalase in vitro. *Methods Enzymol.* **105**, 121–126
[https://doi.org/10.1016/S0076-6879\(84\)05016-3](https://doi.org/10.1016/S0076-6879(84)05016-3)
- Ajeigbe K. O., Olaleye S. B., Oladejo E. O., Olayanju A. O. (2011): Effect of folic acid supplementation on oxidative gastric mucosa damage and acid secretory response in the rat. *Indian J. Pharmacol.* **43**, 578–581
<https://doi.org/10.4103/0253-7613.84976>
- Alfárez M. J., Rivas E., Díaz-Castro J., Hijano S., Nestares T., Moreno M., Campos M. S., Serrano-Reina J. A., López-Aliaga I. (2015): Folic acid supplemented goat milk has beneficial effects on hepatic physiology, haematological status and antioxidant defence during chronic Fe repletion. *J. Dairy Res.* **82**, 86–94
<https://doi.org/10.1017/S0022029914000624>
- Allouche L., Hamadouche M., Touabti A. (2009): Chronic effects of low lead levels on sperm quality, gonadotropins and testosterone in albino rats. *Exp. Toxicol. Pathol.* **61**, 503–510
<https://doi.org/10.1016/j.etp.2008.12.003>
- Anis T. H., ElKarasy A., Mostafa T., Gadalla A., Imam H., Hamdy L., Abu el-Alla O. (2007): Chronic lead exposure may be associated with erectile dysfunction. *J. Sex. Med.* **4**, 1428–1436
<https://doi.org/10.1111/j.1743-6109.2007.00587.x>
- Ansar S., AlGhosoon H. T., Hamed S. (2016): Evaluation of protective effect of rutin on lead acetate-induced testicular toxicity in wistar rats. *Toxin Reviews* **34**, 1–5
- Apostoli P., Porru S., Bisanti L. (1999): Critical aspects of male fertility in the assessment of exposure to lead. *Scand. J. Work. Environ. Health* **25**, 40–43
- Au-Yeung K. K. W., Yip J. C. W., Siow Y. L., O K. (2006): Folic acid inhibits homocysteine-induced superoxide anion production and nuclear factor kappa B activation in macrophages. *Can. J. Physiol. Pharmacol.* **84**, 141–147
<https://doi.org/10.1139/Y05-136>
- Bancroft J. D., Gamble M. (2008): *Theory and Practice of Histological Techniques*. 6. Ed. Churchill Livingstone, Philadelphia, PA
- Barbhuiya S. A. S., Sengupta M. (2015): The toxic effects of lead on testicular macrophage immunomodulation and sperm cell parameters in mice. *Br. J. Med. Med. Res.* **9**, 1–10
<https://doi.org/10.9734/BJMMR/2015/17937>
- Bini E. I., D'Attilio L., Marquina-Castillo B., Mata-Espinosa D., Díaz A., Marquez-Velasco R., Ramos-Espinosa O., Gamboa-Domínguez A., Bay M. L., Hernández-Pando R., Bottasso O. (2015): The implication of pro-inflammatory cytokines in the impaired production of gonadal androgens by patients with pulmonary tuberculosis. *Tuberculosis* **95**, 701–706
<https://doi.org/10.1016/j.tube.2015.06.002>
- Bjorndahl L., Soderlund I., Kvist U. (2003): Evaluation of the one-step eosin-nigrosin staining technique for human sperm vitality assessment. *Hum. Reprod.* **18**, 813–816
<https://doi.org/10.1093/humrep/deg199>
- Camejo M. I. (2003): Relation between immunosuppressive Pge(2) and Il-10 to pro-inflammatory Il-6 in seminal plasma of infertile and fertile men. *Arch. Androl.* **49**, 111–116
<https://doi.org/10.1080/01485010390129232>
- Carocci A., Catalano A., Lauria G., Sinicropi M. S., Genchi G. (2016): Lead toxicity, antioxidant defense and environment. *Rev. Environ. Contam. Toxicol.* **238**, 45–67
https://doi.org/10.1007/398_2015_5003
- Doumouchtsis K. K., Doumouchtsis S. K., Doumouchtsis E. K., Perrea D. N. (2009): The Effect of lead intoxication on endocrine functions. *J. Endocrinol. Invest.* **32**, 175–183
<https://doi.org/10.1007/BF03345710>
- Ebaid H., Bashandy S. A., Alhazza I. M., Rady A., El-Shehry S. (2013): Folic acid and melatonin ameliorate carbon tetrachloride-induced hepatic injury, oxidative stress and inflammation in rats. *Nutr. Metab.* **10**, 1743–7075
<https://doi.org/10.1186/1743-7075-10-20>
- Ebisch I. M., Thomas C. M., Peters W. H., Braat D. D., Steegers-Theunissen R. P. (2007): The importance of folate, zinc and antioxidants in the pathogenesis and prevention of subfertility. *Hum. Reprod. Update* **13**, 163–174
<https://doi.org/10.1093/humupd/dml054>
- El-Zohairy E. A., Youssef A. F., Abul-Nasr S. M., Fahmy I. M., Salem D., Kahil A. K., Madkour M. K. (1996): Reproductive hazards of lead exposure among urban Egyptian men. *Reprod. Toxicol.* **10**, 145–151
[https://doi.org/10.1016/0890-6238\(95\)02057-8](https://doi.org/10.1016/0890-6238(95)02057-8)
- Elgawish R. A. R., Abdelrazek H. M. A. (2014): Effects of lead acetate on testicular function and caspase-3 expression with respect to the protective effect of cinnamon in albino rats. *Toxicology Reports* **1**, 795–801
<https://doi.org/10.1016/j.toxrep.2014.10.010>
- Forges T., Monnier-Barbarino P., Alberto J. M., Gueant-Rodriguez R. M., Daval J. L., Gueant J. L. (2007): Impact of folate and homocysteine metabolism on human reproductive health. *Hum. Reprod. Update* **13**, 225–238
<https://doi.org/10.1093/humupd/dml063>
- Gornall A. G., Bardawill C. J., David M. M. (1949): Determination of serum protein by means of the biuret reagent. *J. Biol. Chem.* **117**, 751–766
- Guraya S. S. (1987): *Biology of Spermatogenesis and Spermatozoa in Mammals*. pp. 434. Springer-Verlag Berlin Heidelberg
<https://doi.org/10.1007/978-3-642-71638-6>
- Hamed E. A., Sayyed H. G., Abo-El gait A. T., Galal H. M. (2014): The effect of vitamin E on lead induced gonadal dysfunctions in adult wistar albino rats. *Bull. Egypt. Soc. Physiol. Sci.* **34**, 220–236
- Haouas Z., Zidi I., Sallem A., Bhourri R., Ajina T., Zaouali M., Mehdi M. (2015): Reproductive toxicity of lead acetate in adult male rats: histopathological and cytotoxic studies. *J. Cytol. Histol.* **6**, 1–6
- Hasanein P., Kazemian-Mahtaj A., Khodadadi I. (2016): Bioactive peptide carnosin protects against lead acetate-induced hepatotoxicity by abrogation of oxidative stress in rats. *Pharm. Biol.* **54**, 1458–64
<https://doi.org/10.3109/13880209.2015.1104700>
- Heeba G. H., Hamza A. A. (2015): Rosuvastatin ameliorates diabetes-induced reproductive damage via suppression of

- oxidative stress, inflammatory and apoptotic pathways in male rats. *Life Sci.* **141**, 13–19
<https://doi.org/10.1016/j.lfs.2015.09.015>
- Hu W., Zhou P. H., Rao T., Zhang X. B., Wang W., Zhang L. J. (2015): Adrenomedullin attenuates interleukin-1 β -induced inflammation and apoptosis in rat leydig cells via inhibition of Nf- κ B signaling pathway. *Exp. Cell Res.* **339**, 220–230
<https://doi.org/10.1016/j.yexcr.2015.10.024>
- Hwang S. Y., Siow Y. L., Au-Yeung K. K., House J., Karmin O. (2011): Folic acid supplementation inhibits nadph oxidase-mediated superoxide anion production in the kidney. *Am. J. Physiol. Renal Physiol.* **300**, 189–198
<https://doi.org/10.1152/ajprenal.00272.2010>
- Ibrahim W., Tousson E., Ali E. M., Mansour M. A. (2011): Folic acid alleviates oxidative stress and hyperhomocysteinemia involved in testicular dysfunction of hypothyroid rats. *Gen. Comp. Endocrinol.* **174**, 143–149
<https://doi.org/10.1016/j.ygcen.2011.08.012>
- Jensen T. K., Bonde J. P., Joffe M. (2006): The influence of occupational exposure on male reproductive function. *Occup. Med.* **56**, 544–553
<https://doi.org/10.1093/occmed/kql116>
- Ji X., Li Z., Chen H., Li J., Tian H., Li Z., Gao X., Xiang Q., Su Z., Huang Y., Zhang Q. (2015): Cytotoxic mechanism related to dihydrolipoamide dehydrogenase in leydig cells exposed to heavy metals. *Toxicology* **334**, 22–32
<https://doi.org/10.1016/j.tox.2015.05.003>
- Joshi R., Adhikari S., Patro B. S., Chattopadhyay S., Mukherjee T. (2001): Free radical scavenging behavior of folic acid: evidence for possible antioxidant activity. *Free Radic. Biol. Med.* **30**, 1390–1399
[https://doi.org/10.1016/S0891-5849\(01\)00543-3](https://doi.org/10.1016/S0891-5849(01)00543-3)
- Klein D., Wan Y. J., Kamyab S., Okuda H., Sokol R. Z. (1994): Effects of toxic levels of lead on gene regulation in the male axis: increase in messenger ribonucleic acids and intracellular stores of gonadotrophs within the central nervous system. *Biol. Reprod.* **50**, 802–811
<https://doi.org/10.1095/biolreprod50.4.802>
- Kresovich J. K., Argos M., Turyk M. E. (2015): Associations of lead and cadmium with sex hormones in adult males. *Environ. Res.* **142**, 25–33
<https://doi.org/10.1016/j.envres.2015.05.026>
- Lee J. E., Lim M. S., Park J. H., Park C. H., Koh H. C. (2014): Nuclear Nf- κ B contributes to chlorpyrifos-induced apoptosis through p53 signaling in human neural precursor cells. *Neurotoxicology* **42**, 58–70
<https://doi.org/10.1016/j.neuro.2014.04.001>
- Li N., Liu X., Zhang P., Qiao M., Li H., Li X., Zhang H., Yu Z. (2015): The effects of early life lead exposure on the expression of interleukin (Il) 1beta, Il-6, and glial fibrillary acidic protein in the hippocampus of mouse pups. *Hum. Exp. Toxicol.* **34**, 357–363
<https://doi.org/10.1177/0960327114529451>
- Majumdar S., Maiti A., Karmakar S., Das A. S., Mukherjee S., Das D., Mitra C. (2010): Antiapoptotic efficacy of folic acid and vitamin B12 against arsenic-induced toxicity. *Environ. Toxicol.* **27**, 351–363
<https://doi.org/10.1002/tox.20648>
- Minutoli L., Antonuccio P., Polito F., Bitto A., Squadrito F., Di Stefano V., Nicotina P. A., Fazzari C., Maisano D., Romeo C., Altavilla D. (2009): Mitogen-activated protein kinase 3/ mitogen-activated protein kinase 1 activates apoptosis during testicular ischemia-reperfusion injury in a nuclear factor-kappaB-independent manner. *Eur. J. Pharmacol.* **604**, 27–35
<https://doi.org/10.1016/j.ejphar.2008.12.028>
- Mohammadi F., Nikzad H., Taghizadeh M., Taherian A., Azami-Tameh A., Hosseini S. M., Moravveji A. (2014): Protective effect of zingiber officinale extract on rat testis after cyclophosphamide treatment. *Andrologia* **46**, 680–686
<https://doi.org/10.1111/and.12135>
- Naha N., Manna B. (2007): Mechanism of lead induced effects on human spermatozoa after occupational exposure. *Kathmandu Univ. Med. J.* **5**, 85–94
- Nishikimi M., Rao N. A., Yagi K. (1972): The occurrence of superoxide anion in the reaction of reduced phenazine methosulfate and molecular oxygen. *Biochem. Biophys. Res. Commun.* **46**, 849–854
[https://doi.org/10.1016/S0006-291X\(72\)80218-3](https://doi.org/10.1016/S0006-291X(72)80218-3)
- Ohkawa H., Ohishi N., Yagi K. (1979): Assay for lipid peroxides in animal tissues by thiobarbituric acid reaction. *Anal. Biochem.* **95**, 351–358
[https://doi.org/10.1016/0003-2697\(79\)90738-3](https://doi.org/10.1016/0003-2697(79)90738-3)
- Oyeyemi M. O., Ubiogoro O. (2005): Spermogram and morphological characteristics in testicular and epididymal spermatozoa of large white boar in Nigeria. *Int. J. Morphol.* **23**, 235–239
<https://doi.org/10.4067/S0717-95022005000300008>
- Paglia D. E., Valentine W. N. (1967): Studies on the quantitative and qualitative characterization of erythrocyte glutathione peroxidase. *J. Lab. Clin. Med.* **70**, 158–169
- Pant N., Srivastava S. P. (2003): Testicular and spermatotoxic effects of quinalphos in rats. *J. Appl. Toxicol.* **23**, 271–274
<https://doi.org/10.1002/jat.919>
- Quan F. S., Yu X. F., Gao Y., Ren W. Z. (2015): Protective effects of folic acid against central nervous system neurotoxicity induced by lead exposure in rat pups. *Genet. Mol. Res.* **14**, 12466–12471
<https://doi.org/10.4238/2015.October.16.13>
- Rader J. I., Celesk E. M., Peeler J. T., Mahaffey K. R. (1982): Effect of lead acetate on rats fed diets containing low levels of folic acid. *Drug Nutr. Interact.* **1**, 131–142
- Reshma Anjum M., Sreenivasula Reddy P. (2015): Recovery of lead-induced suppressed reproduction in male rats by testosterone. *Andrologia* **47**, 560–567
<https://doi.org/10.1111/and.12303>
- Robinson S. R., Lee A., Bishop G. M., Czerwinska H., Dringen R. (2015): Inhibition of astrocytic glutamine synthetase by lead is associated with a slowed clearance of hydrogen peroxide by the glutathione system. *Front. Integr. Neurosci.* **9**, 1–8
<https://doi.org/10.1016/j.neuroscience.2014.11.009>
- Rodriguez-Iturbe B., Sindhu R. K., Quiroz Y., Vaziri N. D. (2005): Chronic exposure to low doses of lead results in renal infiltration of immune cells, Nf-kappaB activation, and overexpression of tubulointerstitial angiotensin II. *Antioxid. Redox Signal.* **7**, 1269–1274
<https://doi.org/10.1089/ars.2005.7.1269>

- Sanocka D., Jedrzejczak P., Szumala-Kaekol A., Fraczek M., Kurpisz M. (2003): Male genital tract inflammation: the role of selected interleukins in regulation of pro-oxidant and antioxidant enzymatic substances in seminal plasma. *J. Androl.* **24**, 448–455
<https://doi.org/10.1002/j.1939-4640.2003.tb02693.x>
- Shaban El-Neweshy M., Said El-Sayed Y. (2011): Influence of vitamin C supplementation on lead-induced histopathological alterations in male rats. *Exp. Tox. Pathol.* **63**, 221–227
<https://doi.org/10.1016/j.etp.2009.12.003>
- Shalaby M. A., El Zorba H. Y., Ziada R. M. (2010): Reproductive toxicity of methomyl insecticide in male rats and protective effect of folic acid. *Food Chem. Toxicol.* **48**, 3221–3226
<https://doi.org/10.1016/j.fct.2010.08.027>
- Sinuani I., Beberashvili I., Averbukh Z., Sandbank J. (2013): Role of IL-10 in the progression of kidney disease. *World J. Transplant.* **3**, 91–98
- Sokol R. Z., Wang S., Wan Y. J., Stanczyk F. Z., Gentzsch E., Chapin R. E. (2002): Long-term, low-dose lead exposure alters the gonadotropin-releasing hormone system in the male rat. *Environ. Health Perspect.* **110**, 871–874
<https://doi.org/10.1289/ehp.02110871>
- Sun G. X., Chen Y., Liu C. P., Li S., Fu J. (2016a): Effect of selenium against lead-induced damage on the gene expression of heat shock proteins and inflammatory cytokines in peripheral blood lymphocytes of chickens. *Biol. Trace Elem. Res.* **172**, 474–80
<https://doi.org/10.1007/s12011-015-0602-2>
- Sun H., Wu W., Guo J., Xiao R., Jiang F., Zheng L., Zhang G. (2016b): Effects of nickel exposure on testicular function, oxidative stress, and male reproductive dysfunction in *Spodoptera litura fabricius*. *Chemosphere* **148**, 178–187
<https://doi.org/10.1016/j.chemosphere.2015.10.068>
- Taniguchi K., Karin M. (2014): IL-6 and related cytokines as the critical lynchpins between inflammation and cancer. *Semin. Immunol.* **26**, 54–74
<https://doi.org/10.1016/j.smim.2014.01.001>
- Tousoulis D., Kourkouti P., Briasoulis A., Vogiatzi G., Valatsou A., Pantopoulou A., Oikonomou E., Perrea D., Stefanadis C. (2014): Divergent effects of folic acid administration on inflammatory status and cholesterol levels in apoe deficient mice. *Int. J. Cardiol.* **173**, 608–609
<https://doi.org/10.1016/j.ijcard.2014.03.134>
- Valentino M., Rapisarda V., Santarelli L., Bracci M., Scorcelletti M., Di Lorenzo L., Cassano F., Soleo L. (2007): Effect of lead on the levels of some immunoregulatory cytokines in occupationally exposed workers. *Hum. Exp. Toxicol.* **26**, 551–556
<https://doi.org/10.1177/0960327107073817>
- Williams P. J., Bulmer J. N., Innes B. A., Broughton Pipkin F. (2011): Possible roles for folic acid in the regulation of trophoblast invasion and placental development in normal early human pregnancy. *Biol. Reprod.* **84**, 1148–1153
<https://doi.org/10.1095/biolreprod.110.088351>
- Zemjanis R. (1977): Collection and evaluation of semen. In: *Diagnostic and Therapeutic Techniques in Animal Reproduction*. William and Wilkins company, Baltimore, USA
- Zhao M., Chen Y. H., Dong X. T., Zhou J., Chen X., Wang H., Wu S. X., Xia M. Z., Zhang C., Xu D. X. (2013): Folic acid protects against lipopolysaccharide-induced preterm delivery and intrauterine growth restriction through its anti-inflammatory effect in mice. *PLoS One* **8**, e82713
<https://doi.org/10.1371/journal.pone.0082713>

Received: August 22, 2016

Final version accepted: September 27, 2016