

EXPERIMENTAL STUDY

The effect of diosmin on pancreatic injury induced by hepatic ischemia reperfusion in rats

Serin Kilicoglu S¹, Tanrikulu Y², Kismet K³, Devrim E⁴, Erel S³, Sen Tanrikulu C⁵, Aydogan A³, Tasova V³, Sabuncuoglu MZ³, Kilicoglu B³

Department of Histology and Embriology, Ufuk University Faculty of Medicine, Cankaya, Ankara, Turkey.
kilicoglublulent@yahoo.com

Abstract: *Background:* Hepatic ischemia-reperfusion causes histological injury to the pancreatic cells during transplantation, trauma and emergency surgery. We investigated the effects of diosmin, a phlebotropic drug with antioxidant and antiinflammatory effects, on pancreatic injury in the experimental liver ischemia-reperfusion model. *Materials and methods:* Forty rats were divided into the four groups: sham (Group 1), control (Group 2), peroperative diosmin (50 mg/kg) treatment (Group 3) and preoperative 10-day diosmin (50 mg/kg) treatment group (Group 4). Ischemia-reperfusion model was carried out by clamping the hepatic pedicle for 60 min and then reperfusion of the liver for 90 min. At the end of the procedures, blood and pancreas tissue samples were obtained for biochemical and histopathological assessment.

Results: According to the results of liver function tests, amylase and the plasma and pancreatic tissue oxidative stress parameters, there was a significant difference between the control and other groups. Histopathologically; the specimens of the Group 2 showed specific morphological abnormalities. The groups 3 and 4 showed the pancreas histomorphology similar to the sham group. Pathological scores were significantly different between the Group 2 and other groups.

Conclusions: Diosmin can be administered for a protection of destructive effects of hepatic ischemia-reperfusion injury on pancreas both emergent and elective hepatic surgical operations in which possible ischemic periods were expected (Fig. 1, Tab. 3, Ref. 33). Full Text in PDF www.elis.sk.

Key words: diosmin, liver, ischemia-reperfusion, pancreatic injury.

Hepatic ischemia-reperfusion injury is ordinarily at the time of the repair of extensive liver trauma, shock, tumour resection and liver transplantation (1). Prolonged organ ischemia is characterized by a lack of tissue oxygen. The several situations occur at the lack of tissue oxygen such as adenosine triphosphate (ATP) depletion, derangements in calcium homeostasis, conversion of cellular metabolism to anaerobic pathways, loss of cellular function and cell death. However, once the blood flow is re-established, reperfusion enhances the injury caused by the ischemic period, aggravating the damage caused at the cellular level. Ischemia-reperfusion injury in various organs was recognized as a complex phenomenon. The various factors play a role in the pathogenesis of ischemia reperfusion injury such as increased inflammatory response, reactive oxygen species, cytokine release and neutrophil activation (2, 3).

¹Department of Histology and Embriology, Ufuk University Faculty of Medicine, Cankaya, Ankara, Turkey, ²2nd General Surgery Department, Erzurum Area Training and Research Hospital Yakutiye, Erzurum, Turkey, ³4th General Surgery Department, Ankara Training and Research Hospital Uluçanlar, Ankara, Turkey, ⁴Department of Biochemistry, Ankara University Faculty of Medicine, Cankaya, Ankara, Turkey, and ⁵Emergency Medicine Department, Erzurum Area Training and Research Hospital Yakutiye, Erzurum, Turkey

Address for correspondence: B. Kilicoglu, Ankara Training and Research Hospital General Surgery Department, Uluçanlar, Ankara, 06340, Turkey. Phone: +90.3122044201

There are many techniques for liver inflow occlusion during hepatectomy; continuous or intermittent Pringle manoeuvre is used most frequently (4). The Pringle manoeuvre induces not only a stagnation of the portal venous blood, thereby increasing portal venous pressure, but also an ischemic liver damage. There is an increasing evidence that the changes in the portal circulation during hepatic ischemia reperfusion also causes damages in other organs, such as the intestine, lung, heart (5–7). In addition, an increased portal venous pressure may induce pancreatitis and contribute to mortality (8). Nevertheless, the way how the pancreas responds to congestion and acute elevation of portal venous pressure by portal vein occlusion is not well understood (9, 10).

Furthermore, the relationship between liver resection and hyperamylasemia are examined. Hyperamylasemia is a well-documented sequel of liver surgery, and has been demonstrated following other types of abdominal surgery and even extra-abdominal surgery (5, 6). In addition, hyperamylasemia occurs in the process of an acute pancreatitis and in the postoperative period of various types of surgery, including hepatic surgery (8, 11, 12).

Diosmin is an antioxidant, phlebotropic and vascular protective flavonoid, which increases venous tone, improves lymphatic drainage and reduces capillary hyperpermeability. It also inhibits the activation, migration and adhesion of leukocytes, which leads to a reduction in the release of inflammatory mediators and

thereby a reduction in capillary hyperpermeability. The antioxidant activity of diosmin has been shown in many studies (13–15).

In the present study, we investigated the effects of diosmin on pancreatic injury in the experimental liver ischemia-reperfusion model.

Materials and methods

Animals

Forty Wistar-Albino female rats, weighing 250 ± 30 g, were housed under a constant temperature (21 ± 2 °C) individually in wire cages with 12 h light-dark cycle, fed water and rodent chow ad libitum. Twelve hours before anaesthesia, animals were deprived of food, but had free access to water 2 h before anaesthesia. No enteral or parenteral antibiotics were administered. The procedures in this experimental study were performed in accordance with the National Guidelines for The Use and Care of Laboratory Animals and approved by the Animal Ethics Committee of Ankara Research and Training Hospital.

Study groups and operative procedure

Rats were randomly divided into the four groups each including 10 animals: SHAM group, Control group (ischemia-reperfusion) and treatment groups (peroperative group and preoperative group). Animals were anaesthetized by intramuscular injection of 80 mg/kg ketamine hydrochloride (Ketalar; Parke-Davis, Istanbul, Turkey) and 20 mg/kg xylazine (Rompun, Bayer, Istanbul, Turkey). After the abdomen was shaved and disinfected, a mid-line incision was made and rats underwent either sham surgery or ischemia-reperfusion. Ischemia was carried out by clamping for 60 min with a microvascular “bulldog” clamp of hepatic pedicle. After the ischemic period, liver was reperfused by opening the clamp, and reperfusion was achieved for 90 min. In the peroperative treatment group, diosmin was given to the rats, just after ischemia induction at a dose of 50 mg/kg in gavage form with nasogastric tube; therefore the peak plasma levels of diosmin were achieved before reperfusion was initiated. In the preoperative treatment group, 50 mg/kg/day diosmin (Vendios; Bilim, Istanbul, Turkey) was given to the rats one dose daily for ten days before the operation, in gavage form with nasogastric tube (7 Gauge feeding tube) that was inserted daily and taken off after drug administration.

At the end of the procedures, blood and pancreas tissue samples were obtained for biochemical and histopathological assessment.

Biochemical analyses

Plasma alanine aminotransferase (ALT), aspartate aminotransferase (AST) and amylase levels were measured for evaluating the liver functions by using Olympus Au 640 autoanalyzer. To assess oxidative injury, malondialdehyde (MDA) levels, glutathione peroxidase (GSH-Px) and xanthine oxidase (XO) enzyme activities were determined in the blood samples and malondialdehyde (MDA) levels and glutathione peroxidase (GSH-Px) enzyme activities were determined in the pancreas samples.

Evaluation of oxidative stress

After sacrifice of the animals, pancreas samples were removed and kept on an ice bath until homogenization. The sample of pancreas was first washed with distilled water, the tissues were homogenized in (20 % w/v, approximately 1 g in 5 ml for each) physiological saline, then they were centrifuged $4000 \times g$ for 15 min and upper clear supernatants were used in the assays. All the procedures were performed at $+4$ °C throughout the experiments. Protein level of the clear supernatants was studied by Lowry's method (16), and then they were adjusted to equal concentrations before the other analyses. All the results were expressed as unit/mg protein for those of pancreas tissues. Malondialdehyde (MDA) level (nmol/mg) and glutathione peroxidase (GSH-Px) enzyme activity (mIU/mg) were measured in the supernatants.

MDA level was measured by thiobarbituric acid reactive substances method. GSH-Px activity was measured by following changes in NADPH absorbance at 340 nm.

Histological evaluation

For the light microscopic analyses, the samples obtained from the pancreas were fixed in 10% neutral buffered formaline solution for 2 days. Tissues were washed in flowing water and were dehydrated with rising concentrations of ethanol (50 %, 75 %, 96 %, 100 %). After dehydration, specimens were put into xylene to obtain transparency and were then infiltrated with and embedded in paraffin. Embedded tissues were cut into sections of 5 μ m thickness by Leica RM 2125 RT and stained with hematoxylin and eosin. Histopathologic examinations were performed by two histopathologists, blinded to the study design. Photographs were taken by Olympus BX-51 microscope with Olympus DP-71 photo attachment. The histological grading of edema was made using a scale ranging from 0 to 3 (0 = no edema, 1 = interlobular edema, 2 = interlobular and moderate intralobular edema, and 3 = interlobular edema and severe intralobular edema). Leukocytic infiltration was also graded from 0 to 3 (0 = absent, 1 = scarce perivascular infiltration, 2 = moderate perivascular and scarce diffuse infiltration, 3 = abundant diffuse infiltration). Grading of vacuolization was based on the appropriate percentage of acinar cells involved: 0 = absent, 1 = less than 25 %, 2 = 25–50 % and 3 = more than 50 % of acinar cells. Haemorrhage was graded as: 0 = no haemorrhage, 1 = 1–2 haemorrhagic foci per slide, 2 = 3–5 haemorrhagic foci per slide, 3 = more than 5 haemorrhagic foci per slide. Necrosis was graded as: 0 = no necrosis, 1 = less than 15 % of pancreatic cells involved, 2 = 15–35 % of cells involved, 3 = more than 35 % of cells involved.

Statistical analysis

Data analysis was performed using the SPSS 15.0 package program. Data were presented as the mean \pm standard deviation. Any possible differences among the groups were evaluated by the One-Way ANOVA or Kruskal Wallis variance analysis, where appropriate. When the p-value from the variance analysis was statistically significant, the Mann-Whitney U multiple comparison test was used to know which group differs from the others. Furthermore, the Student's t-test variance analysis was used for

Tab. 1. Liver function tests.

Groups	AST (U/L)	ALT (U/L)	Amylase (U/L) [¶]
SHAM Group	97.60 ± 18.15*	36.60 ± 3.13*	1879.00 ± 184.18**
Control Group	465.60 ± 43.49	201.20 ± 49.49	2119.80 ± 156.00
Peroperative Treatment Group	318.60 ± 108.32 ^{#,¶}	159.40 ± 83.59 [#]	1830.50 ± 353.07 [#]
Preoperative Treatment Group	282.60 ± 38.02 ^{£,µ}	78.40 ± 16.04 ^{£,κ,µ}	1547.50 ± 195.01 ^{£,κ}

Abbreviations: ALT – alanine aminotransferase, AST – aspartate aminotransferase, LDH – lactate dehydrogenase, (*) Amylase results were diluted 5 times, * p < 0.001 and ** p = 0.001 vs control, # p < 0.05 vs control, £ p < 0.001 and vs control, κ p < 0.001 and ** p < 0.05 vs perop.treatment group, (¶) p < 0.001, vs SHAM group, (¶) p < 0.001 vs SHAM group

Tab. 2. Plasma oxidative stress activities of the groups.

Groups	MDA (unit/mL)	GSH-Px (unit/mL)	XO (unit/mL)
SHAM Group	1.72 ± 0.27*	452.06 ± 8.67*	0.51 ± 0.02*
Control Group	3.00 ± 0.88	307.02 ± 6.48	0.65 ± 0.04
Peroperative Treatment Group	1.93 ± 0.12*	377.96 ± 6.51*	0.59 ± 0.04*
Preoperative Treatment Group	1.86 ± 0.43*	424.06 ± 6.93* [#]	0.56 ± 0.01*

Abbreviations: MDA – malondialdehyde, GSH-Px – glutathione peroxidase enzyme activity, XO – xanthine oxidase enzyme activity, * p < 0.05 vs control, # p < 0.001 vs perop. treatment group

the evaluation of the histopathological results. All results were accepted as statistically significant when p < 0.05.

Results

All rats were sacrificed on postoperative day 10. No rat died during the experimental period.

Biochemical analyses

The results of liver function tests of the groups are summarized in the Table 1. There was a significant difference between the SHAM group and the Control group according to the levels of AST, ALT and amylase (p < 0.001 for AST and ALT, p = 0.001 for amylase). There was a significant difference between the Control group and the Peroperative treatment group according to the levels of AST, ALT and amylase (p < 0.05 for all). There was a significant difference between the Control group and the Preoperative treatment group according to the levels of AST, ALT and amylase (p < 0.001 for all). There was a significant difference between the Sham group and the Peroperative treatment group according to the levels of AST (p < 0.001). There was a significant difference between the Sham group and the Peroperative treatment group according to the levels of AST and ALT (p < 0.001 for all). There was no significant difference between the Sham group and the treatment groups according to the levels of amylase. There was no significant difference between the Peroperative treatment group and the Preoperative treatment group according to the levels of AST (p = 0.940). Serum ALT and amylase levels were higher in the Peroperative group than the Preoperative treatment group and the difference was significant (p < 0.001 for AST, p < 0.05 for amylase).

Oxidative stress

The plasma levels of MDA, GSH-Px and XO are summarized in the Table 2. There was a significant difference between the Control group and other groups according to the MDA, GSH-Px and XO levels (p < 0.05 for all). There was not a significant difference between the Peroperative treatment group and the Preoperative treatment group according to the MDA and XO levels (p > 0.05),

Tab. 3. Tissue oxidative stress activities of the groups.

Groups	MDA (nmol/mg)	GSH-Px (mIU/mg)
SHAM Group	0.31 ± 0.07	36.33 ± 17.11
Control Group	0.47 ± 0.13	24.39 ± 5.68
Peroperative Treatment Group	0.32 ± 0.14*	38.21 ± 8.89**
Preoperative Treatment Group	0.31 ± 0.07 [£]	33.46 ± 9.00 [#]

Abbreviations: MDA – malondialdehyde, GSH-Px – glutathione peroxidase enzyme activity, * p < 0.05 and ** p = 0.001 vs control, # p < 0.05 vs control, £ p < 0.05 vs perop. treatment group

GSH-Px levels were higher in the Preoperative treatment group than in the Peroperative treatment group and the difference was significant (p < 0.001). There was not a significant difference between the Sham group and the treatments groups according to the MDA, GSH-Px and XO levels (p > 0.05 for all).

The pancreas tissue levels of MDA and GSH-Px are summarized in the Table 3. There was not a statistically significant difference between the SHAM group and the Control group according to MDA and GSH-Px levels (p > 0.05 for all). There was a statistically significant difference between the Control group and the Peroperative treatment group according to MDA and GSH-Px levels (p < 0.05 for MDA, p = 0.001 for GSH-Px). There was not a statistically significant difference between the Control group and the Preoperative treatment group according to MDA and XO levels (p > 0.05). GSH-Px levels were higher in the Preoperative treatment group than in the Control group and the difference was significant (p < 0.05). There was a statistically significant difference between the Peroperative treatment group and the Preoperative treatment group according to MDA levels (p < 0.05). GSH-Px levels were higher in the Peroperative treatment group than in the Preoperative treatment group and the difference was not significant (p = 0.596).

Histopathological results

The pancreas of the sham operated animals showed no tissue alteration on light microscopy in rats (Fig. 1A). The Control group (ischemia-reperfusion) showed interlobular edema and there was a moderate intralobular edema in four rats. We observed 1–2 hemorrhagic foci per slide (Fig. 1B1). The leukocytic infiltration was

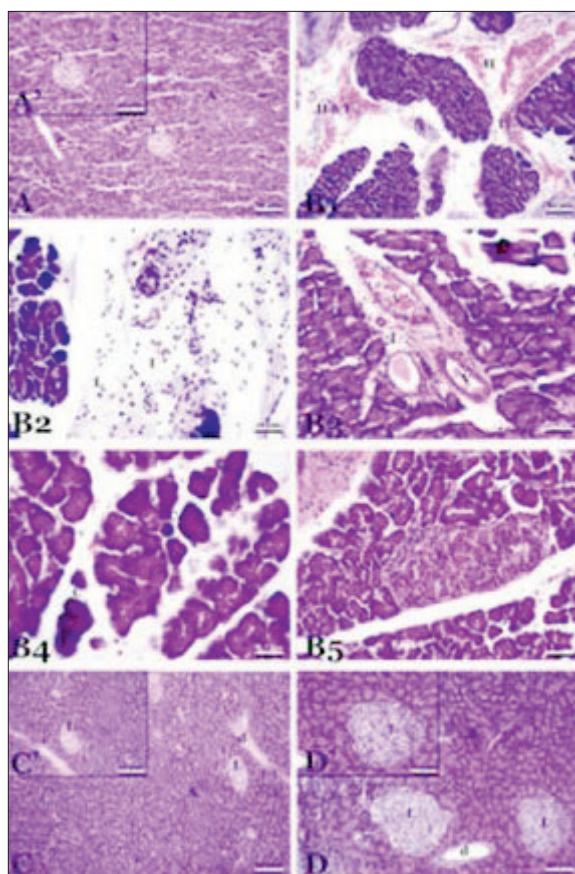


Fig. 1. The micrographs of light microscope stained with haematoxylin and eosin. Micrograph (A) sham group illustrates the typical structure of pancreas with the aciner cells (A) and langerhans islets (L). Micrograph (B 1, 2, 3, 4, 5) ischemia-reperfusion group hemorrhagic foci (H) and inflammation (I) in the interlobular area, lymphocytes (L), neutrophils (N), vessels (V), vacuoles (v), collapsed cells (C). Micrograph C and D treated with diosmin intralobular ductus (d).

moderate in the perivascular region and a diffuse infiltration was scarce (Fig. 1B3). In one focus per slide, the interlobular region was infiltrated with polymorphonuclear leukocytes and lymphocytes (Fig. 1B2). The vacuolization of cells was not remarkable in whole tissue. Only less than 25 % of the acinar cells were vacuolized. The collapsed acinar cells were present in the boundary of the lobules (Fig. 1B4). The Langerhans islets were qualitatively larger in the ischemia-reperfusion group and congestion in the islets' capillaries were remarkable (Fig. 1B5). The treated groups with diosmin (the Peroperative group and the Preoperative group) showed no histological alteration to the ordinary pancreas tissue. There was no histological evidence of leukocyte infiltration, necrosis and/or vacuolization. We observed no perivascular infiltration or edema in the interlobular/intralobular region of the parenchyma (Figs 1C and D).

Discussion

Ischemia reperfusion injury is a complex phenomenon where-by cellular damage in a hypoxic organ is accentuated following the

restoration of oxygen delivery. An interruption of an organ's blood flow, with its subsequent lack of oxygen and nutrient supply, is an inherent phenomenon during diverse surgical procedures. In liver surgery, there are clinical situations in which the ischemic periods can be particularly long, such as during the resection of large hepatic tumours, management of hepatic trauma of diverse origins, vascular reconstructions, and liver procurement for transplantation. Once the blood flow and oxygen supply are re-established, reperfusion enhances the injury caused by the ischemic period, aggravating the damage caused at the cellular level (3, 17).

Ischemia-reperfusion injury is now thought to be the main cause. In the early stages of hepatic reperfusion, endothelial cells swell, vessels constrict, leukocytes become entrapped, and platelets aggregate within sinusoids, resulting in microcirculatory failure. There have also been reports of sinusoids failing to refill and inflammatory cytokine production increasing during the reperfusion period (18, 19).

Hepatic ischemia-reperfusion injury involves interaction between different cell types and a variety of cellular and molecular mechanisms including Kupffer cell activation, formation of reactive oxygen species, release of cytokines and chemokines, and neutrophil recruitment (3).

There is an increasing evidence that changes in the portal circulation during hepatic ischemia reperfusion also causes damages in other organs, such as the intestine, lung, heart (5–7). Furthermore, there are published studies that specifically examine the association between pancreatitis and liver resection. In addition, there are studies that have examined the relationship between liver resection and hyperamylasemia, a biochemical marker of pancreatitis. Hyperamylasemia is a well-documented sequel of liver surgery, and has been demonstrated following other types of abdominal surgery and even extra-abdominal surgery (5, 6). Tsuzuki et al (12) observed hyperamylasemia in 70 (39.5 %) of 177 patients who had undergone hepatectomy for hepatocellular carcinoma or metastatic lesions, but they could not elucidate the mechanism responsible. Miyagawa et al (8) found that significant hyperamylasemia following liver resection was associated with prolonged occlusion of the hepatoduodenal ligament, the Pringle manoeuvre.

Many factors, such as an increased portal venous pressure, ischemic liver damage, and reduced functional liver volume may affect amylase metabolism after hepatectomy. It has been reported that the portal venous stasis associated with liver disease may predispose patients to develop pancreatitis (8, 20). An occlusion of the portal vein results in venous congestion in the pancreas and hyperamylasemia and pancreatitis have been induced in an experimental setting by complete occlusion of the pancreatic veins. A prolonged portal congestion also appears to be another considerable problem to be dealt with. Despite some recent attempts to understand it, the contribution of acute portal congestion to hepatic ischemia-reperfusion injury has not yet been fully clarified (21).

In the present study, we evaluated the biochemical analyses by measuring the plasma AST, ALT and amylase. Diosmin treatment was significantly ameliorates these parameters both in preoperative and peroperatively treated groups.

Oxidative stress most likely plays a major role in the early development of acute pancreatitis and several experimental animal models show a beneficial effect of anti-oxidative drugs. Therapy with antioxidants (such as nitric oxide, tetrandine, L-arginin, allopurinol) administered intravenously has been investigated in a prospective double-blind placebo controlled randomized trial on patients with predicted severe AP but no effect on mortality could be demonstrated. The prophylactic effect on the incidence of post-ERCP pancreatitis was tested in two randomized prospective randomized trials with 256 and 106 patients, respectively. N-acetylcysteine (NAC) was administered before and after ERCP and both studies concluded that NAC was without any preventive effect (22, 23).

Despite advances in experimental studies on the pancreas, the mechanism involved in pancreatic changes resulting in an acute increase of portal pressure secondary to portal venous clamping has not been fully clarified. Aydede et al (24) pointed out that portal bed congestion can trigger an inflammatory response in the pancreas, with a directly proportional relationship between congestion and the changes.

Diosmin is a naturally occurring flavonoid glycoside that can be isolated from various plant sources or derived from the flavonoid hesperidin. Diosmin is considered to be a vascular-protecting agent used to treat chronic venous insufficiency, hemorrhoids, lymphedema, and varicose veins. As a flavonoid, diosmin also exhibits anti-inflammatory, free-radical scavenging, and antimutagenic properties. Diosmin acts by improving venous tone, increasing lymphatic drainage, protecting capillary bed microcirculation, inhibiting inflammatory reactions, and reducing capillary permeability. Micronised purified flavonoid fraction inhibits the activation, migration and adhesion of leukocytes at the capillary level. This leads to a reduction in the release of inflammatory mediators such as oxygen free radicals, prostaglandins and thromboxane, resulting in a decrease in capillary hyperpermeability (25).

Diosmin-hesperidin reported to have radical scavenging properties in the previous reports (26–28). Bouskela et al (29) has found that diosmin-hesperidin prevented the reperfusion injury in hamster cheek pouch ischemia/reperfusion injury model. It was reported that ischemia/reperfusion induced an increase in the microvascular permeability and the leukocyte adhesion was inhibited by diosmin-hesperidin, which is consistent with an improvement in blood flow through the microvascular network. This protective effect might include a decrease in endothelial cell swelling with a consequent decrease in flow resistance. Another possibility for the observed effects of diosmin-hesperidin is its antioxidant effect (29–32). In another study, Pehlivan et al (33) found that diosmin-hesperidin was effective in preventing intestinal reperfusion injury after an oral administration.

In the present study, we investigated the effect of diosmin on pancreas in the hepatic ischemia-reperfusion injury. There was a significant difference between the control and diosmin groups according to the results of amylase and liver function tests.

The groups treated with diosmin (the Peroperative group and the Preoperative group) showed no histological alteration to the ordinary pancreas tissue. There was no histological evidence of leukocyte infiltration, necrosis and/or vacuolization. We observed

no perivascular infiltration or edema in the interlobular/intralobular region of the parenchyma.

In the present study, we evaluated the oxidative stress by measuring the plasma levels of MDA, GSH-Px, XO and pancreas tissue levels of MDA and GSH-Px. Diosmin treatment was also significantly decreased the oxidative stress both in preoperative and peroperatively treated groups.

Conclusion

The present study was the first study about the effect of diosmin on pancreas in the hepatic ischemia-reperfusion injury. When we compared the preoperatively and peroperatively treated groups, better results were achieved in the Preoperatively treated group; but the difference was not statistically significant. According to these results, we concluded that diosmin could be administered for the protection of destructive effects of hepatic ischemia-reperfusion injury on pancreas in both emergent and elective hepatic surgical operations, in which possible ischemic periods were expected.

References

1. **Fondevila C, Busuttil RW, Kupiec-Weglinski JW.** Hepatic ischemia/reperfusion injury – a fresh look. *Exp Mol Pathol* 2003; 74: 86–93.
2. **Suzuki S, Inaba K, Konno H.** Ischemic preconditioning in hepatic ischemia and reperfusion. *Curr Opin Organ Transplant* 2008; 13: 142–147.
3. **Montalvo-Jave EE, Escalante-Tattersfield T, Ortega-Salgado JA, Piña E, Geller DA.** Factors in the pathophysiology of the liver ischemia – reperfusion injury. *J Surg Res* 2008; 147: 153–159.
4. **van Gulik TM, de Graaf W, Dinant S, Busch OR, Gouma DJ.** Vascular occlusion techniques during liver resection. *Dig Surg* 2007; 24: 274–281.
5. **Sathasivam S, Ritchie A, Brooks AJ, Morris DL.** Acute pancreatitis following liver resection: report of three fatal cases and a review of the literature. *ANZ J Surg* 2004; 74: 643–645.
6. **Miyagawa S, Makuuchi M, Kawasaki S, Kakazu T.** Changes in serum amylase level following hepatic resection in chronic liver disease. *Arch Surg* 1994; 129: 634–638.
7. **Tanrikulu Y, Kismet K, Serin Kilicoglu S, Devrim E, Erel S, Sen Tanrikulu C, Dinc S, Edebal OH, Erdemli E, Akkus MA.** Diosmin ameliorates intestinal injury induced by hepatic ischemia reperfusion in rats. *Bratisl Lek Listy* 2011; 112: 545–551.
8. **Miyagawa S, Makuuchi M, Kawasaki S, Kakazu T, Hayashi K, Kasai H.** Serum Amylase elevation following hepatic resection in patients with chronic liver disease. *Am J Surg* 1996; 171: 235–238.
9. **Pringle JH.** V. Notes on the Arrest of Hepatic Hemorrhage Due to Trauma. *Ann Surg* 1908; 48: 541–549.
10. **Man K, Fan ST, Ng IO, Lo CM, Liu CL, Wong J.** Prospective evaluation of Pringle maneuver in hepatectomy for liver tumors by a randomized study. *Ann Surg* 1997; 226: 704–711.
11. **Unalp OV, Aydin U, Yazici P, Nart D, Yenisey C, Kavak T, et al.** The effects of the Pringle maneuver on the pancreas: can octreotide be protective? *JOP* 2009; 10: 284–291.
12. **Tsuzuki T, Shimizu S, Takahashi S, Iio H.** Hyperamylasemia after hepatic resection. *Am J Gastroenterol* 1993; 88: 734–736.

13. **Lyseng-Williamson KA, Perry CM.** Micronised purified flavonoid fraction: a review of its use in chronic venous insufficiency, venous ulcers and haemorrhoids. *Drugs* 2003; 63: 71–100.
14. **Cotelle N, Bernier JL, Catteau JP, Pommery J, Wallet JC, Gaydou EM.** Antioxidant properties of hydroxy-flavones. *Free Radic Biol Med* 1996; 20: 35–43.
15. **Bors W, Heller W, Michel C, Saran M.** Flavonoids as antioxidants: determination of radical-scavenging efficiencies. *Methods Enzymol* 1990; 186: 343–355.
16. **Lowry OH, Rosebrough NJ, Farr AL, Randall RJ.** Protein measurement with folin phenol reagent. *J Biol Chem* 1951; 182: 265–275.
17. **Teoh NC, Farrell GC.** Hepatic ischemia reperfusion injury: pathogenic mechanisms and basis for hepatoprotection. *J Gastroenterol Hepatol* 2003; 18: 891–902.
18. **Serracino-Inglott F, Habib NA, Mathie RT.** Hepatic ischemia-reperfusion injury. *Am J Surg* 2001; 181: 160–166.
19. **Badia JM, Ayton LC, Evans TJ, Carpenter AJ, Nawfal G, Kinderman H et al.** Systemic cytokine response to hepatic resections under total vascular exclusion. *Eur J Surg* 1998; 164: 185–190.
20. **Murata A, Ogawa M, Uda K, Matsuura N, Watanabe Y, Baba T et al.** Release of pancreatic secretory trypsin inhibitor from human hepatoblastoma cells on stimulation with cytokines. *Life Sci* 1988; 43: 1233–1240.
21. **Sjövall S, Holmin T, Evander A, Stenram U.** Splenic and gastroduodenal vein occlusion--influence on the pancreatic gland and on the outcome of experimental pancreatitis. *Int J Pancreatol* 1988; 3 (2–3): 143–149.
22. **Bang UC, Semb S, Nojgaard C, Bendtsen F.** Pharmacological approach to acute pancreatitis. *World J Gastroenterol* 2008; 14: 2968–2976.
23. **Siriwardena AK, Mason JM, Balachandra S, Bagul A, Galloway S, Formela L et al.** Randomised, double blind, placebo controlled trial of intravenous antioxidant (n-acetylcysteine, selenium, vitamin C) therapy in severe acute pancreatitis. *Gut* 2007; 56: 1439–1444.
24. **Aydede H, Erhan Y, Ikgül O, Cilaker S, Sakarya A, Vatansever S.** Effect of portal vein occlusion on the pancreas: an experimental model. *World J Surg* 2006; 30: 1000–1006.
25. **De-Souza DA, Greene LJ.** Intestinal permeability and systemic infections in critically ill patients: effect of glutamine. *Crit Care Med* 2005; 33: 125–135.
26. **Magnotti LJ, Deitch EA.** Burns, bacterial translocation, gut barrier function, and failure. *J Burn Care Rehabil* 2005; 26: 383–391.
27. **Stefanutti G, Pierro A, Parkinson EJ, Smith VV, Eaton S.** Moderate hypothermia as a rescue therapy against intestinal ischemia and reperfusion injury in the rat. *Crit Care Med* 2008; 36: 1564–1572.
28. **Kirimlioglu V, Kirimlioglu H, Yilmaz S, Piskin T, Tekerekoglu S, Bayindir Y.** Effect of steroid on mitochondrial oxidative stress enzymes, intestinal microflora, and bacterial translocation in rats subjected to temporary liver inflow occlusion. *Transplant Proc* 2006; 38: 378–381.
29. **Bouskela E, Cyrino FZ, Lerond L.** Effects of oral administration of different doses of purified micronized flavonoid fraction on microvascular reactivity after ischaemia/reperfusion in the hamster cheek pouch. *Br J Pharmacol* 1997; 122: 1611–1616.
30. **Monograph.** Diosmin. *Altern Med Rev* 2004; 9: 308–311.
31. **Pickelmann S, Nolte D, Leiderer R, Möllmann M, Schütze E, Messmer K.** Effects of the phlebotropic drug Daflon 500 mg on postischemic reperfusion injury in striated skin muscle: a histomorphologic study in the hamster. *J Lab Clin Med* 1999; 134: 536–545.
32. **Korthui RJ, Gute DC.** Anti-inflammatory actions of a micronized, purified flavonoid fraction in ischemia/reperfusion. *Adv Exp Med Biol* 2002; 505: 181–190.
33. **Pehlivan M, Hazinedaroglu SM, Kayaoglu HA, Erkek AB, Keklik T, Canbolat O, et al.** The effect of diosmin hesperidin on intestinal ischaemia – reperfusion injury. *Acta Chir Belg* 2004; 104: 715–718.

Received April 13, 2012.

Accepted December 17, 2012.