

## Determining the extent and stage of disease in patients with newly diagnosed non-Hodgkin's lymphoma using $^{18}\text{F}$ -FDG-PET/CT

T. PAPAĀIK<sup>1</sup>, M. MYSLIVECEK<sup>2</sup>, M. SKOPALOVA<sup>3</sup>, A. MALAN<sup>4</sup>, E. BURIANKOVA<sup>5</sup>, V. KOZA<sup>5</sup>, M. HNATKOVA<sup>6</sup>, M. TRNENY<sup>6</sup>, Z. SEDOVA<sup>1</sup>, Z. KUBOVA<sup>1</sup>, P. KORANDA<sup>2</sup>, P. FLODR<sup>7</sup>, J. JARKOVSKY<sup>8</sup>, L. DUSEK<sup>8</sup>, K. INDRAK<sup>1</sup>

<sup>1</sup>Department of Hemato-Oncology, University Hospital Olomouc and Faculty of Medicine and Dentistry, Palacký University I.P.Pavlova 6, 775 20 Olomouc, Czech Republic, e-mail: tomas.papajik@fnol.cz, <sup>2</sup>Department of Nuclear Medicine, University Hospital Olomouc and Faculty of Medicine and Dentistry, Palacký University Olomouc, <sup>3</sup>PET Center, Na Homolce Hospital Prague, <sup>4</sup>Department of Nuclear Medicine, University Hospital Pilsen, <sup>5</sup>Hematological and Oncological Department, University Hospital Pilsen, <sup>6</sup>Department of Internal Medicine, General University Hospital Prague, <sup>7</sup>Department of Pathology, University Hospital Olomouc and Faculty of Medicine and Dentistry, Palacký University Olomouc, <sup>8</sup>Institute of Biostatistics and Analyses, Masaryk University Brno

Received September 12, 2010

Positron emission tomography (PET) using 2-[fluorine-18]-fluoro-2-deoxy-D-glucose ( $^{18}\text{F}$ -FDG) combined with computed tomography (CT) represents a three-dimensional imaging method suitable for staging in patients with non-Hodgkin's lymphomas (NHLs). The aim of our prospective multicenter study was to assess the value of initial PET/CT as compared with CT and PET alone for determining the stage and extent of the disease. A total of 122 patients with newly diagnosed NHL were examined using PET/CT. Four patients with resected lymphoma lesion and negative PET/CT were therefore excluded from the study. Of the remaining 118 cases, a total of 117 (99%) were described as  $^{18}\text{F}$ -FDG-avid. When compared with PET/CT, CT and PET showed very good sensitivity of lymph node imaging (97% and 100%, respectively); the specificity, however, was significantly lower (66.7% and 94.4%, respectively;  $p=0.0001$ ). When detecting organ lesions, the sensitivity of CT and PET was lower than that of PET/CT (92.5% and 96.3%, respectively;  $p=0.0001$ ); specificity was significantly decreased in CT and a little lower in PET (59.5% and 91.9%;  $p=0.0001$ ). When compared with CT alone, PET/CT changed staging of the disease in 11 patients (9%) and was able to detect a total of 82 discrepancies in 67 of the 117 patients (57%). In conclusion, PET/CT is a new standard in imaging the involvement of lymph nodes and extranodal organs in NHL patients regardless of their histopathological types. Both sensitivity and specificity of the examination are higher than those of CT as well as PET alone.

*Key words:*  $^{18}\text{F}$ -FDG PET – PET/CT – CT – non-Hodgkin's lymphoma – staging

Determination of the stage of the disease, size of the tumor mass and extent of the involvement of other organs plays an important role in selecting adequate therapy in all malignant neoplasms. In patients with non-Hodgkin's lymphomas (NHLs), a prototype of highly chemo- and radiosensitive disease, mapping of the extent of the disease is crucial. Data obtained by this process are key to selecting the intensity and length of chemotherapy (immunochemotherapy) or planning the extent of radiotherapy [1,2]. Individually intensive and prognostically stratified therapy both improves the patients' treatment outcome and survival and lowers the risk of complications and late consequences of the therapy. Precise determination of the disease extent is, however, also important from the point of view of the future evaluation of treatment response, in vast majority of cases based on comparing the disease status prior to initiating and after completing the therapy [3].

Until recently, the gold standard for imaging the involved nodes and extranodal organs was computed tomography (CT). It is capable of identifying changes in the size and shape of the organ shown and describing structurally different lymphoma lesions in normal tissue with a high precision. But CT cannot reveal whether a non-enlarged lymph node is diffusely infiltrated with lymphoma. To an even larger extent, the same problem is true in detecting diffuse infiltration of extranodal organs [1,4]. With the prospects of improving the results of CT scans in detecting lymphoma involvement of organs, there has been an effort to introduce "metabolic detection" of lymphoma tissue into routine examinations. Although scintigraphy using the application of the  $^{67}\text{Ga}$  radioisotope which accumulates in lymphoma cells by binding to transferrin receptors improved CT sensitivity and specificity in many cases, it has not been widely used in practice for initial determination of the disease

stage [5]. This is because the examination is time consuming and technically demanding, positive findings within the organism are often difficult to interpret precisely and the informative value for the abdominal and retroperitoneal regions is low due to physiological uptake of the radioisotope by the intestinal mucosa and poor accumulation of the substance by the cells of low-grade malignant NHLs.

Only the introduction of positron emission tomography (PET) using a fluorine isotope-labeled glucose analog, 2-[fluorine-18]-fluoro-2-deoxy-D-glucose ( $^{18}\text{F}$ -FDG), into the process of determining the stage and extent of lymphoma infiltration of the organism brought a significant positive change [1,5]. The  $^{18}\text{F}$ -FDG PET method makes use of the fact that tumor cells in most NHLs have significantly increased glucose metabolic turnover (increased glycolysis) and, therefore, accumulate the administered  $^{18}\text{F}$ -FDG to a greater extent. Then the sensitive PET system analyzes the metabolic activity of the tissues and helps to decide whether the particular tissue is infiltrated with lymphoma [4]. However,  $^{18}\text{F}$ -FDG is not a solely tumor-specific agent and due to its character, it may be physiologically highly metabolized by certain tissues (brain, cardiac, intestinal) or in the areas of inflammation or other organ damage [6]. To decrease the rates of false-positive results, exact anatomical localizations and correlations with structural images provided by CT scans are used. Therefore, in the recent years, the two modalities have been integrated into a single hybrid PET/CT system capable of precise anatomical and functional localization of pathological lesions, significantly increasing the examination specificity [7,8].

Our prospective multicenter study carried out in three hematology and 3 nuclear medicine centers performing PET/CT scans in the Czech Republic studied the benefit of this method in the initial staging of various types of newly diagnosed and untreated NHLs. The primary aim of the work was to make an independent comparison of CT, PET and PET/CT scans. The secondary endpoint was to assess the value of initial PET/CT as compared with CT and other laboratory and clinical data for determining the stage and extent of the disease.

### Patients and methods

Between September 2007 and March 2009, a total of 122 patients (55 females and 67 males) with newly diagnosed and untreated NHL were indicated for initial  $^{18}\text{F}$ -FDG PET/CT examination. The median age of the group was 59 years (range;

26 – 79 years). In all patients, lymphoma was diagnosed based on two readings of cancer tissue biopsy specimens by two independent pathologists. The second reading was always performed at one of the Czech university departments and the lymphoma specimens were carefully examined immunohistochemically using an antibody panel. In 78 of them, proliferative activity of tumor cells was also assessed using Ki67 antigen expression (clone MIB-1; DakoCytomation Glostrup, Denmark). Staining and scoring were carried out using standard method as previously described [9]. Subsequently, the individual cases were classified according to the WHO Classification of Tumors of Hematopoietic and Lymphoid Tissues. The proportion of individual types of NHLs in the group is shown in Table 1. The disease was staged according to the Ann Arbor system criteria [1]. To determine the stage of the disease, all the necessary usual examinations were carried out. In all patients, blood count with differential and bone marrow tests were performed. The samples were analyzed histopathologically and immunohistochemically from tissue sampled by trephine biopsy from the iliac blade, or immunocytologically (by flow cytometry) from bone marrow aspirate. The basic imaging method for determining the size and extent of lymphoma was  $^{18}\text{F}$ -FDG PET/CT examination. In the case of unclear findings on PET/CT scans or unclear clinical or laboratory findings, the attending physician referred the patient for additional adequate investigations (endoscopy, ultrasound or magnetic resonance imaging), complemented with biopsy of unclear lesions if necessary. The disease was staged by the attending hematologist based on the summary of all available data on the extent and behavior of the patient's tumor.

Prior to their  $^{18}\text{F}$ -FDG PET/CT examination, the patients had to fast (for at least 6 hours) and their blood glucose levels were measured. If the glucose concentration did not exceed 10 mmol/l, 400 MBq of 2-[fluorine-18]-fluoro-2-deoxy-D-glucose ( $^{18}\text{F}$ -FDG) per 70 kg of weight were administered intravenously, with the activity applied being recalculated based on the actual weight. Sixty minutes after the administration of  $^{18}\text{F}$ -FDG and oral administration of a contrast agent and immediately after emptying the urinary bladder by the patient, the PET/CT examination with the Siemens Biograph 16 HI-REZ scanner was initiated. CT scans were carried out after intravenous administration of a nonionic contrast agent, typically from the skull base to the upper third of the thighs with arms upwards. When indicated, the range of scans was modified as needed. The lung region was scanned with patients holding their breath

**Table 1. Comparing the sensitivity and specificity of CT and PET in imaging the involvement of lymph nodes and extranodal organs with consensually evaluated PET/CT complemented with clinical and laboratory data**

		Sensitivity	Specificity	p
Lymph nodes	CT	97.0% (91.4 – 99.4)	66.7% (41.0 – 86.7)	0.0001 (valid for specificity only)
	PET	100.0% (96.3 – 100.0)	94.4% (72.7 – 99.9)	
Extranodal organs	CT	92.5% (84.4 – 97.2)	59.5% (42.1 – 75.2)	0.0001
	PET	96.3% (89.4 – 99.2)	91.9% (78.1 – 98.3)	0.0001

in expiration. This was followed by caudocranial PET scanning with iterative reconstruction of the images. Transmission correction to attenuate gamma radiation was carried out by CT. All CT, PET and PET/CT findings were independently assessed by a radiologist and a nuclear medicine physician. The following groups of lymph nodes were separately assessed in the CT, PET and PET/CT scans: cervical, supraclavicular, axillary, anterior mediastinal, paratracheal, hilar, mesenteric, retroperitoneal, iliac and inguinal. For statistical analysis, the sides were not distinguished in paired groups of nodes. Further, changes in the following organs were studied: the liver, spleen, lung, stomach, intestine, bone, kidney, adrenal, skin, nasal cavity, orbit, brain, spinal cord, thyroid, testis and ovary. If another organ or tissue was involved, it was listed and discussed separately. An abnormal lymph node seen on a CT scan was defined as that with either the long axis exceeding 15 mm or the long axis of 11 – 15 mm and the short axis exceeding 10 mm; in the case of an extranodal organ, changes in its pathological and anatomical properties. A PET-positive finding was defined as a visually evaluated lesion with focal or diffuse accumulation of  $^{18}\text{F}$ -FDG higher than that in the background or structures of mediastinal blood pool, respectively.

As in the other similar studies, not all the pathological findings on CT, PET and PET/CT scans were confirmed by histological examination as such an approach would be both ethically and medically unacceptable. In a previously confirmed diagnosis of NHL, the biopsy of a pathological lesion was decided by the attending physician only if there was a suspicion of two synchronous processes in the particular case which had to be clearly verified. If inflammatory, infectious or other neoplastic diseases were ruled out as the cause of  $^{18}\text{F}$ -FDG accumulation, then every nodal or tissue mass with increased utilization of  $^{18}\text{F}$ -FDG was considered to be infiltrated by lymphoma cells. By contrast, bone marrow involvement was only assessed by immunohistological or immunocytological examination of tissue samples as the opinions on the value of potential detection of bone marrow infiltration by  $^{18}\text{F}$ -FDG PET or PET/CT vary significantly. Moreover, the accumulation of  $^{18}\text{F}$ -FDG in bone marrow may be influenced by numerous other factors such as anemia or activation of hematopoiesis induced by paraneoplastic production of certain cytokines. As a reference standard for comparing the sensitivity and specificity of separate CT and PET examinations, a consensually assessed PET/CT examination with known clinical and laboratory data of the patient was used.

The work was designed as a prospective multicenter study approved by the Multicenter Ethical Committee of the Faculty of Medicine and Dentistry and University Hospital Olomouc and carried out in accordance with the updated principles of the Declaration of Helsinki. The patients gave written informed consent to examination and anonymous data analysis.

The obtained data were processed by standard methods of summary statistics. To compare relative frequencies between two groups, Fischer's exact test was used. To analyze sensitivity and specificity of CT and PET scans alone as compared with PET/CT

examination, ROC (receiver operating characteristic) analysis was performed. Statistical analyses were carried out using the Statistica for Windows 7.1 (StatSoft Inc., 2005) and SPSS 17.0.2 (SPSS Inc., 2003) software applications; the MedCalc 11.1.0.0 software (MedCalc Software, 2009) was used for the ROC analysis.

## Results

A total of 3,172 assessed nodal regions and organs were described independently by 3 ways of imaging (CT, PET and PET/CT scans). That is, a total of 9,516 assessments in 122 included patients were performed. In 119 patients, lymphoma involvement of bone marrow was evaluated (by cytology and histology of bone marrow); in 40 of them (34%), its infiltration by lymphoma cells was confirmed. Forty-seven patients (39%) had B-symptoms (fever, sweats, weight loss) manifested at the disease onset. Stages III and IV were detected in 25 (20%) and 70 (57%) patients, respectively. Three patients with primary nodal diffuse large B-cell lymphoma (DLBCL) had their involved lymph nodes surgically removed and 1 patient with testicular DLBCL had undergone orchiectomy. Since no other PET-positive lesions or significant enlargement of nodes or organs were revealed by their CT scans, they were excluded from further assessment. In 118 patients, utilization of  $^{18}\text{F}$ -FDG by lymphoma tissue was evaluated. Of those, 117 cases (99%) were defined as  $^{18}\text{F}$ -FDG-avid. In one patient with small lymphocytic lymphoma (SLL), the tumor cells did not accumulate the administered  $^{18}\text{F}$ -FDG despite large nodal masses clearly shown in CT scans; therefore, her lymphoma was classified as  $^{18}\text{F}$ -FDG-non-avid. A total of 3 SLL cases were evaluated, with the other 2 patients (66%) accumulating  $^{18}\text{F}$ -FDG. The median value of tumor cell proliferative activity as assessed by the Ki67 antigen was 60% (range; 5 – 100%).

Analysis of the sensitivity and specificity of PET and CT scans alone compared with PET/CT complemented with clinical and laboratory data showed higher sensitivity of PET and PET/CT in comparison with CT in lymph node imaging (Table 1). However, there was no statistical difference between the sensitivity of PET and PET/CT. More significant differences were found in specificity assessment, with especially CT showing significantly lower values than PET/CT ( $p=0.001$ ). Even more significant differences were observed in extranodal organ assessment. Here, CT alone was characterized by a sensitivity of 92.5% and a specificity of only 59.9%. The lowest CT sensitivity was noted when pathological bone lesions were visualized (46%), followed by findings in the liver (60%), stomach (73%) and lung (83%) regions. For CT scans, the lower specificity was seen in abnormalities of the lung (89%) and spleen (84%) regions. The sensitivity and specificity of PET examination alone in the extranodal organ regions were 96% and 92%, respectively. When compared with PET/CT results, the sensitivity and specificity values in both separate methods were statistically significantly lower ( $p=0.0001$ ).

When comparing the findings on PET/CT scans in 117  $^{18}\text{F}$ -FDG-avid patients with CT scans alone, results of

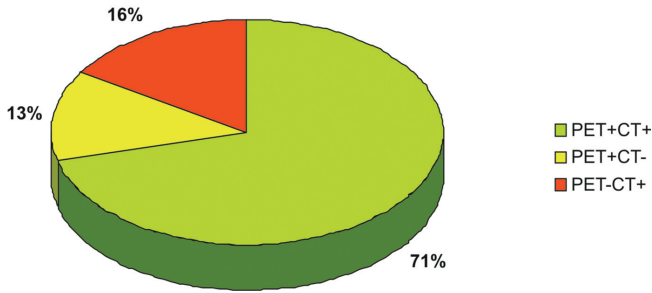


Figure 1. Agreement between <sup>18</sup>F-FDG PET/CT and CT findings in lymph node imaging in 117 patients

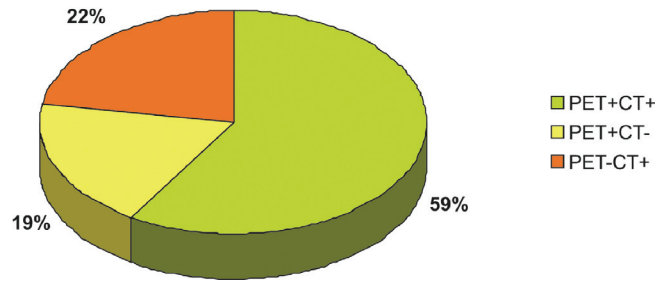


Figure 2. Agreement between <sup>18</sup>F-FDG PET/CT and CT findings in extranodal organ imaging in 117 patients

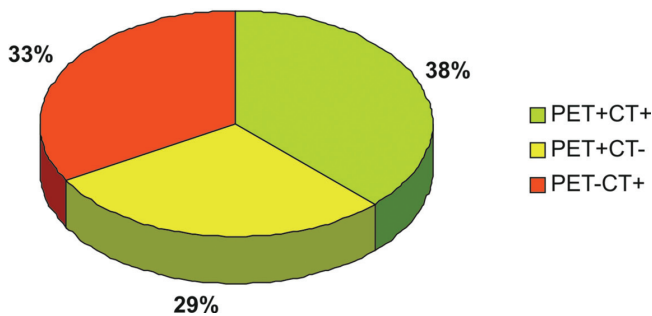


Figure 3. Agreement between <sup>18</sup>F-FDG PET/CT and CT findings in lymph node and extranodal organ imaging in 117 patients

the CT criteria) were found on PET/CT scans that clearly accumulated the administered <sup>18</sup>F-FDG. Most frequently, these were DLBCL patients (8 cases), followed by those with follicular lymphoma (FL; 5 cases), mantle cell lymphoma (MCL; 1 case) and peripheral T-cell lymphoma (PTL; 1 case). In 19 patients (16%), on the other hand, CT scan showed enlarged nodes that did not accumulate <sup>18</sup>F-FDG in PET and PET/CT scans (Figure 1). Once again, these were mostly DLBCL patients (8 cases), followed by those with MCL (4 cases), FL (2 cases), SLL (2 cases) and PTCL, marginal zone lymphoma of MALT type (MZL MALT) and mycosis fungoides (MF) (1 case each).

Similarly, organ involvement was analyzed in detail. In 22 patients (19%), PET and PET/CT scans revealed <sup>18</sup>F-FDG PET-positive organ lesions (with focal or diffuse <sup>18</sup>F-FDG accumulation). However, according to the CT criteria, the visualized organ was not enlarged, or it showed no signs of lymphoma infiltration. Those were 10 DLBCL cases, 6 FL patients, 3 patients with PTCL, 2 cases with MCL and one patient with T-cell lymphoblastic lymphoma (T-LBL). In 22 patients (22%), by contrasts, enlarged organs were found on CT scans (most frequently the enlarged spleen) that did not accumulate the administered <sup>18</sup>F-FDG (Figure 2). These included 11 cases with DLBCL, 5 patients with FL, 3 with MCL, 3 with PTCL, 2 patients with nodal MZL, 1 case with SLL and one with MF.

bone marrow tests and clinical and other available data, the PET/CT examination result alone led to changes in the stage of the disease in 11 patients (9%). The stages were lowered in 6 patients (5%) and increased in 5 patients (4%). The PET/CT results led to modification in the treatment approach only in 3 of 117 patients (3%). Table 2 show more detailed data on patients with PET/CT-changed stages of their disease.

Further, CT, PET and PET/CT findings were compared in detail in the 11 aforementioned nodal regions in 117 patients. In 15 patients (13%), non-enlarged lymph nodes (according to

Table 2. More detailed data on patients in whom PET/CT changed staging of the disease

Patient	Gender	Diagnosis	Change in staging	Stage according to CT (Ann Arbor)	Stage according to PET/CT (Ann Arbor)	Change in therapy
077	Female	Diffuse large B-cell lymphoma	Increase	III	IV	No
118	Female	Diffuse large B-cell lymphoma	Increase	I	III	Yes
023	Male	Peripheral T-cell lymphoma	Increase	III	IV	No
057	Female	Follicular lymphoma	Increase	III	IV	No
097	Female	Follicular lymphoma	Increase	II	IV	Yes
108	Male	Diffuse large B-cell lymphoma	Decrease	IV	III	No
058	Female	Diffuse large B-cell lymphoma	Decrease	IV	III	No
010	Male	Diffuse large B-cell lymphoma	Decrease	III	II	No
112	Male	Nodal marginal zone lymphoma	Decrease	III	II	No
081	Female	Marginal zone lymphoma of MALT type	Decrease	III	II	No
045	Male	Mycosis fungoides	Decrease	IV (EORTC stage)	I (EORTC stage)	Yes

In 34 patients (29%), PET and PET/CT scans showed  $^{18}\text{F}$ -FDG accumulation in lymph node or extranodal organ with no enlargement or other structural changes seen on CT scans. On the other hand, in 39 patients (33%), enlarged lymph nodes or extranodal organs were described in CT scans that showed no increase in  $^{18}\text{F}$ -FDG accumulation on PET and PET/CT scans (Figure 3). When compared with CT, PET/CT scans detected a total of 34 differences in 33 patients in lymph node imaging. When analyzing changes in extranodal scans, 48 differences in 46 patients (39%) were revealed by PET/CT. Thus, a total of 82 discrepancies between PET/CT and CT were described in 67 (57%) of the 117 studied patients. Thirty patients were diagnosed with DLBCL, 16 with FL, 7 with PTCL, 7 with MCL, 3 with MZL, 2 with SLL, 1 with T-LBL and 1 with MF.

In 2 patients, PET scans revealed a pathological lesion identified as inflammatory using PET/CT and clinical and laboratory data. In 1 patient, a lesion sized 29x24x32mm and accumulating  $^{18}\text{F}$ -FDG was found in segment 1 of the right lung. When the CT scans were carefully examined, the lesion was shown to have rough edges and a radiologist expressed a suspicion of tumor duplicity. This was later confirmed by finding non-small squamous cell lung carcinoma in tissue resected by upper lung lobectomy.

When all 3,172 assessed nodal regions and organs were statistically evaluated in 117  $^{18}\text{F}$ -FDG-avid patients, CT is characterized by 2.6% of false-negative and 5.1% false-positive results when compared with PET/CT in the detection of lymph node involvement; PET is characterized by 0% of false-negative and 0.9% of false-positive results. In the case of extranodal organ involvement, CT showed 5.1% of false-negative and 12.8% of false-positive results and PET showed 2.6% of false-negative and 2.6% of false-positive results when compared with PET/CT. The number and characteristics of discrepancies in the nodal regions and extranodal organs (false-positive and false-negative results) were not statistically different with respect to the main types of NHLs represented (DLBCL, FL, PTCL;  $p=0.284$  and  $p=0.678$ , overall  $p=0.071$ ). When discrepancies were evaluated in patients based on proliferative activity according to Ki67 (less than 60% and 60% or more), there were no statistically significant differences in the rates of changes between the two groups ( $p=0.079$  and  $p=0.559$ , overall  $p=0.247$ ).

## Discussion

Precise determination of the stage of the disease, site of the tumor mass and involvement of individual organs is crucial for assessing the prognostic risk and selecting adequate therapy in NHL patients [1]. Numerous studies have shown that  $^{18}\text{F}$ -FDG PET examination is more sensitive and specific than CT and gallium scintigraphy in determining the lymphomatous involvement of individual tissues and organs [10, 11]. The disadvantage of  $^{18}\text{F}$ -FDG PET examination alone is a worse spatial image of the pathological tissue and its structure when compared with CT. Moreover,  $^{18}\text{F}$ -FDG is not a substance

specifically accumulated by tumor tissue only and may be physiologically metabolized by numerous other tissues (brain, cardiac, intestinal) as well as in the areas of inflammation or other organ damage [12, 13]. That is why each  $^{18}\text{F}$ -FDG PET-positive lesion has to be precisely anatomically localized and correlated with a structural image provided by CT examination. The integrated PET/CT method is capable of precise visualization of the structure and localization of a pathological lesion accumulating  $^{18}\text{F}$ -FDG, and of increasing the overall specificity of examination when compared with PET and CT alone. Moreover, CT data are used to correct PET scans for attenuation of the gamma rays by the patient's tissues [7, 8].

Although hybrid PET/CT systems have been used in many countries for more than 7 years, only few research teams carried out prospective studies to assess the benefit of integrated  $^{18}\text{F}$ -FDG PET/CT examination for determining the stage of the disease and involvement of individual organs in newly diagnosed and untreated patients with NHL. In their studies, Hernandez-Maraver, Tatsumi and Ngeow and their colleagues stated that in a significant proportion of patients with NHL and Hodgkin's lymphoma (HL), PET/CT may change the initial stage of the disease (23%, 17% and 17%, respectively) [14-16]. This may be extremely important for the patient as based on this information, the physician may adequately alter the intensity of therapy and increase the hope for CR of the disease. The above-mentioned studies as well as others (le Fougere et al., Fueger et al.) confirmed high sensitivity and specificity of PET/CT examination compared with CT and, in indolent lymphomas, also compared with PET examination alone [17, 18].

In our multicenter, prospective study only 1 SLL patient from 118 assessed ones did not accumulate the administered  $^{18}\text{F}$ -FDG. We know from both the literature and our own experience that in SLL, similarly to chronic lymphocytic leukemia, a significant proportion of cases do not metabolize  $^{18}\text{F}$ -FDG to a larger extent [19]. In the other patients,  $^{18}\text{F}$ -FDG avidity was demonstrated in all cases, regardless of the histological type of NHL. Especially in patients with PTCL and MZL, our data are different from some previously published studies. Elstrom et al. reported sensitivity of  $^{18}\text{F}$ -FDG PET examination in 67% of cases in MZL patients and in only 40% of PTCL patients [20]. In the case of PTCL, however, recent information supports the findings in our cohort, with low  $^{18}\text{F}$ -FDG PET sensitivity (13 – 50%) only in skin T-cell lymphomas or PTCL skin lesions [21]. As for MZL, the latest findings suggest that  $^{18}\text{F}$ -FDG PET sensitivity in nodal MZL is higher than in other forms arising from the mucosa, in particular gastric mucosa. At the same time, the sensitivity of the examination is higher in more advanced stages of the disease. However, even in this case, the published data are not completely consistent [22, 23].

For further analysis, the cohort was reduced to 117 patients whose lymphoma tissue accumulated  $^{18}\text{F}$ -FDG to a larger extent. Generally, the cohort was characterized by a relatively high proportion of advanced stages of the disease, typically in MCL, PTCL, nodal MZL and FL. We consider this one

of the reasons for a lower frequency of changes in staging based on PET/CT (9%) when compared with other cohorts, mostly describing patients with DLBCL and HL [14, 15, 24]. In agreement with the literature, 13% of patients were shown to clearly accumulate the administered  $^{18}\text{F}$ -FDG in the lymph nodes not considered infiltrated with NHL according to CT criteria [15, 25]. The number of findings was even higher in the cases of extranodal organ involvement, with 19% of patients having a demonstrated accumulation of  $^{18}\text{F}$ -FDG in organs with no changes in the structure or size shown by CT. The discrepancies in our cohort are consistent with repeatedly published data [26, 27]. A higher sensitivity of  $^{18}\text{F}$ -FDG PET and PET/CT when compared with CT is currently a clearly demonstrated and widely accepted fact. Studies using PET/CT scans showed that the technique allows precise localization and characterization of even small pathological lesions despite the fact that the sensitivity of PET/CT is not much higher than that of PET [17].

On the other hand, in 16% of patients, enlarged lymph nodes shown in CT scans did not accumulate  $^{18}\text{F}$ -FDG and 22% of patients were found to have clinically significantly morphologically abnormal extranodal organs with no pathological metabolism of the administered substance. Regardless of the type of discrepancy, a higher overall percentage of changes were found in imaging extranodal organs than in lymph nodes. When identifying the types of NHLs in which the discrepancies were found, no significant differences were found in the frequency of changes in the individual histopathological groups of lymphomas or in the group of lymphomas with the Ki67 proliferative activity of less than 60% or 60% and more. Even though this led to changes in staging in only 9% of patients and to modification in the treatment approach only in 3% patients in our cohort, it is important for further approach to patients. In particular if vital organs are involved (the liver, kidneys, bones), such findings may result in adopting many preventive measures to decrease the risk of potential complications of both the disease itself and the administered anti-tumor therapy. This type of information is even more valuable for further follow-up of the patient. The comparison of initial  $^{18}\text{F}$ -FDG PET/CT examination with early findings in the course of treatment and especially the final examination after completed therapy may significantly influence the assessment of the patient's treatment response. This is because many changes may occur in the patient's organism during therapy (inflammation, necrosis, hyperplasia of organs). These make the final interpretation of  $^{18}\text{F}$ -FDG PET/CT difficult and without comparison with the initial examination may lead to misinterpretation and inaccurate assessment of the response of lymphoma to the administered therapy [28, 29]. Moreover, initial  $^{18}\text{F}$ -FDG PET/CT examination may reveal clinically significant and unexpected other findings that may require modification of the therapeutic approach. In our cohort, two patients were found to have a clinically asymptomatic inflammatory lesion and one patient had second primary neoplasm (FL and lung carcinoma). As stated in the previous section,

$^{18}\text{F}$ -FDG PET/CT evaluation of bone marrow involvement was not separately analyzed and the standard methods were biopsy and histopathological examination of tissues (aspiration and immunocytological analysis in some cases). Data on the sensitivity and specificity of  $^{18}\text{F}$ -FDG PET/CT in the detection of bone marrow involvement are markedly different in individual studies [30, 31]. Given the aforementioned findings and the fact that various types of NHLs were evaluated in our cohort, the results might be adversely affected if further detailed analyses were not performed. We plan to evaluate the benefit of  $^{18}\text{F}$ -FDG PET/CT in the assessment of bone marrow infiltration with lymphoma cells should in a separate study.

In conclusion,  $^{18}\text{F}$ -FDG PET/CT examination is becoming a new standard in determining the extent and stage of the disease in patients with NHL. Its sensitivity is significantly higher than that of conventional radiological imaging methods (CT). In particular, the sensitivity of detecting the involvement of extranodal organs by lymphoma has improved significantly thanks to its use. Our prospective multicenter study confirmed the applicability and practical value of the  $^{18}\text{F}$ -FDG PET/CT method as initial imaging examination in the vast majority of NHL types. When comparing CT and  $^{18}\text{F}$ -FDG PET/CT scans, we found a significant number of variations in 57% of the studied patients. Although the findings changed staging of the disease in only 9% of patients and led to a modification in the treatment approach only in 3% patients, we consider them clinically very valuable especially from the point of future assessment of the therapeutic response in patients with NHL.

Acknowledgments. Supported by the Czech Ministry of Health grant project No.NR/9502-3 and grant project of MSMT No. 619 895 9205.

## References

- [1] KWEE TC, KWEE RM, NIEVELSTEIN RAJ. Imaging in staging of malignant lymphoma: a systematic review. *Blood* 2008; 111: 504 – 516. [doi:10.1182/blood-2007-07-101899](https://doi.org/10.1182/blood-2007-07-101899)
- [2] ARMITAGE JO. Staging non-Hodgkin lymphoma. *CA Cancer J Clin* 2005; 55: 368–376. [doi:10.3322/canjclin.55.6.368](https://doi.org/10.3322/canjclin.55.6.368)
- [3] CHESON BD, PFISTNER B, JUWEID ME, GASCOYNE RD, SPECHT L, et al. Revised response criteria for malignant lymphoma. *J Clin Oncol* 2007; 25: 579–586. [doi:10.1200/JCO.2006.09.2403](https://doi.org/10.1200/JCO.2006.09.2403)
- [4] BARENTSZ J, TAKAHASHI S, OYEN W, MUS R, DE MULDER P, et al. Commonly used imaging techniques for diagnosis and staging. *J Clin Oncol* 2006; 24: 3234–3244. [doi:10.1200/JCO.2006.06.5946](https://doi.org/10.1200/JCO.2006.06.5946)
- [5] SEAM P, JUWEID ME, CHESON BD. The role of FDG-PET scans in patients with lymphoma. *Blood* 2007; 110: 3507–3516. [doi:10.1182/blood-2007-06-097238](https://doi.org/10.1182/blood-2007-06-097238)
- [6] BARRINGTON SF, O'DOHERTY MJ. Limitations of PET for imaging lymphoma. *Eur J Nucl Med Mol Imaging* 2003; 30 (Suppl. 1): 117–127. [doi:10.1007/s00259-003-1169-2](https://doi.org/10.1007/s00259-003-1169-2)
- [7] SCHULTHESS GK, STEINERT HC, HANY TF. Integrated PET/CT: Current applications and future directions. *Radiology* 2006; 238: 405–422. [doi:10.1148/radiol.2382041977](https://doi.org/10.1148/radiol.2382041977)

- [8] HANY TF, STEINERT HC, GOERRES GW, BUCK A, VON SCHULTHESS GK. PET diagnostic accuracy: improvement with in-line PET-CT system: initial results. *Radiology* 2002; 225: 575–581. [doi:10.1148/radiol.2252011568](https://doi.org/10.1148/radiol.2252011568)
- [9] MILLER TP, GROGAN TM, DAHLBERG S, SPIER CM, BRAZIEL RM, et al. Prognostic significance of the Ki-67-associated proliferative antigen in aggressive non-Hodgkin's lymphomas: a prospective Southwest Oncology Group trial. *Blood* 1994; 83: 1460–1466.
- [10] THILL R, NEUERBURG J, FABRY U, CREMERIUS U, WAGENKNECHT G, et al. Comparison of findings with 18-FDG PET and CT in pretherapeutic staging of malignant lymphoma. *Nuklearmedizin* 1997; 36: 234–239.
- [11] WIRTH A, SEYMOUR JF, HICKS RJ, WARE R, FISHER R, et al. Fluorine-18 fluorodeoxyglucose positron emission tomography, gallium-67 scintigraphy and conventional staging for Hodgkin's disease and non-Hodgkin's lymphoma. *Am J Med* 2002; 112: 262–268. [doi:10.1016/S0002-9343\(01\)01117-2](https://doi.org/10.1016/S0002-9343(01)01117-2)
- [12] BAKHEET SM, POWE J. Benign causes of 18-FDG uptake on whole body imaging. *Semin Nucl Med* 1998; 28: 352–358. [doi:10.1016/S0001-2998\(98\)80038-X](https://doi.org/10.1016/S0001-2998(98)80038-X)
- [13] SONET A, GRAUX C, NOLLEVAUX MC, KRUG B, BOSLY A, et al. Unsuspected FDG-PET findings in the follow-up of patients with lymphoma. *Ann Hematol* 2007; 86: 9–15. [doi:10.1007/s00277-006-0167-4](https://doi.org/10.1007/s00277-006-0167-4)
- [14] HERNANDEZ-MARAVAR D, HERNANDEZ-NAVARRO F, GOMEZ-LEON N, COYA J, RODRIGUEZ-VIGIL B, et al. Positron emission tomography/computed tomography: diagnostic accuracy in lymphoma. *Br J Haematology* 2006; 135: 293–302. [doi:10.1111/j.1365-2141.2006.06284.x](https://doi.org/10.1111/j.1365-2141.2006.06284.x)
- [15] TATSUMI M, COHADE C, NAKAMOTO Y, FISHMAN EK, WAHL RL. Direct comparison of FDG PET and CT findings in patients with lymphoma: initial experience. *Radiology* 2005; 237: 1038–1045. [doi:10.1148/radiol.2373040555](https://doi.org/10.1148/radiol.2373040555)
- [16] NGEOW JY, QUEK RH, NG DC, HEE SW, TAO M, et al. High SUV uptake on FDG-PET/CT predicts for an aggressive B-cell lymphoma in a prospective study of primary FDG-PET/CT staging in lymphoma. *Ann Oncol* 2009; 20:1543–1547. [doi:10.1093/annonc/mdp030](https://doi.org/10.1093/annonc/mdp030)
- [17] LA FOUGERE C, HUNDT W, BRÖCKEL N, PFLUGER T, HAUG A, et al. Value of PET/CT versus PET and CT performed as separate investigations in patients with Hodgkin's disease and non-Hodgkin's lymphoma. *Eur J Nucl Med Mol Imaging* 2006; 33: 1417–1425. [doi:10.1007/s00259-006-0171-x](https://doi.org/10.1007/s00259-006-0171-x)
- [18] FUEGER BJ, YEOM K, CZERNIN J, SAYRE JW, PHELPS ME, et al. Comparison of CT, PET, and PET/CT for staging of patients with indolent non-Hodgkin's lymphoma. *Mol Imaging Biol* 2009; 11: 269–274. [doi:10.1007/s11307-009-0200-9](https://doi.org/10.1007/s11307-009-0200-9)
- [19] TSUKAMOTO N, KOJIMA M, HASEGAWA M, ORIUCHI N, MATSUSHIMA T, et al. The usefulness of (18)F-fluorodeoxyglucose positron emission tomography ((18)F-FDG-PET) and a comparison of (18)F-FDG-pet with (67)gallium scintigraphy in the evaluation of lymphoma: relation to histologic subtypes based on the World Health Organization classification. *Cancer* 2007; 110: 652–659. [doi:10.1002/cncr.22807](https://doi.org/10.1002/cncr.22807)
- [20] ELSTROM R., GUAN L. BAKER G., NAKHODA K, VERGILIO JA, et al. Utility of FDG-PET scanning in lymphoma by WHO classification. *Blood* 2003; 101: 3875–3876. [doi:10.1182/blood-2002-09-2778](https://doi.org/10.1182/blood-2002-09-2778)
- [21] BISHU S., QUIGLEY J.M., SCHMITZ J., BISHU SR, STEMM RA, et al. F-18-fluoro-deoxy-glucose positron emission tomography in the assesment of peripheral T-cell lymphomas. *Leuk. Lymphoma* 2007; 48: 1531–1538. [doi:10.1080/10428190701344915](https://doi.org/10.1080/10428190701344915)
- [22] KARAM M, NOVAK L, CYRIAC J, ALI A, NAZEER T, et al. Role of fluorine-18 fluoro-deoxyglucose positron emission tomography scan in the evaluation and follow-up of patients with low-grade lymphomas. *Cancer* 2006; 107: 175–183. [doi:10.1002/cncr.21967](https://doi.org/10.1002/cncr.21967)
- [23] ALINARI L, CASTELLUCCI P, ELSTROM R, AMBROSINI V, STEFONI V, et al. 18F-FDG PET in mucosa-associated lymphoid tissue (MALT) lymphoma. *Leuk Lymphoma* 2006; 47: 2096–2101. [doi:10.1080/10428190600733499](https://doi.org/10.1080/10428190600733499)
- [24] DELBEKE D, MARTIN WH, MORGAN DS, KINNEY MC, FEURER I, et al. 2-deoxy-2-(F-18) fluoro-D-glucose imaging with positron emission tomography for initial staging of Hodgkin's disease and lymphoma. *Mol Imaging Biol* 2002; 4: 105–114. [doi:10.1016/S1095-0397\(01\)00058-9](https://doi.org/10.1016/S1095-0397(01)00058-9)
- [25] MOOG F, BANGERTER M, DIEDERICHS CG, GUHLMANN A, KOTZERKE J, et al. Lymphoma: role of whole body 2-deoxy-2-(F-18) fluoro-D-glucose (FDG) PET in nodal staging. *Radiology* 1997; 203: 795–800.
- [26] MOOG F, BANGERTER M, DIEDERICHS CG Extranodal malignant lymphoma: detection with FDG PET versus CT. *Radiology* 1998; 206: 475–481.
- [27] SCHAEFER NG, HANY TF, TAVERNA C, SEIFERT B, STUMPE KD, et al. Non-Hodgkin lymphoma and Hodgkin disease: coregistered FDG PET and CT at staging and restaging – do we need contrast-enhanced CT? *Radiology* 2004; 232: 823–829 [doi:10.1148/radiol.2323030985](https://doi.org/10.1148/radiol.2323030985)
- [28] STRAUSS LG. Fluorine-18 deoxyglucose and false-positive results: a major problem in the diagnostic of oncological patients. *Eur J Nucl Med* 1996; 23: 1409–1415. [doi:10.1007/BF01367602](https://doi.org/10.1007/BF01367602)
- [29] KAZAMA T, FARIA SC, VARAVITHYA V, PHONG-KITKARUN S, ITO H, et al. FDG PET in the evaluation of treatment for lymphoma: clinical usefulness and pitfalls. *Radiographics* 2005; 25: 191–207. [doi:10.1148/rg.251045045](https://doi.org/10.1148/rg.251045045)
- [30] MOOG F, BANGERTER M, KOTZERKE J, GUHLMANN A, FRICKHOFEN et al. 18-F-fluorodeoxyglucose-positron emission tomography as a new approach to detect lymphomatous bone marrow. *J Clin Oncol* 1998; 16: 603–609.
- [31] PAONE G, ITTI E, HAIOUN C, DUPUIS J, LIN C, et al. Bone marrow involvement in diffuse large B-cell lymphoma: correlation between FDG-PET uptake and type of cellular infiltrate. *Eur J Nucl Med Mol Imaging* 2009; 36: 745–750. [doi:10.1007/s00259-008-1021-9](https://doi.org/10.1007/s00259-008-1021-9)