

Immunoelectron microscopy in mycosis fungoides and benign dermatoses. Expression of CD3, CD4 and CD7 receptors.

A. A. GRZANKA¹, W. PLACEK¹, A. GRZANKA², M. SOKOLOWSKA-WOJDYLO³, A. ZURYN²

¹Department of Dermatology and sexually transmitted diseases, Nicolaus Copernicus University, Collegium Medicum in Bydgoszcz, Poland, e-mail: agrzanka@cm.umk.pl, ²Department of Histology and Embryology, Nicolaus Copernicus University, Collegium Medicum in Bydgoszcz, ³ Department of Dermatology, Medical University of Gdańsk

Received February 10, 2009

Mycosis fungoides is an epidermotropic cutaneous T-cell lymphoma (CTCL). Specimens for presented study were taken from sixteen patients with MF confirmed by immunohistochemical methods and PCR and from nine patients with benign dermatoses. To demonstrate CD3, CD4 and CD7 antigens immunogold method was used. We saw morphological differences between lymphocytes from MF and benign dermatoses. In MF, CD3 and CD4 were present rather in form of clusters placed on the surface of cell. On the contrary – CD3 to CD7 distribution analysis showed that these antigens were present rather individually, however there were seen clusters as well. In MF tumor stage labelling decreased in following order: CD7, CD3 and CD4. We also found internalisation of studied antigens via the coated structures of the cell membrane – especially in tumor stage. In benign dermatoses the majority of all receptors was present on the cell membrane. Our work showed differences in localization of studied antigens, between MF stages, what can suggest their possible translocation in cells. We also found loss of CD3 and CD7 antigens in tumor stage what might be use as a diagnosis tool for this disease.

Key words: mycosis fungoides, benign dermatoses, CD3, CD4 and CD7 receptors, immunogold labelling

Mycosis fungoides, the most common form of primary cutaneous T-cell lymphoma (CTCL), is slowly progressive and chronic disease of the skin. It's typically found in adults of 40 – 60 years of age, with man affected by the disorder twice as commonly as women. In early stages of MF patients are showing isolated patches and plaques. As the disease develops, more symptoms are present, including tumors, involvement of blood and lymph node. In final stage, visceral disease occurs. Obviously, survival rate is decreasing with development of the disease: from stage IA – where it appears to be the same as for the rest of the population, to IVB stage (visceral involvement), where the median survival is only 2.5 years or less. Treating of the disease includes topical corticosteroids, phototherapy, topical chemotherapy, radiotherapy, retinoids (in IA to IIB stages) and systemic chemotherapy. Modern therapy for cutaneous T-cell lymphoma is based on the cellular and molecular pathways involved in the pathogenesis of CTCLs includes monoclonal antibodies and biological response modifiers (in IIB to IV stages) [1]. Recently it was reported that the use of allogenic stem cell transplantation can cause long-term durable remissions of more than 3 years in case of patients with CTCL [2].

MF can be characterized by skin being epidermotropically infiltrated with small or medium-sized lymphocytes with cerebriform nuclei. Malignant cells are forming clusters which can be seen in epidermis and papillary dermis and admixture of reactive inflammatory cells is present in the infiltrate. The early diagnosis of MF may cause difficulties, not only because of the fact that there are few malignant cells, but especially by MF histopathologic similarity to benign inflammatory diseases and it's usually necessary to perform multiple biopsies to establish a definite diagnosis. During MF's progression to tumor stage, the proportion and tumor cells size increases and epidermotropism decreases [3, 4]. In MF the tumor cells express a mature T-helper memory phenotype, ie. CD3⁺, CD4⁺, CD8⁻ CD45RO⁺ with a T-cell receptor (TCR) of the α/β heterodimer [5]. CD7 is expressed on about 90% of CD4 T cells [6]. This antigen is involved in signal transduction and may function as an adhesion molecule during T-cell activation [7, 8]. Loss of CD7 expression in neoplastic lymphocytes is considered as a distinguish characteristic of mycosis fungoides (MF) and cutaneous T-cell lymphoma. There are some studies showing that CD7 recep-

tors may be valuable in the diagnosis between inflammation and neoplasia in lymphoproliferative skin disorders [6, 9–11]. In our previous studies we described the expression of CD3 and CD4 antigens on lymphocytes in patients with mycosis fungoides by immunogold method at the ultrastructural level. We demonstrated the close localization of CD3 and CD4 antigens in clusters in this study and we were able to conclude the relation in distribution between both studied antigens [12]. In the literature there are not any reports on distribution at the ultrastructural level above mentioned antigens but results on evidence that CD3 and CD4 complex interacts both physical and functionally on T-cell were published [13–18]. The ultrastructural studies not only visualized the pattern of distribution and relationship between antigens but might also suggest their possible translocation in studied cells what let us to gather more information to understand the biology of mycosis fungoides. Our present study enhances knowledge about the distribution of CD3 to CD4 and additionally to CD7 antigens in patients with MF (patch, plaque and tumor stages) and benign dermatoses.

Materials and methods

Specimens were taken from sixteen patients with Mycosis fungoides confirmed by immunohistochemical methods and PCR (4 in patch, 9 in plaque stage and 3 in tumor stage) and from nine patients with benign dermatoses (lichen planus, eczema, psoriasis). Samples were fixed with 4% paraformaldehyde in PBS for 1 h at 4°C. For conventional electron microscopy to estimate the morphology, cell were fixed with 3,6% glutaraldehyde in phosphate buffer, postfixated in OsO₄ in the same buffer and after dehydration with alcohol embedded in Epon 812. Thin sections were stained with uranyl acetate and lead citrate.

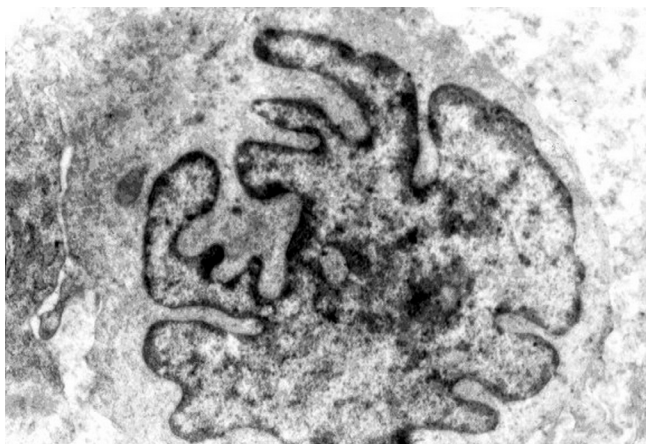

Fig. 1. Electron micrographs of MF lymphocytes with big, cerebriform shaped nucleus occupying nearly whole area of the cell (magnification X 20000).

Using double gold labeling method for ultrastructural study 10nm gold particles were used for CD3 and 20nm gold particles for CD4 and CD7 antigens respectively. After fixation samples were washed overnight in PBS at 4°C. Dehydration was performed in an ascending series of ethanol and embedded in LR White. Sections were cut at 60 nm and placed on nickel grids. The grids were incubated with RTU-CD3 antibody (Novocastra). After incubation with primary antibodies for 30 minutes, the thin sections on grids were rinsed in PBS. Then were exposed to biotinylated rabbit anti-mouse immunoglobulins (Dako) diluted 1:100 and again washed in PBS. Afterwards, the grids were transferred onto drops of 1:50 dilution of 10 nm gold particles conjugated to streptavidin (SIGMA) and incubated for 30 min. After the grids were dried, the procedure was repeated on the other side of the grids. The sections were then incubated with RTU-CD4 or CD7 antibody (Novocastra) and 20 nm gold/streptavidin particles (SPI Supplies). All incubation steps were performed at room temperature. Control specimens were incubated with nonimmune antiserum (normal mouse serum, DAKO). The preparations were examined using a transmission electron microscope JEM 100 (JEOL, Tokyo, Japan).

The project was approved by CM UMK ethics committee, No. KB/196/2004.

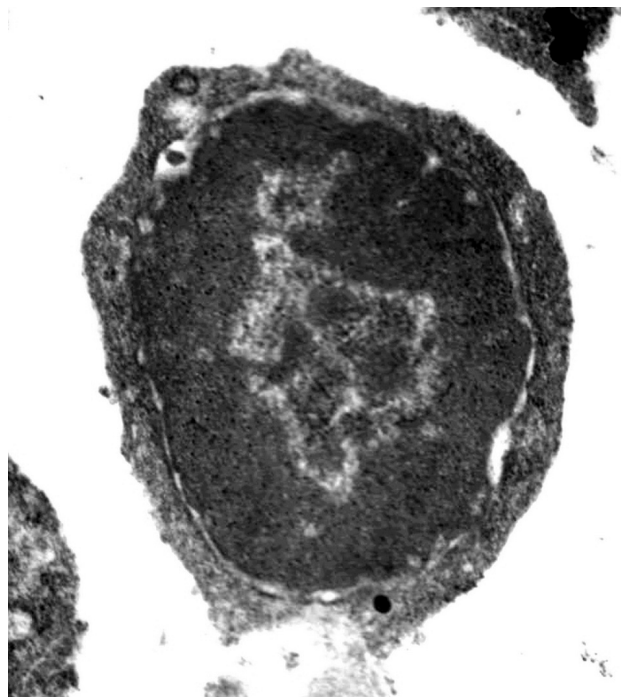

Fig. 2. Electron micrograph of benign dermatoses lymphocyte with characteristic rounded shaped nucleus and narrow rim cytoplasm. Control reaction with normal mouse serum instead of primary antibodies (magnification X 27000).

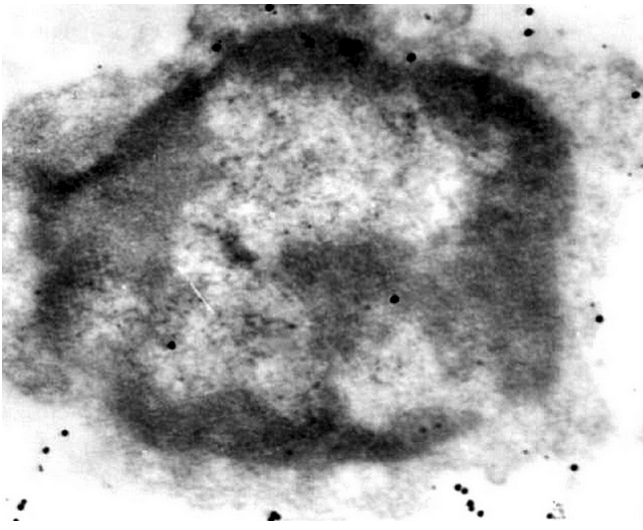


Fig. 3. Inflammatory T-cell with double gold labelling of CD3 and CD4 antigens. They are present in form of clusters on the plasma membrane and some of the single particles in the cytoplasm and nucleus (magnification X 30000).

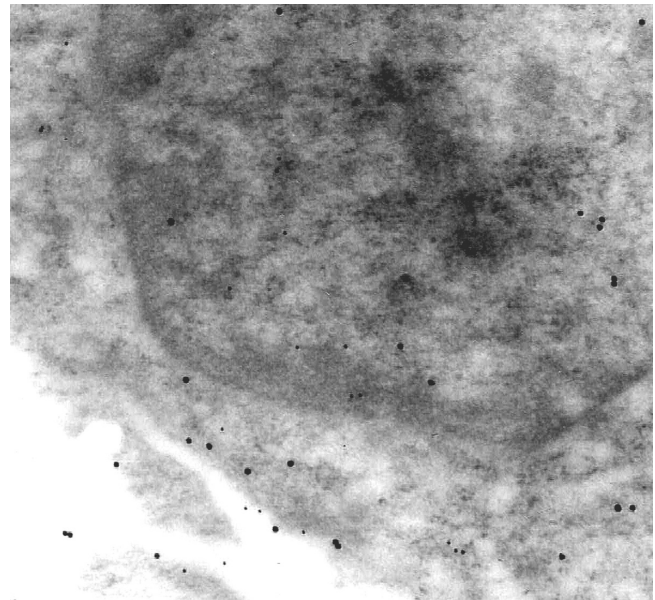


Fig. 4. MF with double gold labelling of CD3 and CD7 antigens showed more individual CD3 and CD7 receptors but there were also seen clusters only composed of small or big gold particles in all stages (magnification X 38000).

Results

Here we studied distribution of CD3 antigen to CD4 and CD7 in samples taken from patients with mycosis fungoides with patch, plaque and tumor stage and also in benign inflammatory diseases at the electron microscopy. Morphological analysis of mycosis fungoides samples at the ultrastructural level showed atypical malignant lymphocytes with big, cerebriform shaped nucleus occupying nearly whole area of the cell (Fig. 1). Instead, in samples taken from patients with benign dermatoses, lymphocytes were smaller and had characteristic rounded shaped nucleus and narrow rim cytoplasm (Fig. 2). The expression of studied antigens was found on all lymphocytes in mycosis fungoides and benign dermatoses at the ultrastructural level. The antigens were present on cell membrane but there were also gold particles inside cell. The results of present studies, regarding CD3 and CD4 distribution in MF, were similar to our previous work, which focused only on plaque stage. Here, the CD3 and CD4 antigens in patch and plaque stages and also of inflammatory T- cells were present rather in form of clusters of both antigens, placed on the surface of cell than as single particles along the plasma membrane (Fig. 3). Instead, the mycosis fungoides cells labelled for CD3 and CD7 antigens showed more individual CD3 and CD7 receptors but there were also seen clusters only composed of small or big gold particles in all stages (Fig. 4). In our studies in some cases especially of tumor stage we observed internalisation of studied antigens via the coated structures of the cell membrane (Fig. 5a-d). In tumor stage we also noted decrease labelling of CD7, CD3 and CD4 antigens respectively and more

gold particles for all antigens in cytoplasm and nucleus than on plasma membrane (Figs 6–7). These studies showed bigger expression of CD4, than CD3 and CD7 receptors on plasma membrane not only of mycosis fungoides in patch and plaque stages but also of inflammatory T- cells (Fig. 3, 4). In relation to malignant T- cells benign dermatoses cells were characterized by presence of all receptors first of all on the cell membrane. Labelling of CD3, CD4 and CD 7 antigens was not found in control cells incubated with non-immune serum (Fig. 2).

Discussion

Cutaneous T-cells Lymphomas (CTCL) are characterized by loss of some surface antigens such as CD7 or CD26 and others like CD2, CD3, CD5 [19–20]. Atypical expression of T-cell surface markers still needs more studies especially that it can be useful as additional method to diagnose CTCL. The purpose of this study was to characterize the localization of CD3 to CD4 and CD7 antigens in biopsy samples of all stages of mycosis fungoides and benign dermatoses at the ultrastructural level. This report is a continuation of our previous study on expression of CD3 and CD4 receptors in samples taken from patients with mycosis fungoides in plaque stage [12]. That study at the ultrastructural level showed close localization of both receptors, which were often forming clusters. In the present work, the evaluation at the ultrastructural level also showed close localization of both receptors in all stages of MF and benign dermatoses, what seems to confirm our previous and other authors results, regarding the existing relations between them [13–16, 18, 21]. The data regarding

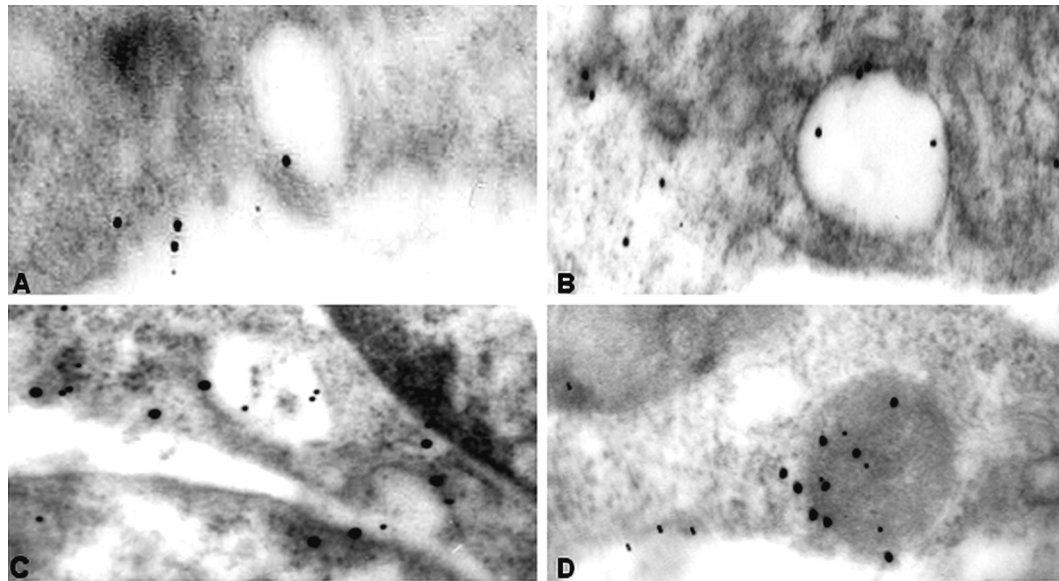


Fig. 5a,b,c,d. Fragments of MF cells with areas containing gold particles labelling antigens CD4 (a-b); CD3 and CD7 (c); CD3 and CD4 (d); magnification X 38000 (a, d); X 36000 (b); X39000 (c).

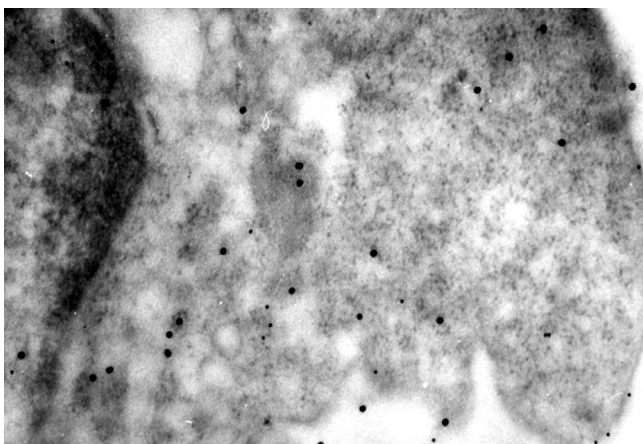
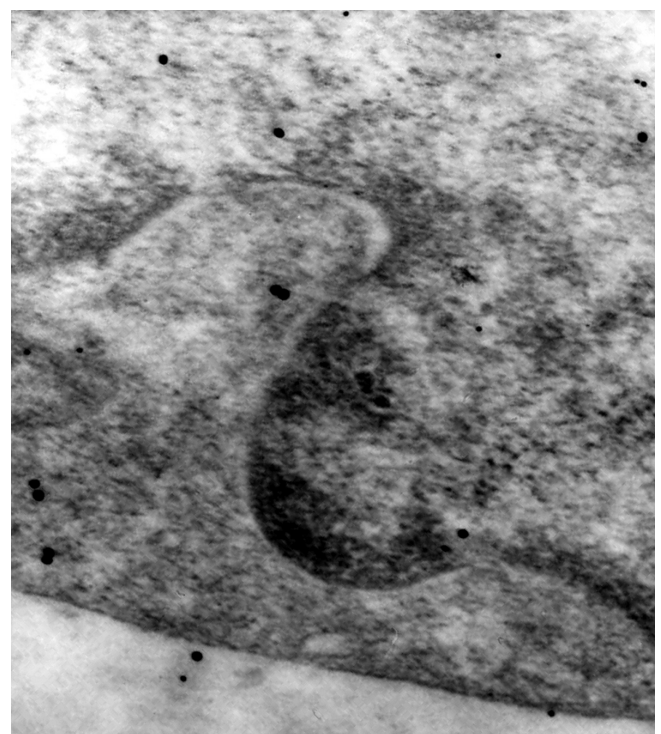

Fig. 6,7. Electron micrograph of tumor stage MF cell showing singular gold particles on the plasma membrane and numerous in the cytoplasm, labelling of CD3 and CD4 (Fig. 6); CD3 and CD7 (Fig.7); magnification X 40000 (Fig.6); X 40000 (Fig.7).



lower CD3 to CD4 receptors expression, obtained by us, are also similar to other authors, who proved smaller expression of CD3 receptors on lymphomas T-cells. [17, 22]. Besides that Edelman et al. showed correlation between CD3 antigen low expression and morphology of mycosis fungoides [23]. Our present work was expanded to CD7 antigen. We found that patients with MF in tumor stage showed loss of CD3 and CD7, to those in patch and plaque stages and to patients with

benign dermatoses. There are other reports on lower expression of CD7 [1, 24–27]. Most of authors state that deficiency of this antigen can represent a tool for diagnosis of MF [1, 6,

10]. This also includes reports from Murphy et al. concluding that minimal CD7 expression is typical for MF [9] and Prince et al. suggesting that CD7 absence can be treated as one of prognostic factors for MF [1]. However, Alaibac et al. claim that CD7 deletion cannot be fully reliable for diagnosis, as it is too common for both benign and neoplastic skin infiltrates [11] and Vonderheid points out that regardless of the cause, it is expected from CD7 deficient cells to accumulate in chronically inflamed skin and it might be a persistent nature of MF lesions responsible for lower CD7 expression [25].

On the basis of our present and previous studies we can conclude that T-cells in MF express more CD4 receptor than CD3 and CD7, what is in agreement with studies of Harmon et al. and others [20, 23, 28–29]. We present more CD4 receptors and only single CD3 and CD7 antigens on cells of the patients with tumor stage. Our study provides also evidence of CD3, CD4 and CD7 antigens internalisation through coated vesicles, what can be one way of losing receptors from surface of MF cells. Internalisation of CD4 receptors on human T-cells was demonstrated by Wang et al. [30]. They found endocytotic vesicles and vacuoles of diverse sizes and shapes near the cell membrane, or deep in the cell centre, to contain CD4 antigen. There were also reports that TCR/CD3/CD4 complexes after internalisation don't degenerate completely and may return to the cell surface [4]. Immunolabelling, observed in our present work, may give indirect evidence to this mechanism of receptors translocation. This loss of antigens from the cell surface may weaken the effect of therapy which is based on drug–antigen binding [31]. Their increased numbers inside MF tumor stage cells can be caused by the disorder of their synthesis or by increased endocytosis. There is a possibility that this “hiding” of TCR/CD3 receptors in malignant cells has influence on disorder in signal transferring in cell, which may cause lack of balance between proliferation and apoptosis of these cells.

Similar observations were made by Pelchen-Mattews et al. studying endocytosis of the T cell differentiation antigen CD4 in lymphocytic and nonlymphocytic cells. With the use of electron microscopy analysis, they examined CD4 distribution and demonstrated that immunogold particles labelling CD4 enter cells through coated pits [32].

In conclusions we found that in tumor stage, CD3, CD4 and CD7 antigens are present more often inside the cell, which may be related to increased endocytosis of these receptors and hence there is a possibility of that phenomenon's connection to loss of those receptors from the cell membrane. Our studies on the ultrastructural level not only visualised the pattern of distribution and relationship between CD3 and CD4 or CD7 antigens but might also suggest their possible translocation in mycosis fungoides cells. Since those are the very first observations, they need to be confirmed with the use of additional methods. Presented studies will be continued and supported by observations of new clinical cases.

Acknowledgment. The work was supported by the Nicolaus Copernicus University, Collegium Medicum (grant SD 68/04)

References:

- [1] PRINCE HM, MCCORMACK C, RYAN G, O'KEEFE R, SEYMOUR F, et al. Management of the primary cutaneous lymphomas. *Australas J Dermatol* 2003; 44: 227–242. [doi:10.1046/j.1440-0960.2003..x](https://doi.org/10.1046/j.1440-0960.2003..x)
- [2] DUARTE RF, SCHMITZ N, SERVITJE O, SUREDA A. Haematopoietic stem cell transplantation for patients with primary cutaneous T-cell lymphoma. *Bone Marrow Transplant* 2008; 41: 597–604. [doi:10.1038/sj.bmt.1705968](https://doi.org/10.1038/sj.bmt.1705968)
- [3] WILLEMZE R, KERL H, STERRY W, BERT E., CERRONI L. et al. EORTC classification for primary cutaneous lymphomas: A proposal from the cutaneous lymphoma study group of the European Organization for Research and Treatment of Cancer. *Blood* 1997; 90: 354–371.
- [4] KARENKO L, HAHTOLA S, RANKI A. Molecular cytogenetics in the study of cutaneous T-cell lymphomas (CTCL). *Cytogenet Genome Res* 2007; 118: 353–361. [doi:10.1159/000108320](https://doi.org/10.1159/000108320)
- [5] MICHIE SA, ABEL EA, HOPPE RT, WARNKE EA, WOOSD GS. Expression of T-cell receptor antigens in mycosis fungoides and inflammatory skin lesions. *J Invest Dermatol* 1989; 93: 116–120. [doi:10.1111/1523-1747.ep12277376](https://doi.org/10.1111/1523-1747.ep12277376)
- [6] COTTA AC, CINTRA ML, DE SOUZA EM, CHAGAS CA, MAGNA LA, et al. Diagnosis of mycosis fungoides: a comparative immunohistochemical study of T-cell markers using a novel anti-CD7 antibody. *Appl Immunohistochem Mol Morphol* 2006; 14: 291–295. [doi:10.1097/00129039-200609000-00006](https://doi.org/10.1097/00129039-200609000-00006)
- [7] CHAN AS, REYNOLDS PJ, SHIMIZU Y. Tyrosine kinase activity associated with the CD7 antigen: correlation with regulation of T cell integrin function. *Eur J Immunol* 1994; 24: 2602–2608. [doi:10.1002/eji.1830241106](https://doi.org/10.1002/eji.1830241106)
- [8] REINHOLD U, LIU L, SESTERHENN J, ABKEN H. CD7-negative T cells represent a separate differentiation pathway in a subset of post-thymic helper T cell. *Immunology* 1996; 89: 391–396. [doi:10.1046/j.1365-2567.1996.d01-744.x](https://doi.org/10.1046/j.1365-2567.1996.d01-744.x)
- [9] MURPHY M, FULLEN D, CARLSON JA. Low CD7 expression in benign and malignant cutaneous lymphocytic infiltrates: experience with an antibody reactive with paraffin-embedded tissue. *Am J Dermatopathol* 2002; 24: 6–16. [doi:10.1097/00000372-200202000-00002](https://doi.org/10.1097/00000372-200202000-00002)
- [10] ORMSBY A, BERGFELD WF, TUBBS RR, HIS ED. Evaluation of a new paraffin-reactive CD7 T-cell deletion marker and a polymerase chain reaction-based T-cell receptor gene rearrangement assay: implications for diagnosis of mycosis fungoides in community clinical practice. *J Am Acad Dermatol* 2001; 45: 405–413. [doi:10.1067/mjd.2001.116342](https://doi.org/10.1067/mjd.2001.116342)
- [11] ALAIBAC M, PIGOZZI B, BELLONI-FORTINA A, MICHELOTTO A, SAPONERI A, et al. CD7 expression in reactive and malignant human skin T-lymphocytes. *Anticancer Res* 2003; 23: 2707–2710.
- [12] A. Immunogold detection of CD3 and CD4 antigens in patients with Mycosis fungoides. *Neoplasma* 2006; 53: 424–427.

- [13] JULIUS M, MAROUN CR, HAUGHN L. Distinct roles for CD4 and CD8 as co-receptors in antigen receptor signalling. *Immunol Today* 1993; 14: 177–183. doi:10.1016/0167-5699(93)90282-P
- [14] VIGNALI DA, CARSON RT, CHANG B, MITTLER RS, STROMINGER JL. The two membrane proximal domains of CD4 interact with the T cell receptor. *J Exp Med* 1996; 183: 2097–2107. doi:10.1084/jem.183.5.2097
- [15] COLLINS TL, UNIYAL S, SHIN J, STROMINGER JL, MITTLER RS, et al. p56lck association with CD4 is required for the interaction between CD4 and the TCR/CD3 complex and for optimal antigen stimulation. *J Immunol* 1992; 148: 2159–2162.
- [16] ANDERSON P, BLUE ML, SCHLOSSMAN SE. Comodulation of CD3 and CD4. Evidence for a specific association between CD4 and approximately 5% of the CD3: T cell receptor complexes on helper T lymphocytes. *J Immunol* 1988; 140: 1732–1737.
- [17] CHUCK RS, CANTOR CR, TSE DE. CD-4-T-cell antigen receptor complexes on human leukemia T cells. *Proc Natl Acad Sci USA* 1990; 87: 5021–5025. doi:10.1073/pnas.87.13.5021
- [18] RIVAS A, TAKADA S, KOIDE J, SONDERSTRUP-MCDEWITT G. et al. CD4 molecules are associated with the antigen receptor complex on activated but not resting T cells. *J Immunol* 1988; 140: 2912–2918.
- [19] BERNENGO MG, NOVELLI M, QUAGLINO P, LISA F, DEMATTEIS A, et al. The relevance of the CD4+, CD26- subset in the identification of circulating Sezary cells. *Br J Dermatol* 2001; 144: 125–135. doi:10.1046/j.1365-2133.2001.04014.x
- [20] WOOD GS, HONG SR, SASAKI DT, ABEL EA, HOPPE RT, et al. Leu-8/CD7 antigen expression by CD3+ T cells: comparative analysis of skin and blood in mycosis fungoides/Sézary syndrome relative to normal blood values. *J Am Acad Dermatol* 1990; 22: 602–607. doi:10.1016/0190-9622(90)70080-2
- [21] VIGNALI DA, CARSON RT, CHANG B, MITTLER RS, STROMINGER JL. The two membrane proximal domains of CD4 interact with the T cell receptor. *J Exp Med* 1996; 183: 2097–2107. doi:10.1084/jem.183.5.2097
- [22] MITTLER RS, GOLDMAN SJ, SPITALNY GL, BURAKOFF SJ. T-cell receptor-CD4 physical association in a murine T-cell hybridoma: induction by antigen receptor ligation. *Proc Natl Acad Sci USA* 1989; 86: 8531–8535. doi:10.1073/pnas.86.21.8531
- [23] EDELMAN J, MEYERSON HJ. Diminished CD3 expression is useful for detecting and enumerating Sezary cells. *Am J Clin Pathol* 2000; 114: 467–477.
- [24] ALAIBAC M, TONIN E, PESERICO A. Cutaneous lymphomas. *Acta Dermatovenerol* 2001; 10.
- [25] VONDERHEID EC. On the diagnosis of erythrodermic cutaneous T-cell lymphoma. *J Cutan Pathol* 2006; 33: 27–42. doi:10.1111/j.0303-6987.2006.00541.x
- [26] PREESMAN AH, TOONSTRA J, VAN DER PUTTE SCJ, VANVLOTEN WA, et al. Immunophenotyping on simultaneously occurring plaques and tumours in mycosis fungoides and Sézary syndrome. *Br J Dermatol* 1993; 129: 660–666. doi:10.1111/j.1365-2133.1993.tb03328.x
- [27] MICHIE SA, ABEL EA, HOPPE RT, WARNKE RA, WOOD GS. Discordant expression of antigens between intraepidermal and intradermal T cells in mycosis fungoides. *Am J Pathol* 1990; 137: 1447–1451.
- [28] HARMON CB, WITZIG TE, KATZMANN JA, PITTELKOF MR. Detection of circulating T cells with CD4+CD7- immunophenotype in patients with benign and malignant lymphoproliferative dermatoses. *J Am Acad Dermatol* 1996; 35: 404–410. doi:10.1016/S0190-9622(96)90605-2
- [29] QUERFELD C, ROSEN ST, GUITART J, KUZEL TM. The spectrum of cutaneous T-cell lymphomas: new insights into biology and therapy. *Curr Opin Hematol* 2005; 12: 273–278. doi:10.1097/01.moh.0000166498.64515.03
- [30] WANG JJ, HU C, LEE F, CHENG JT, WANG JJ. Internalization of CD4 molecules in human T-cells demonstrated by immuno-electron microscopy. *Histochemistry* 1992; 97: 51–59. doi:10.1007/BF00271281
- [31] DUVIC M, FOSS FM. Mycosis fungoides: pathophysiology and emerging therapies. *Semin Oncol* 2007; 34: S21–S28. doi:10.1053/j.seminoncol.2007.11.006
- [32] PELCHEN-MATTHEWS A, ARMES JE, GRIFFITHS G, MARSH M. Differential endocytosis of CD4 in lymphocytic and nonlymphocytic cells. *J Exp Med* 1991; 173: 575–587. doi:10.1084/jem.173.3.575