

## Overexpression of Wnt-2 in colorectal cancers

J. K. PARK<sup>1</sup>, J. H. SONG<sup>2</sup>, T. C. HE<sup>3</sup>, S. W. NAM<sup>2</sup>, J. Y. LEE<sup>2</sup>, W. S. PARK<sup>2\*</sup>

<sup>1</sup>Departments of Surgery and <sup>2</sup>Pathology, College of Medicine, The Catholic University of Korea, 505 Banpo-dong, Seocho-gu, Seoul 137-701, Korea, e-mail: wonsang@catholic.ac.kr, <sup>3</sup>The Molecular Oncology Laboratory, Department of Surgery, The University of Chicago Medical Center, Chicago, Illinois 60637, U.S.A.

Received July 7, 2008

The binding of the Wnt ligand to its receptor Frizzled, activates the Wnt canonical signaling pathway in carcinogenesis as well as many cellular processes, including cellular proliferation and differentiation. Wnt-2, one of 19 members of the *Wnt* gene family, is frequently overexpressed in malignant tissues. Here, in order to investigate the role of Wnt-2 in colorectal carcinogenesis, we examined the expression of the Wnt-2 protein in 120 colorectal cancers by immunohistochemistry. Wnt-2 protein was expressed in the cell membrane and cytoplasm and up-regulated in 74 (61.7%) of 120 colorectal cancers. Statistically, overexpression of Wnt-2 protein was not associated with the clinical and pathological parameters studied, including tumor location, tumor size, clinical stage, lymph node metastasis, and 5-year survival ( $P > 0.05$ ). These results indicate that up-regulation of the Wnt-2 protein might play a role in the development of colorectal cancers, as an early event of carcinogenesis.

*Key words: Wnt-2 protein, expression, immunohistochemistry, tissue microarray, colon cancer*

The Wnt ligand binds directly to the cystein-rich extracellular domain of Frizzled (Fz), activates disheveled and disassembles  $\beta$ -catenin, resulting in  $\beta$ -catenin stabilization and accumulation in the cytoplasm [1, 2]. In general, the level of  $\beta$ -catenin, in the cytoplasm, is kept low by interaction with a protein complex that consists of adenomatous polyposis coli (APC), Axin, protein phosphatase 2A, and glycogen synthase kinase 3 $\beta$  (GSK-3 $\beta$ ). It is believed that this complex phosphorylates the  $\beta$ -catenin, thereby inducing ubiquitination-dependent proteolysis of  $\beta$ -catenin. Therefore, alterations of these genes cause accumulation of  $\beta$ -catenin, in the cytoplasm as well as nuclear translocation of  $\beta$ -catenin. After its translocation into the nucleus, the stabilized  $\beta$ -catenin binds to members of the Tcf/Lef family thereby activating target genes, such as cyclin D1 and myc.

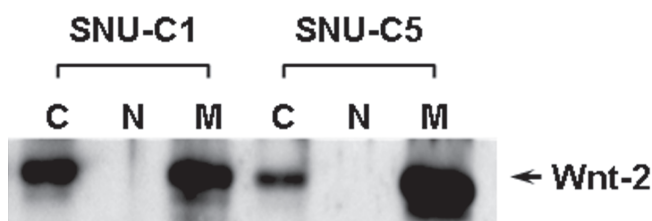
Several lines of evidence have shown that the Wnt signaling pathway related genes are involved in human cancer development and/or progression [2]. In cancer cells, one of these genes is mutated, in a given tumor sample, reflecting their role in a common pathway of carcinogenesis [3]. For example, colon tumors with mutations in the *APC* gene have a wild-type

$\beta$ -catenin and tumors with mutations in the  $\beta$ -catenin gene have a wild-type *APC*. In particular, most of the  $\beta$ -catenin mutations are activating mutations, mainly occurring at one of the four phosphorylation sites in exon 3 [2, 4]. In addition, aberrant overexpression in the cytoplasm or nuclear accumulation of  $\beta$ -catenin is frequently found in sporadic colorectal cancers. [5] Moreover, mutations in the *APC*,  $\beta$ -catenin and *Axin* genes are frequently found in Western reports on colon cancer. These findings suggest that constitutive activation of the Wnt canonical pathway contributes to human carcinogenesis [6]. However, somatic mutations in *APC* and  $\beta$ -catenin genes have been only rarely detected in Korean patients with colorectal cancer [7]. Thus, it is likely that there are other mechanisms responsible for activating the Wnt signaling pathway in the development of sporadic colorectal cancer in Korean patients.

The role of Wnt signaling in cancer was suggested by the discovery of Wnt-1 at an integration site of MMTV in mouse mammary carcinomas [8]. It has been shown that the overexpression of Wnt (Wnt-1 and Wnt-2), with signaling through  $\beta$ -catenin, promotes transformation of mammary epithelial cells in the mouse cell line C57MG [9–11]. In addition, Wnt signaling regulates expression of the receptor tyrosine kinase Met, a receptor for epithelial growth, in

\* Corresponding author

Park JK and Song JH contribute equally to this work.



**Figure 1.** Wnt-2 expression in 2 colon cancer cell lines by Western blot. Wnt-2 protein was expressed mainly in cell membrane and cytoplasm in two colorectal cancer cell lines. C, cytosol fraction; N, nuclear fraction; M, membrane fraction.

colorectal cancer [12]. The *Wnt-2* gene, located on chromosome 7q31.3, is highly expressed in fetal lungs and weakly expressed in the placenta [13]. Blasband *et al.* has reported that up-regulation of Wnt-2 promotes transformation of mammary epithelial cells in the mouse cell line C57MG; demonstrating the oncogenic activity of Wnt-2 [9]. In addition, frequent up-regulation of Wnt-2 has been reported in colorectal cancer, gastric cancer and malignant pleural mesothelioma [13–15]. Furthermore, it has also been reported that blocking of Wnt-2 signaling, by anti-Wnt-2 antibody, induces downregulation of cytosolic  $\beta$ -catenin as well as apoptosis and suppression of tumor growth in a xenograft model [16]. All of these findings suggest that activation of the Wnt pathway, by upregulation of Wnt-2, may play an important role in the development of colorectal cancers.

Here, in order to investigate whether altered expression of Wnt-2 is associated with the development or progression of colorectal cancer, we evaluated the expression of Wnt-2 in a series of 120 colorectal cancers using immunohistochemistry.

## Materials and methods

**Tissue samples.** One hundred and twenty sporadic colorectal cancers were obtained from the College of Medicine, The Catholic University of Korea. The tumors were staged according to Dukes' criteria [17]. There were 12, 45, 55, and 8 cases with stage A, B, C, and D, disease respectively. Two pathologists screened the histological sections and selected areas representative in the density of tumor cells. Tissue cores from each cancer sample (0.6 mm in diameter) were taken and placed in a new recipient paraffin block using a commercially available microarray instrument (Beecher Instruments, Micro-Array Technologies, Silver Spring, MD, USA), according to established methods [18]. One cylinder of normal colon mucosa, adjacent to each tumor, was also transferred to the recipient block.

**Immunohistochemistry for Wnt-2.** To detect the subcellular location of Wnt-2, proteins from two colon cancer cell lines were extracted using the nuclear and cytoplasmic extraction reagents (NE-PER; Pierce, Rockford, IL, USA) or

membrane protein extraction kit (Mem-PER; Pierce) according to manufacturer's instruction, and 20  $\mu$ g of each lysate was separated by SDS-PAGE and transferred to nitrocellulose membranes. The proteins were detected with anti-Wnt-2 monoclonal antibodies (R&D Systems, Minneapolis, MN, USA).

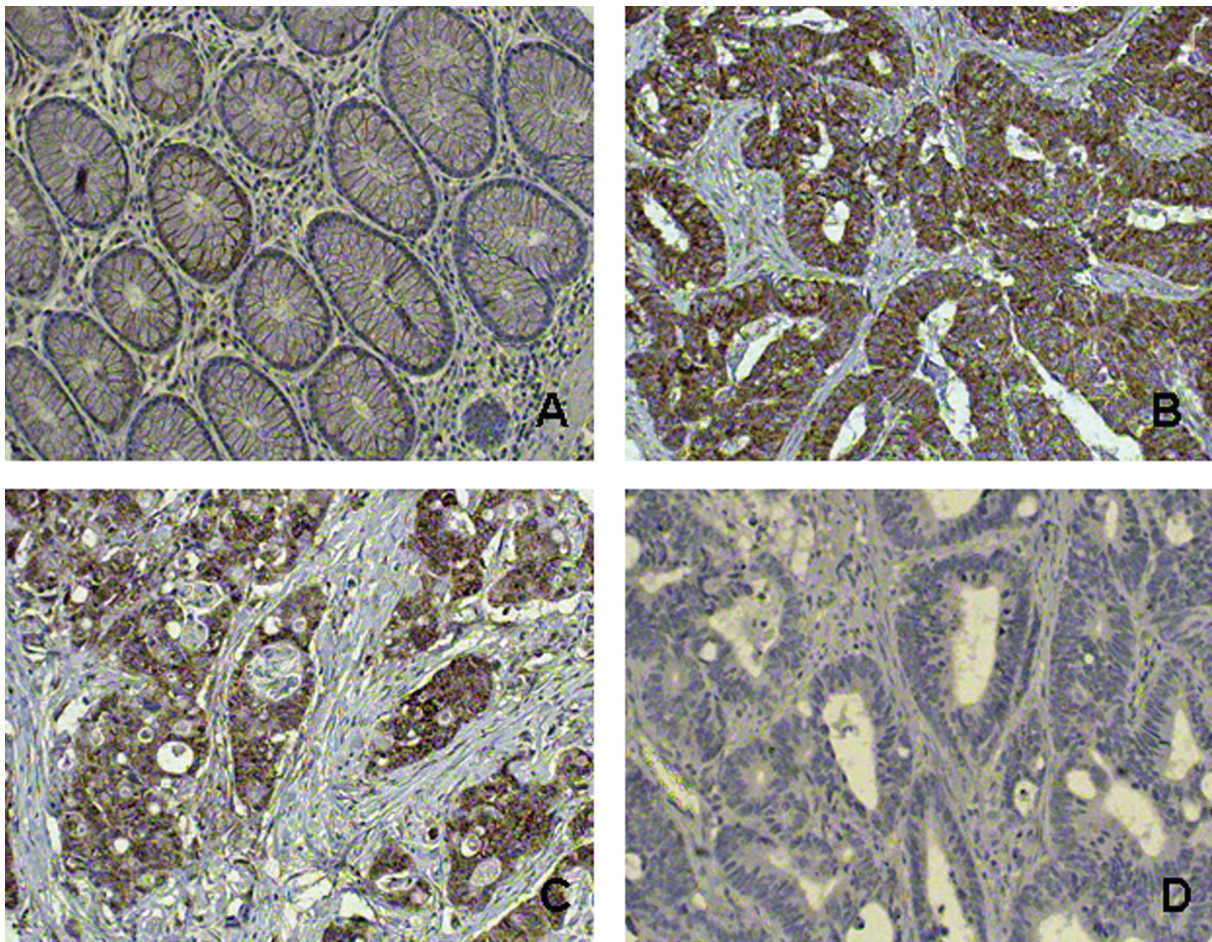
For the immunohistochemical analysis, 4  $\mu$ m sections were cut the day before use and stained according to standard protocols. To maximize the signal on immunohistochemistry, two strategies were used in the present study, i.e. antigen retrieval in citrate buffer and signal amplification with biotinylated tyramide. For the former, heat-induced epitope retrieval was conducted by immersing the slides in Coplin jars filled with 10 mmol/L citrate buffer (pH 6.0) and boiling the buffer for 30 min in a pressure cooker (Nordic Ware, Minneapolis, MN, USA) inside of a microwave oven at 700 W; the jars were then cooled for 20 min. For the latter, the Renaissance TSA indirect kit (NEN Life Science, Boston, MA, USA), which included streptavidin-peroxidase and biotinylated tyramide, was used. After rinsing with PBS, the slides were treated with 1%  $H_2O_2$  in PBS for 15 min at room temperature to remove endogenous peroxidase activity. After washing with TNT buffer (0.1 mol/L Tris-HCl, pH 7.4, 0.15 mol/L NaCl and 0.05% Tween 20) for 20 min, the slides were treated with TNB buffer (0.1 mol/L Tris-HCl, pH 7.4, 0.15 mol/L NaCl and 0.5% blocking reagent). The sections were incubated overnight at 4°C with the antibody (1/100 dilution) for Wnt-2 protein (R&D Systems, Minneapolis, MN, USA). Detection was carried out using biotinylated goat anti-mouse antibodies (Sigma, St. Louis, MO, USA), followed by incubation with peroxidase-linked avidin-biotin complex. Diaminobenzidine was used as a chromogen and the slides were counterstained with Mayer's hematoxylin. For the Wnt-2 protein, the tumors were interpreted as negative when the immunostaining was weak, as with the corresponding normal colon mucosa, or when immunopositive cells were less than 30% of the cancer cells. The results were reviewed independently by two pathologists. As negative controls, the slides were treated by replacing the primary antibodies with non-immune serum.

**Statistical analysis.** The correlation between Wnt-2 expression and various clinical and pathological parameters was assessed using the Chi-square and Bartholomew tests. Survival curves were constructed using the Kaplan–Meier method and compared using the log rank test. A *P* value less than 0.05 was considered statistically significant.

## Results

**Immunohistochemistry for the Wnt-2 Protein.** The subcellular localization of Wnt-2 was confirmed in 2 colon cancer cell lines by Western blot analysis using a monoclonal anti-Wnt-2 antibody. The Wnt-2 protein was expressed mainly in the cell membrane and cytoplasm of the cancer cells (Fig. 1).

The immunohistochemistry findings from the membrane of the glandular epithelial cells of the corresponding normal



**Figure 2.** Expression of Wnt-2 in colonic mucosa and cancer by immunohistochemistry. A, colonic mucosa, the positive reaction was weakly seen in lymphocytes of lamina propria and glandular epithelial cells. B & C, Tubular adenocarcinoma showed moderate to strong immunopositivity predominantly in the cytoplasm of tumor cells. D, Negative staining of Wnt-2 in cancer cells. (Original magnifications: A, B, C and D, X 200).

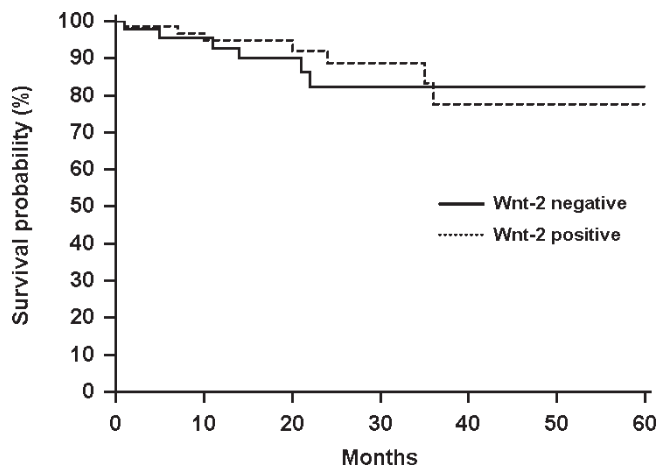
colon mucosa demonstrated negative or very weak positive staining. The expression of Wnt-2 in cancer cells, compared to the corresponding normal colon mucosa, showed moderate to strong immunopositive staining for the Wnt-2 protein in the cell membrane and cytoplasm of colorectal cancer cells (Fig. 2). The tumor tissues even from different portions of the same tumor showed similar expression levels, indicating no evidence of intra-tumor heterogeneity. However, the surrounding stromal cells, including fibroblasts, were negative for Wnt-2.

The overexpression of the Wnt-2 protein was detected in 74 (61.7%) of 120 cancers. Based on the differentiation grade of the cancer cells, Wnt-2 overexpression was detected in 66.7% (4/6), 62.4% (68/109) and 40% (2/5) of well, moderately and poorly differentiated colorectal cancers. This classification showed no association between the expression of the Wnt-2 protein and the differentiation of the tumor cells (Chi-Square test,  $P > 0.05$ ). In addition, Wnt-2 overexpression was noted in 7 (58.3%) of 12 cases corresponding to stage A,

29 (64.4%) of 45 to stage B, 32 (58.2%) of 55 to stage C, and 6 (75.0%) of eight corresponding to stage D, respectively. Furthermore, Wnt-2 was overexpressed in 34 (58.6%) of 58 cases with lymph node metastases. Statistically, there was no significant relationship between the Wnt-2 protein expression and the clinical and pathological parameters studied, including clinical stage (Bartholomew test,  $P > 0.05$ ), tumor location, tumor size, and lymph node metastases (Chi-Square test,  $P > 0.05$ ) (Table 1). The 5-years survival rate of patients with Wnt-2 positive tumors was 77.6%, while that of patients with Wnt-2 negative tumors was 82.3% (Fig. 3). Statistically, there was no significant association between the Wnt-2 overexpression and the 5-year survival ( $P = 0.6377$ ).

## Discussion

Wnt signaling is involved in various cellular processes, including embryonic development and homeostatic self-re-



**Figure 3.** Kaplan-Meier analysis of survival of colorectal cancer patients. Comparative survival analysis of immunohistochemically classified tumors demonstrating (-) negative and (...) positive staining for Wnt-2 protein showed no significant correlation between Wnt-2 overexpression and 5 year survival ( $P = 0.6377$ ).

newal. Altered expression or mutational activation of the Wnt signaling pathway related genes has been linked to various human cancers, such as gastric, lung and colorectal cancers [11, 14, 19]. Despite the widespread activation of the Wnt

pathway in colon cancer, only a small fraction (<5%) of sporadic cancers exhibit activating mutations of the *APC* or  *$\beta$ -catenin* genes during tumorigenesis. This suggests that other molecular mechanisms play a role in the activation of this pathway [20]. Epigenetic changes in Wnt pathway components, including *APC*, *DICKKOPF-1 (DKK-1)* and *secreted frizzled-related proteins (SFRPs)*, have also been found [21–23]. Recently, it has been reported that K-ras mutations can induce activation of Wnt signaling *in vitro* by increasing  $\beta$ -catenin stability, perhaps through inhibition of the kinase activity of GSK-3 $\beta$  [24].

Recently, aberrant expression of upstream components of the Wnt signaling pathway has also been found in colorectal cancers [11, 13]. Inhibition of Wnt-2 in colorectal cancer cell lines has been shown to destabilize  $\beta$ -catenin and induce apoptosis, suggesting that an upstream Wnt signal, at the ligand level, may regulate Wnt signaling even in the presence of downstream mutations [25]. In addition, stable overexpression of Wnt-2 has been associated with an invasive phenotype, through a noncanonical Wnt pathway coupled to GSK-3 $\beta$  and c-Jun/AP-1 signaling [26]. All of these findings suggest that up-regulation of Wnt-2, in colorectal cancer, may induce cell proliferation and that *Wnt-2* may be a candidate oncogene.

To investigate the relationship between Wnt-2 expression and the clinical and pathological parameters of colorectal cancers, we examined the Wnt-2 expression in 120 colorectal cancer tissues. First of all, we analyzed the subcellular localization of Wnt-2 in 2 colon cancer cell lines by Western blot analysis and found that the Wnt-2 protein was expressed mainly in the cell membrane and cytoplasm of the cancer cells (Fig. 1). For colorectal cancer, overexpression of the Wnt-2 protein was detected in 74 (61.7%) of 120 colorectal cancers. Statistically, the Wnt-2 expression in the colorectal cancers was not associated with the clinical and pathological parameters studied, including lymph node metastases and clinical stage (Table 1). In addition, there was no significant correlation between the Wnt-2 overexpression and the 5-year survival (Fig. 3). According to a report by Cheng *et al* [19], Wnt-2 expression was correlated with  $\beta$ -catenin nuclear translocation and tumor dissemination. However, it has been reported that constitutive activation of the Wnt signaling pathway is an early event in the progression of tumorigenesis in more than 90% of colorectal cancers [27]. Furthermore, Wnt-2 upregulation in the transition from normal to malignant mucosa, in colon cancer, indicates that Wnt-2 is important in the progression from normal colon mucosa into the malignant phenotype [14]. Therefore, our findings strongly suggest that overexpression of Wnt-2 might play a role in the development of colorectal cancers, as an early event.

The authors wish to acknowledge the financial support of the Catholic Medical Center Research Foundation made in the program year of 2007.

**Table 1.** Wnt-2 immunoreactivity in the colorectal cancers

Parameters	Wnt-2 expression	
	+	-
Differentiation <sup>†</sup>		
Well	4	2
Moderately	68	41
Poorly	2	3
L/N metastasis <sup>‡</sup>		
+	34	24
-	40	22
Stage <sup>#</sup>		
A	7	5
B	29	16
C	32	23
D	6	2
Side <sup>†</sup>		
Right	13	10
Left	61	36
Size <sup>†</sup>		
< 5 cm	37	20
> 5 cm	37	26
Total	74	46

<sup>†</sup>, Chi-Square test,  $P > 0.05$

<sup>#</sup>, Bartholomew test,  $P > 0.05$

## References

- [1] DANN CE, HSIEH JC, RATTNER A, et al. Insights into Wnt binding and signaling from the structures of two Frizzled cysteine-rich domains. *Nature* 2001; 412: 86–90. doi:10.1038/35083601 PMID:11452312
- [2] Polakis P. The many ways of Wnt in cancer. *Curr Opin Genet Dev* 2007; 17: 45–51. doi:10.1016/j.gde.2006.12.007
- [3] Lustig B, Behrens J. The Wnt signaling pathway and its role in tumor development. *J Cancer Res Clin Oncol* 2003; 129: 199–221.
- [4] PARK WS, OH RR, PARK JY, et al. Frequent somatic mutations of the  $\beta$ -catenin gene in intestinal-type gastric cancer. *Cancer Res* 1999; 59: 4257–4260.
- [5] RESNICK MB, ROUTHIER J, KONKIN T, et al. Epidermal growth factor receptor, c-MET, beta-catenin, and p53 expression as prognostic indicators in stage II colon cancer: a tissue microarray study. *Clin Cancer Res* 2004; 10: 3069–3075. doi:10.1158/1078-0432.CCR-03-0462 PMID:15131045
- [6] UTHOFF SM, EICHENBERGER MR, MCAULIFFE TL, et al. Wingless-type frizzled protein receptor signaling and its putative role in human colon cancer. *Mol Carcinog* 2001; 31: 56–62. doi:10.1002/mc.1039 PMID:11398198
- [7] KIM IJ, KU JL, KANG HC, PARK JH, et al. Mutational analysis of OGG1, MYH, MTH1 in FAP, HNPCC and sporadic colorectal cancer patients: R154H OGG1 polymorphism is associated with sporadic colorectal cancer patients. *Hum Genet* 2004; 115: 498–503. doi:10.1007/s00439-004-1186-7 PMID:15449173
- [8] Nusse R, VARMUS HE. Many tumors induced by the mouse mammary tumor virus contain a provirus integrated in the same region of the host genome. *Cell* 1982; 31: 99–109. doi:10.1016/0092-8674(82)90409-3 PMID:6297757
- [9] Blasband A, Schryver B, Papkoff J. The biochemical properties and transforming potential of human Wnt-2 are similar to Wnt-1. *Oncogene* 1992; 7: 153–161.
- [10] Peifer M, Polakis P. Wnt signaling in oncogenesis and embryogenesis—a look outside the nucleus. *Science* 2000; 287: 1606–1609. doi:10.1126/science.287.5458.1606 PMID:10733430
- [11] You L, He B, Xu Z, et al. Inhibition of Wnt2-mediated signaling induces programmed cell death in non-small-cell lung cancer cells. *Oncogene* 2004; 23: 6170–6174. doi:10.1038/sj.onc.1207844 PMID:15208662
- [12] BOON EM, VAN DER NEUT R, VAN DE WETERING M, et al. Wnt signaling regulates expression of the receptor tyrosine kinase met in colorectal cancer. *Cancer Res* 2002; 62: 5126–5128.
- [13] Katoh M. Frequent up-regulation of WNT2 in primary gastric cancer and colorectal cancer. *Int J Oncol* 2001; 19: 1003–1007.
- [14] HOLCOMBE RF, MARSH JL, WATERMAN ML, et al. Expression of Wnt ligands and Frizzled receptors in colonic mucosa and in colon carcinoma. *Mod Pathol* 2002; 55: 220–226. doi:10.1136/mp.55.4.220 PMID:12147710 PMID:1187182
- [15] Mazieres J, You L, He B, Xu Z, et al. Wnt2 as a new therapeutic target in malignant pleural mesothelioma. *Int J Cancer* 2005; 117: 326–332. doi:10.1002/ijc.21160
- [16] You L, He B, Xu Z, et al. An anti-Wnt-2 monoclonal antibody induces apoptosis in malignant melanoma cells and inhibits tumor growth. *Cancer Res* 2004; 64: 5385–5389. doi:10.1158/0008-5472.CAN-04-1227 PMID:15289346
- [17] ASTLER VB, COLLIER FA. The prognostic significance of direct extension of carcinoma of the colon and rectum. *Ann Surg* 1954; 139: 846–851.
- [18] Kononen J, Bubendorf L, Kallioniemi A, et al. Tissue microarrays for high-throughput molecular profiling of tumor specimens. *Nat Med* 1998; 4: 844–847. doi:10.1038/nm0798-844 PMID:9662379
- [19] CHENG XX, WANG ZC, CHEN XY, et al. Correlation of Wnt-2 expression and  $\beta$ -catenin intracellular accumulation in Chinese gastric cancers: relevance with tumour dissemination. *Cancer Letters* 2005; 223: 339–347. doi:10.1016/j.canlet.2004.11.013 PMID:15896469
- [20] Segditsas S, Tomlinson I. Colorectal cancer and genetic alterations in the Wnt pathway. *Oncogene* 2006; 25: 7531–7537. doi:10.1038/sj.onc.1210059 PMID:17143297
- [21] Aguilera O, Peña C, GARCÍA JM, et al. The Wnt antagonist DICKKOPF-1 gene is induced by 1 $\alpha$ , 25-dihydroxyvitamin D3 associated to the differentiation of human colon cancer cells. *Carcinogenesis* 2007; 28: 1877–1884. doi:10.1093/carcin/bgm094 PMID:17449905
- [22] Esteller M, Sparks A, Toyota M, et al. Analysis of adenomatous polyposis coli promoter hypermethylation in human cancer. *Cancer Res* 2000; 60: 4366–4371.
- [23] Suzuki H, WATKINS DN, JAIR KW, et al. Epigenetic inactivation of SFRP genes allows constitutive WNT signaling in colorectal cancer. *Nat Genet* 2004; 36: 417–422. doi:10.1038/ng1330 PMID:15034581
- [24] Li J, Mizukami Y, Zhang X, et al. Oncogenic K-ras stimulates Wnt signaling in colon cancer through inhibition of GSK-3 $\beta$ . *Gastroenterology* 2005; 128: 1907–1918. doi:10.1053/j.gastro.2005.02.067 PMID:15940626
- [25] Shi Y, He B, KUCHENBECKER KM, et al. Inhibition of Wnt-2 and galectin-3 synergistically destabilizes beta-catenin and induces apoptosis in human colorectal cancer cells. *Int J Cancer* 2007; 121: 1175–1181. doi:10.1002/ijc.22848
- [26] Le Floch N, Rivat C, De Wever O, et al. The proinvasive activity of Wnt-2 is mediated through a noncanonical Wnt pathway coupled to GSK-3 $\beta$  and c-Jun/AP-1 signaling. *FASEB J* 2005; 10: 144–146.
- [27] Fodde R, Smits R, Clevers H. APC, signal transduction and genetic instability in colorectal cancer. *Nat Rev Cancer* 2001; 1: 55–67. doi:10.1038/35094067 PMID:11900252